

CASE REPORT

A rare case of paediatric trichotillomania complicating into Rapunzel syndrome: a case report

Preethi Swaroop Bollapalli, ¹, MBBS DPM, Janardhan Bommakanti, ², MBBS MD, Sravan Reddy Vangala, ³, MBBS MD, Sunil Pawar, ⁴, MBBS DCH DNB, Madhumohan Reddy, ⁵, MBBS Mch

^{1,3} Consultant Psychiatrist, Maithri psychiatry centre; ² Consultant Dermatologist, ⁴ Consultant Paediatrician, ⁵ Consultant Paediatric surgeon Krishna children's Hospital, Hyderabad, India

ABSTRACT

Background: Trichotillomania is a psychological condition that involves strong urge to pull one's hair. Trichophagia is disorder of eating of hair. Bezoar is collection of undigested material such as hair, drugs and plastic or combinations. Rapunzel syndrome is a rare type of trichobezoar, which has mass of hair lodged in stomach extending up to ileum. In majority, diagnosis is made very late, at a stage where surgery is the only option.

Case description: A 9 year old girl was brought with complaints of loss of hair on scalp since 8 months, decreased appetite, and constipation, weight loss since 5 months and vomiting since 2 weeks. Patient had paediatric consultations without much benefit; patient was referred to dermatologist and paediatric surgeon. Ultrasound showed mass in abdomen. Patient was operated to find a mass extending from stomach to terminal ileum. Patient was referred to a Psychiatrist and diagnosis of Trichotillomania was made.

Discussion: Trichobezoar is common in young females, often with an underlying psychiatric disorder, they present late due to the low index of suspicion. As this condition is a rarity in paediatric age group and very little progress to Rapunzel syndrome, this paper discusses about the systemic team management of the above individual.

Conclusion: High index of suspicion is needed to diagnose this condition in paediatric age group.

Key words: Trichotillomania; trichobezoar; rapunzel syndrome

Date of first submission: 5/11/14 **Date of initial decision:** 24/11/14 **Date of acceptance:** 29/12/14

INTRODUCTION

The American Psychiatric Association's *Diagnostic and Statistical Manual of Mental Disorders, Fourth Edition, Text Revision (DSM-IV-TR)* ^[1] includes trichotillomania (TTM) in the category of a diverse group of impulse-control disorders. The essential features of this disorder include recurrent pulling out of one's hair resulting in noticeable hair loss, increasing sense of tension immediately preceding or when resisting hair pulling, and pleasure or relief when pulling out the hair. It also cause clinically significant distress or impaired social or occupational functioning. The site from which hair is most frequently pulled is the scalp, but hair may be pulled from eyelashes, eyebrows, the pubic region, or other parts of the body.

Many patients meet all the criteria for TTM except tension before or relief after pulling out hair. The patient described here did not meet *DSM-IV-TR* criteria ^[1] for TTM, even though she had a long history of both disfiguring hair pulling and trichophagia (ingesting the pulled out hair). In one study of adults with TTM, 17% did not describe tension before or relief after pulling out their hair and therefore did not meet *DSM-IV-TR* ^[1] criteria for the diagnosis. Thus, the current

diagnostic criteria may exclude patients with clinically significant symptoms of TTM. ^[2]

Bezoar is a tightly packed collection of undigested material that is unable to exit the stomach. In very rare case, the Rapunzel Syndrome the condition in which hair extends through the pylorus into the small bowel causing symptom and sign of partial or complete gastric outlet obstruction. ^[2]

CASE HISTORY

A 9 year old girl was brought by her parents with complaints of 1).loss of hair on scalp area since 8 months 2).loss of appetite, constipation, weight loss since 5 months, and 3) vomiting since 2 weeks.

The patient was asymptomatic 8 months back, mother initially noticed small patchy loss of hair in scalp area in parietal region on both sides more so on right side. After 2-3 months she observed reduction in quantity of hair more on parietal and temporal region of the scalp on both sides. On detailed history taking, mother revealed an interesting observation that her child pulls the hair with her fingers whenever she is alone. But, denied habit of eating the pulled hair. She had loss of appetite, constipation and weight loss since 5 months; vomiting 1-2 episodes in day since 2 weeks, mucoid in appearance with few food particles. The patient regularly visited paediatrician for above problem including hair problem, she was prescribed medicines symptomatically, multivitamins with deworming on 3 visits. When the patient had not much benefit, paediatrician referred the child to dermatologist for hair problem and paediatric surgeon for abdominal symptoms.

Address for correspondence: Dr Preethi Swaroop Bollapalli
Address: 137/B, MIGH, S.R. Nagar, Hyderabad 500038,
Telangana, India.
Phone number: +919885259740
Email: drpreethiswaroop@yahoo.co.in.

How to cite this article: Bollapalli PS, Bommakanti J, Vangala SR, Pawar S, Reddy M. A rare case of paediatric trichotillomania complicating into Rapunzel syndrome: a case report. AP J Psychol Med 2014; 15(2):258-60.

On examination the child was dull looking. Diffuse loss of hair on the scalp mainly in parietal and temporal region. Small intact hair follicles are visible in same area. Child is pale. No scaling or scarring present in affected area. All investigations were done along with ultrasound abdomen scan. Patient was anaemic. Ultrasound abdomen showed mass in gastrointestinal tract. Though CT/MRI scanning of abdomen was advised, family members refused because they could not afford.

She was referred to paediatric surgeon, evaluated, her basic investigations were done; haemogram was significant for anaemia. Patient was planned for surgery with the impression of intestinal obstruction secondary to intestinal bands or meckel's diverticulitis which is more common in children, surgeon approached from the small intestine on exploration found collection of mass of tuft hair which was traced from the ileum till the stomach (Figures 1, 2, 3).

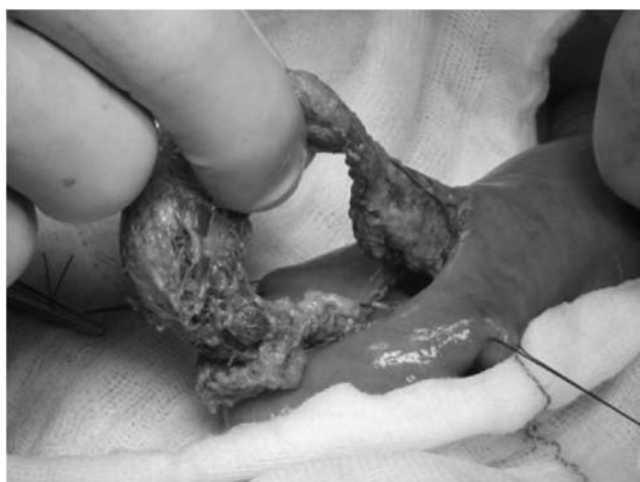

Figure 1 Bezoar in stomach coated with food particles during surgery

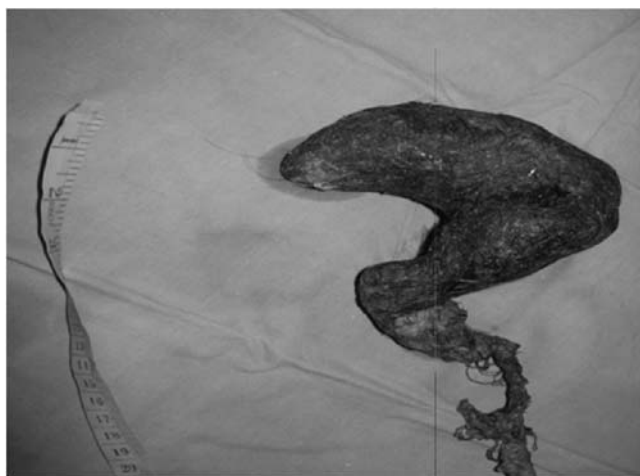

Figure 2 Bezoar extending beyond stomach




Figure 3 Bezoar extending from stomach to terminal ileum

The patient was 4th in birth order belonging to a poor socio economic family and illiterate background, patient had thumb sucking, teeth grinding and temper tantrums, patient's family reported patient plucking her hair but denied any ingestion of it, she was regularly beaten for pulling her hair, patient reported a sense of tension building up during plucking of hair and an ease afterwards. Patient appeared anxious and impulsive, patient had average intelligence. She was referred to the psychiatrist and a diagnosis of trichotillomania was made according to *DSM-IV-TR*.^[1] Diagnostic psychometry was not significant.

Details of psychiatric treatment:

The patient did not tolerate the SSRI, fluoxetine 20 mg/day as she developed repeated vomiting with this drug. Hence, she was started on oral clomipramine 25mg once daily for 1 week, increased to 50 mg divided into 2 doses every day along with oral divalproex sodium 250 mg twice daily.

The patient was simultaneously taught habit reversal techniques. Behaviour modification with wearing of woollen gloves and monkey cap. Parental counselling was given, regular monitoring was advised and if economically possible patient should be kept busy with crochet making and woollen knitting by hands.

The patient was followed up for 3 months. She did not show any signs of plucking of hair and her scalp condition was healthy.

DISCUSSION

Trichotillomania is a psychiatric disorder that involves strong urges to pull own hair.^[1] 30% will engage in trichophagia, and of these, only 1% will go on to eat their hair to the extent requiring surgical removal.^[3] Less than half of the patients give a history of trichophagia. No clear evidence-based practice guidelines for the treatment of patients with TTM are available, and more research is needed. Behavioural techniques and selective serotonin reuptake inhibitors (SSRIs) are the most commonly used treatment modalities,

having the most evidence for efficacy. In habit-reversal therapy, patients learn to be aware of the times, cues, and situations in which they pull their hair. They practice movements such as those in knitting, crochet, and needlepoint that redirect their urges to pull their hair. Behaviour modifications using monkey cap, woollen gloves which prevent gripping and plucking. Thus they learn to “substitute a different and more adaptive behaviour and receive social approval for efforts to interrupt the hair pulling.”^[4]

The SSRIs are the pharmacologic agents used most frequently in the treatment of patients with TTM. Other psychotropic agents that have been used for treating patients with TTM include the tricyclic antidepressants, the antipsychotic medications, and mood-stabilizing (anticonvulsant) medications. Clomipramine hydrochloride and fluoxetine hydrochloride have been used successfully.

In addition to cognitive-behavioural therapy, the patient received SSRI therapy because of her long history of hair pulling with its serious consequences and recurrent hair-pulling impulses after surgical removal of a trichobezoar. This combination treatment was effective initially.

Trichobezoar is common in young females, often with an underlying psychiatric disorder. In our case the presentation is a young age with hair extending from stomach to terminal ileum, causing symptoms, which could mimic vague to gastrointestinal symptoms. Rapunzel Syndrome is a rare form of trichobezoar, named after a tale written in 1812 by the Brothers Grimm about a young maiden, Rapunzel, with long hair who lowered her hair to the ground from a castle, which was a prison tower to permit her young prince to climb up to her window and rescue her. This syndrome was originally described by Vaughan et al. in 1968. The commonly accepted definition is that of a gastric trichobezoar with a tail extending to the jejunum, ileum or the ileocecal junction.^[5]

Majority of cases of trichobezoar present late, due to the low index of suspicion. The complications of Rapunzel syndrome ranges from attacks of incomplete pyloric obstruction to complete obstruction of the bowel to perforation to peritonitis and mortality.^[3, 6-8]

Ultrasound has not much to offer as a diagnostic tool. Endoscopy is diagnostic, in almost all cases. CT scan with contrast will delineate the extension of trichobezoar. Other methods including the use of laser ignited mini-explosive technique were used successfully. Laparoscopy has been also used with limited success.

This disorder is included in impulse control disorder in DSM IV TR,^[1] and included in obsessive compulsive and related disorders in DSM V.^[9] The increase sense of tension and gratification or relief after pulling of hair in DSM IV TR,^[1] has been replaced in DSM V,^[9] and attempts to decrease hair pulling has been added. Obsessive compulsive disorder was classified under anxiety disorders in DSM IV TR,^[1]

whereas it exists as independent entity as obsessive compulsive and related disorders in DSM V.^[9]

CONCLUSION

This case presented with common gastrointestinal symptoms seen in children except for loss of hair from the scalp, family members denied any ingestion of hair giving any hint towards this diagnosis, occurrence in this age group was pointing away from this diagnosis, intervention by dermatologist and paediatric surgeon and finding a mass per abdomen in USG only to be surprised to find bezoar extending from stomach all the way to terminal ileum. This case is being reported because of its rarity. It stresses the need for multidisciplinary approach that is mandatory for better treatment outcome. This case is rare because of its presentation as Rapunzel syndrome rather isolated TTM.

Acknowledgements: Nil

References

1. American Psychiatric Association. (2000). Diagnostic and statistical manual of mental disorders (4th ed., text rev.). Washington, DC: Author.
2. Al-Wadan AH, Al-Absi M, Al-Saadi AS, Abdoulgafour M. Rapunzel syndrome. Saudi Medical Journal 2006; 1912-4.
3. Scorpio R, Sharma D. Terminal ileal trichophytobezoar with perforation: A rare presentation with review. J Indian Assoc Pediatr Surg 2008;13(1):38-40.
4. Sadock BJ, Sadock VA, Ruiz P. Kaplan and Sadock Textbook of Psychiatry. 9th Edition. USA: Lippincott Williams & Wilkins; c2009. Chapter 21, Impulse control disorders - not elsewhere classified; p. 2178-87.
5. Al Wadan AH, Al Kaff H, Al Senabani J, Al Saadi AS. Rapunzel syndrome trichobezoar in a 7-year-old girl: a case report. Cases J 2008;1(1):205.
6. Mohite PN, Gohil AB, Wala HB, Vaza MA. Rapunzel syndrome complicated with gastric perforation diagnosed on operation table. J Gastrointest Surg 2008;12(12):2240-2.
7. Pérez E, Santana JR, García G, Mesa J, Hernández JR, Betancort N, et al. [Gastric perforation due to trichobezoar in an adult (Rapunzel syndrome)]. Cirugía española 2005;78(4):268-70.
8. Soufi M, Benamr S, Belhassan M, Massrouri R, Ouazzani H, Chad B. Giant trichobezoar of duodenojejunal flexure: a rare entity. Saudi J Gastroenterol 2010;16(3):215-7.
9. American Psychiatric Association. (2013). Diagnostic and Statistical Manual of Mental Disorders (5th ed.). Arlington, VA: American Psychiatric Publishing.

Conflict of interest: None declared

Source(s) of support: Nil