

## A sphenoid sinus mucocoele simulating as retro bulbar optic neuritis

Anoop Kishore Gupta, Vimla Menon, Pradeep Sharma, Rohit Saxena, Senthil Kumaran<sup>1</sup>

A 25-year-old male presented with complaints of sudden diminution of vision with pain on eye movement in the left eye which was diagnosed clinically as retro bulbar optic neuritis. However, magnetic resonance imaging (MRI) showed lesion consistent with sphenoid sinus mucocoele. Early surgical removal of mucocoele led to complete recovery of vision, contrast and visual field. A high index of suspicion is necessary for intracranial lesions in all cases of retro bulbar neuritis, especially those with atypical symptoms.

**Key words:** Magnetic resonance imaging, optic neuritis, sphenoid sinus mucocoele, visual evoked response

**Cite this article as:** Gupta AK, Menon V, Sharma P, Saxena R, Kumaran S. A sphenoid sinus mucocoele simulating as retro bulbar optic neuritis. Indian J Ophthalmol 2012;60:216-8.

### Access this article online

#### Quick Response Code:



#### Website:

[www.ijo.in](http://www.ijo.in)

#### DOI:

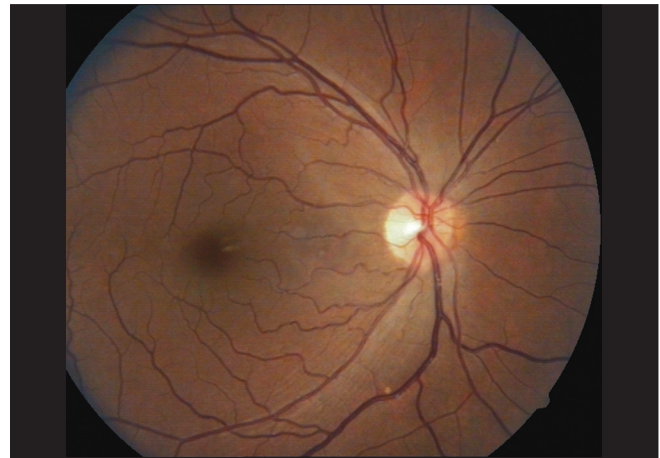
10.4103/0301-4738.95876

Optic neuritis (ON), an acute inflammatory disorder of the optic nerve, typically presents with sudden monocular loss of vision and eye pain in young adults. There are various causes which can lead to ON. The cause of ON in mucosal diseases is due to the course of the optic canal through it. It leads to slowly progressive painless loss of vision, which may terminate in optic atrophy.

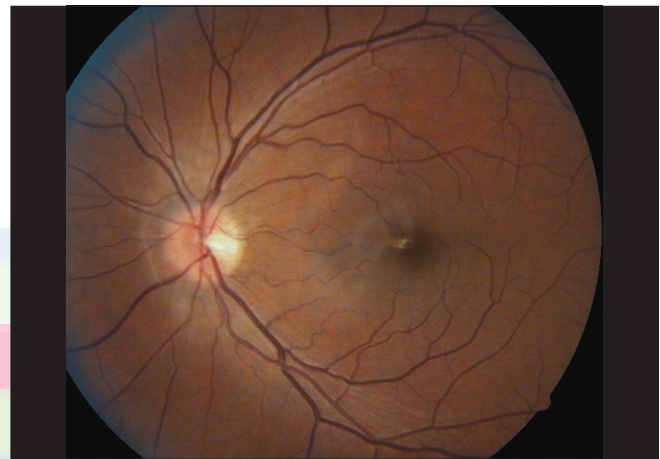
### Case Report

A 25-year-old man presented to us with complains of sudden diminution of vision in the left eye for four days associated with frontal headache and pain on eye movement with no signs of upper respiratory infection or sinusitis.

On examination he had a visual acuity of 20/60 in the left eye and 20/20 in right eye with a left relative afferent pupillary defect (RAPD) of 0.9 log unit. Eye movements were full in both the eyes. Fundus examination revealed normal disc in either eye [Fig. 1a and b]. Contrast sensitivity by Pelli Robson was 1.65 in the right eye and 0.90 in the left eye. Color vision was



**Figure 1a:** Fundus photo of right eye showing normal optic disc



**Figure 1b:** Fundus photo of left eye showing normal optic disc and macula

normal in both the eyes (Pseudo-isochromatic Ishihara plate). Visual evoked response (VER) showed amplitude of 10 micro volts and latency of 103 milliseconds in the right eye and 4 micro volts and 130 milliseconds in the left eye. Goldmann visual field charting was normal in the right eye with baring of blind spot in the left eye [Fig. 2a and b]. No other systemic or neurological deficit was present.

A clinical diagnosis of retro bulbar optic neuritis was made on the basis of acute vision loss, pain on eye movement, affected contrast sensitivity and increased latency on VER.

The patient was asked to follow up after one week, at that time he complained of increase in ocular pain even at rest and his vision had dropped to 20/200. So to exclude any demyelinating disease magnetic resonance imaging (MRI) of the brain was advised. The MRI showed a large lobulated lesion, 41 × 66 × 64 mm along the floor of the sella displacing the pituitary superiorly with a suprasellar extension (no post-contrast enhancement). A diagnosis of sphenoid sinus mucocoele was made [Fig. 3a and b]. The mass was large enough to be causing indentation of the cavernous sinus. The entire hormonal profile was done and all hormone levels in the blood were normal, including the serum prolactin level.

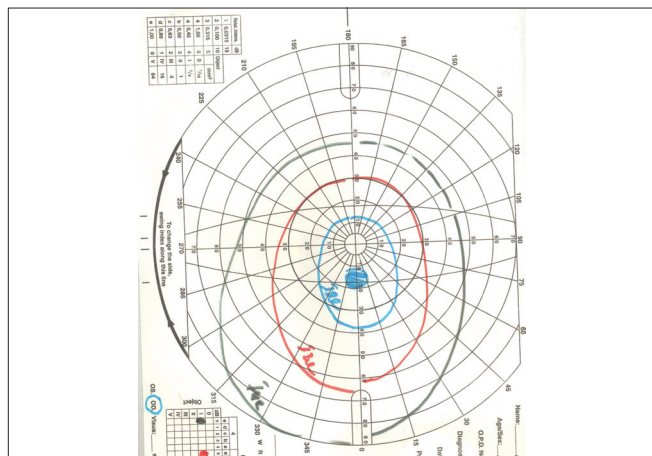
Dr. Rajendra Prasad Centre for Ophthalmic Sciences, <sup>1</sup>Department of NMR, All India Institute of Medical Sciences, New Delhi, India

**Correspondence to:** Dr. Rohit Saxena, Dr. Rajendra Prasad Centre for Ophthalmic Sciences, New Delhi, India. E-mail: [rohitsaxena80@yahoo.com](mailto:rohitsaxena80@yahoo.com)


**Manuscript received:** 18.08.10; **Revision accepted:** 26.07.11

The patient underwent a sub labial transseptal (SLTS) approach for excision of the sphenoid sinus mucocoele under general anesthesia within two weeks of diagnosis. At three weeks postoperatively he had recovered normal visual acuity

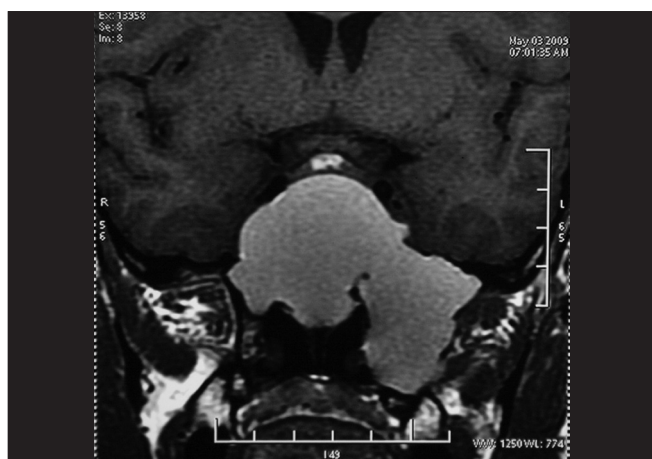
(20/20) but there was residual 0.3 log unit RAPD. The fundus examination was normal with no signs of optic disc pallor. The postoperative MRI done after three weeks showed no residual mucocoele [Fig. 4a and b].



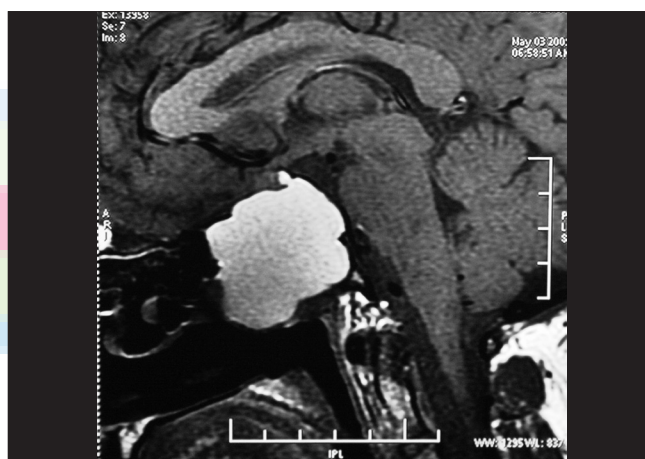**Figure 2a:** Goldmann visual field charting showing normal visual field and blind spot in the right eye



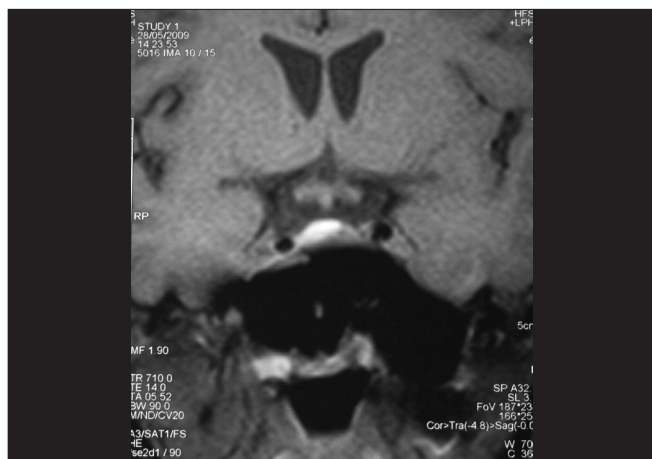
**Figure 2b:** Goldmann visual field charting showing (barring) and enlargement of blind spot size in the left eye



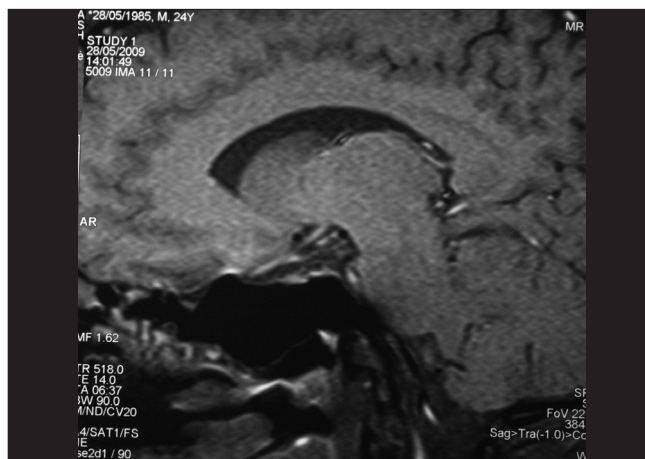
**Figure 3a:** Coronal image of patient showing T2 (hyperintense) lesion in the sphenoid sinus causing mass effect on the pituitary gland and the suprasellar cistern



**Figure 3b:** Sagittal image showing T1 hyperintense lesion filling and expanding the sphenoid sinus



**Figure 4a:** Postoperative coronal image of the same patient showing absence of a mass lesion in the sphenoid sinus



**Figure 4b:** Postoperative (sagittal) image of same patient showing normal aerated sphenoid with no residual lesion

## Discussion

Optic neuritis, an acute inflammatory disorder of the optic nerve, typically presents with sudden monocular loss of vision and eye pain in young adults, more commonly in women and is usually associated with multiple sclerosis. Inflammation of the optic nerve can be due to infection; such as certain viral infections (mononucleosis), herpes zoster, and others, as well as granulomatous processes including sarcoidosis, syphilis, tuberculosis, Cryptococcus, and Lyme's disease and secondarily to contiguous spread of inflammation from the meninges, sinuses or orbit. However, often, retro bulbar neuritis could be mimicked by compressive lesions of the brain, adenexa and sinus diseases.<sup>[1]</sup>

The optic nerve is affected in mucosal diseases due to the course of the optic canal which is variable from person to person; in 51% it is in the lateral and superior wall of the sphenoid sinus, while in 25% cases bone dehiscence of the optic canal is found which leads to direct exposure of the nerve through a thin sinus mucosa.<sup>[2]</sup> Sphenoid sinus mucocoeles are relatively rare, representing 1% of all paranasal sinus mucocoeles.<sup>[3,4]</sup> They usually start unilaterally, but by the time of presentation, the entire sphenoid sinus complex may be opacified and expanded with thinning of its bony walls. Cranial neuropathies are a feature in as many as 50% of cases.<sup>[5]</sup>

In sphenoid mucocoele the vision loss may be either due to the mass effect of the expanding mucocoele leading to disturbance in the blood supply of the optic nerve or by the involvement of the optic canal resulting in unilateral, slowly progressive loss of vision, which may terminate in optic atrophy.<sup>[6,7]</sup> In our case the patient presented with sudden painful acute diminution of vision which may be explained by inflammation as well as the vascular compromised state of the optic nerve by a large mucocoele. Treatment consists of marsupialization or surgical removal of the mucocoele, usually resulting in rapid regression of the ophthalmic manifestations.<sup>[8]</sup> Optic neuropathy seldom recovers if there is a delay in surgery for more than 10 days.<sup>[6]</sup> However, with prompt surgical drainage complete visual recovery occurs as in our case.

In a resource-constrained country like India where neuroimaging is usually not done in cases of ON as the diagnosis is essentially clinical, it is judicious to advise neuroimaging in patients of retro bulbar ON. As in our case while the Goldman fields in the left eye were not conclusive, neuroimaging revealed the presence of a large mucocoele with no sign of sinusitis, which was removed within a fortnight of diagnosis. This early diagnosis and prompt intervention helped in full visual recovery of the patient within a short period of one week.

## Conclusion

A neuroimaging study should be considered essential in cases of retro bulbar neuritis even in the presence of a single atypical feature.

## References

1. Vaphiades MS, Yunker JJ, Roberson GH, Meyer DR, Mills DM. Optic neuritis is nothing to sneeze at. *Surv Ophthalmol* 2007;52: 106-10.
2. McDeLano, Fun FY, Zinreich SJ. Relationship of the optic nerve to the posterior paranasal sinuses: A CT anatomic study. *AJNR Am J Neuroradiol* 1996;17:669-75.
3. Prepageran N, Subramaniam KN, Krishnan GG, Raman R. Ocular presentation of sphenoid mucocoele. *Orbit* 2004;23:45-7.
4. Sethi DS, Lau DP, Chan C. Sphenoid sinus mucocoele presenting with isolated oculomotor nerve palsy. *J Laryngol Otol* 1997;111: 471-3.
5. Ashwin PT, Mahmood S, Pollock WS. Sphenoid sinus mucocoele mimicking aneurysmal oculomotor nerve palsy. *Eye (Lond)* 2001;15:108-10.
6. Levy J, Monos T, Puterman M. Bilateral consecutive blindness due to sphenoid sinus mucocoele with unilateral partial recovery. *Can J Ophthalmol* 2005;40:506-8.
7. Johnson LN, Hepler RS, Yee RD, Batzdorf U. Sphenoid sinus mucocoele (anterior clinoid variant) mimicking diabetic ophthalmoplegia and retrobulbar neuritis. *AJNR Am J Neuroradiol* 1986;7:669-75.
8. Vaphiades MS, Roberson GH. Sphenoid sinus mucocoele presenting as third cranial nerve palsy. *J Neuroophthalmol* 2005;25:293-4.