



Short Communication

Resolution of Primary Aortic Thrombosis after Dabigatran therapy—A New Hope for the Rare and Old Disease

Pankaj Jariwala*, Satya Sridhar Kale

Department of Cardiology and Cardio-thoracic Surgery, Yashoda Hospitals, Raj Bhavan Road, Somajiguda, Hyderabad, Telangana, 500082, India

ARTICLE INFO

Article history:

Received 9 January 2019

Accepted 26 March 2019

Available online 1 April 2019

Keywords:

Primary aortic thrombosis

Direct oral anticoagulant

Vitamin K antagonist

Dabigatran

ABSTRACT

The primary aortic thrombosis (PAT) is an uncommon noncardiac cause of distal peripheral embolization to lower extremities. Also, this condition develops in the absence of extensive atherosclerosis of aorta or abnormal dilatation like aneurysm of the aorta. In most of the cases, there was either no or minimal atherosclerosis of the aorta. The disease can involve any part of the aorta, but in most of the cases, the thoracic aorta below the origin of the left subclavian artery followed by the infrarenal portion of the abdominal aorta was the most common site of involvement. In our case, there was extensive thrombosis starting from the lower part of the thoracic aorta extending across both the renal arteries up to the aortic bifurcation without any underlying aortic pathology or hypercoagulable disease. There are no guidelines for the management of the PAT, but our experience is based on few case series, case reports, and meta-analysis where there are variable success rate using conservative medical management, endovascular procedure, or surgical thrombectomy. Vitamin K antagonist was the drug of choice in all the cases as a part of conservative medical management or used to prevent recurrence after the endovascular or surgical procedure. We present a case of PAT where the use of dabigatran leads to complete resolution and prevented the recurrence of the disease during two-year follow-up, which is the first and unique case report of the literature.

© 2019 Cardiological Society of India. Published by Elsevier B.V. This is an open access article under the CC BY-NC-ND license (<http://creativecommons.org/licenses/by-nc-nd/4.0/>).

1. Short communication

A 53-year-old female, hypothyroid on replacement therapy, hypertensive on regular treatment, presented to the emergency room [ER] with complaints of progressive rest pain in both lower limbs of 2 days duration with pre-gangrenous changes involving fingers and the dorsum of the left foot [Fig. 1A]. On examination, she was hemodynamically stable but most conspicuous finding was absent left lower limb pulses. The ankle–brachial index was 0.31 of the left lower limb and that of the right lower limb was 0.84. Electrocardiogram showed poor 'R' wave progression secondary to hypertension with sinus tachycardia [Fig. 1C]. Her echocardiography did not show any evidence of chamber enlargement with the normal left and right ventricular function [Fig. 1B]. Electrophysiologist ruled out the possibility of paroxysmal atrial fibrillation as her heart was structurally normal. Ultrasound and bilateral arterial Doppler of both lower limbs suspected the presence of the

thrombus in the abdominal aorta with complete thrombotic occlusion of the mid-segment of the left superficial femoral artery with nonvisualization of the distal anterior tibial, posterior tibial, and popliteal artery and nonocclusive thrombosis of the right popliteal artery. Computed tomography (CT) angiography of the heart did not reveal the source of thrombus [Fig. 1D]. CT angiography of the aorta confirmed the findings of the aortic thrombosis in the lower part of thoracic aorta that extended across both the renal arteries up to the bifurcation [Fig. 1E, F, G] and further into the left iliofemoral system, popliteal artery, and common tibioperoneal arterial trunk. The abdominal aortic thrombus extended in to the left renal artery, leading to its complete occlusion [Fig. 1E, G]. The thrombus was eccentric and sessile without any free-floating component. A vascular surgeon performed bilateral embolectomy within an hour of her presentation to the ER, which relieved her symptoms partially with faint palpable distal pulses. But her symptoms recurred again the next day despite the use of the low-molecular-weight heparin (enoxaparin). Repeat Doppler of the left lower limb showed complete occlusion of the mid-distal femoral artery and popliteal artery.

* Corresponding author. Consultant Interventional Cardiologist, Yashoda Hospitals, Raj Bhavan Road, Somajiguda, Hyderabad, Telangana, 500082, India.

E-mail address: pankaj_jariwala@hotmail.com (P. Jariwala).

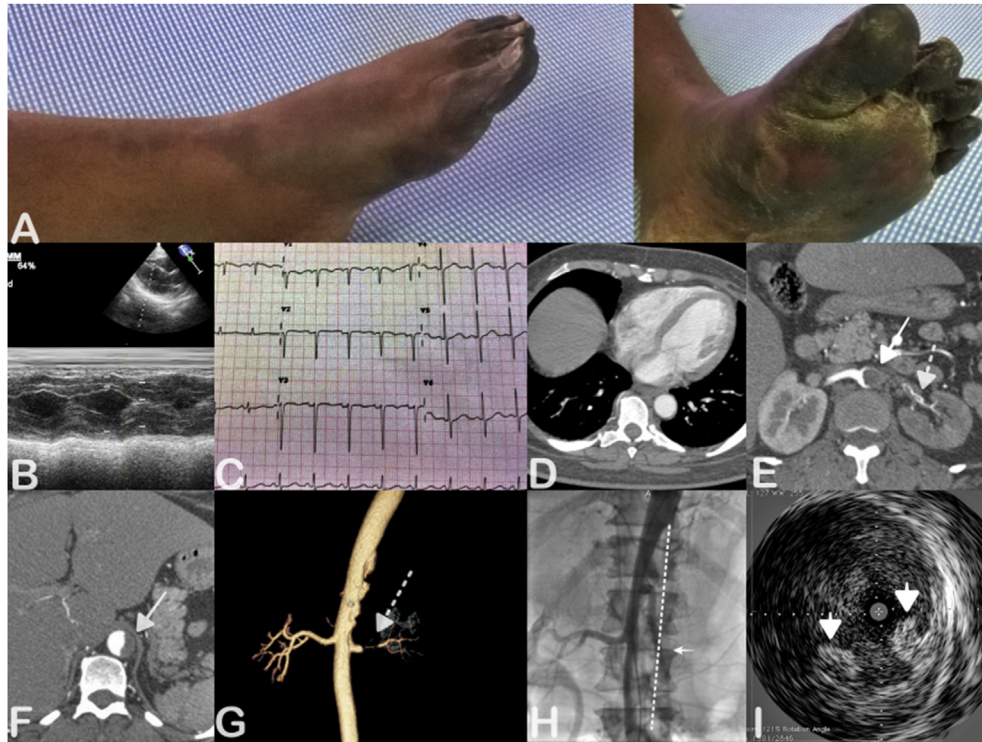


Fig. 1. (A–I): Clinical photograph of distal portion of the lower limb and foot showing acute gangrene of the all the fingers extending up as seen from the medial side (A) and middle part of dorsum of the foot. M-Mode echocardiography showing normal size and normal left ventricular function (ejection fraction, 70.4%). (B) Electrocardiogram showing sinus tachycardia and poor 'R' wave progression, suggestive of long standing hypertension and no evidence of any significant chamber enlargement and ischemia. (C) Computed tomography [CT] of chest showed normal size and dimensions of all the cardiac chambers, which ruled out cardiac cause of the peripheral embolism. (D) CT angiography of the aorta demonstrated a thrombus in the abdominal aorta (solid arrow, E) extending from T12 to L3 with occlusion of the left renal artery (dashed arrow, E, G) with the shrunken left kidney. It was an eccentric sessile abdominal aortic mural thrombus across the renal arteries without any free-floating component. Thrombus extended into the left iliac artery as patient had more symptoms affecting the left lower limb (H). Conventional angiography of the abdominal aorta using a pigtail catheter revealed the extent of thrombus from T11–T12 vertebral space up to the aortic bifurcation (solid black arrow, A; vertical dashed line, H) and mostly on the left side of the aorta (eccentric). PAT extended in to the left renal artery leading to its complete occlusion (solid white arrow, H). Intravascular ultrasound of the abdominal aorta revealed the presence of the sessile eccentric thrombus as seen in the 4–5° clock position and 7° clock position (white arrow heads, I). PAT, primary aortic thrombosis.

Meanwhile, she had accelerated hypertension (blood pressure, 210/100 mm Hg), which was controlled using intravenous labetalol; oral telmisartan 40 mg and amlodipine 5 mg. Prothrombin time was normal, whereas partial thromboplastin time was elevated twice the normal range. Her workup for the hypercoagulable state included carcinoembryogenic antigen, protein C & S, anti-thrombin III, antinuclear antibody and antiphospholipid antibody which were negative.

Checking angiogram on the next day morning revealed abdominal aorta thrombus (Figure H) with occlusion of the left renal artery with complete occlusion of the left popliteal and tibioperoneal artery. Intravascular ultrasound was performed which confirmed the findings of the CT angiography [Fig. 1]. The differential diagnosis of penetrating ulcer of the aorta or localized aortic dissection was ruled out. We tried percutaneous balloon angioplasty and thromboaspiration to recanalize the left popliteal and tibioperoneal artery and also overnight intra-arterial tenecteplase infusion at the rate of 0.5 mg/h through the perfusion catheter was given [pharmaco-mechanical dethrombosis strategy].

After 2 days, above knee amputation to the left leg was performed owing to progressive dry gangrene despite repeated attempts of recanalization. She was discharged with a prescription of dabigatran 150 mg twice daily, aspirin 75 mg, atorvastatin 80 mg, folic acid 5 mg, and antihypertensive medications.

At 6 months, 1-year, 2-year follow-ups, CT angiography demonstrated complete resolution of aortic thrombosis, with no recurrence of symptoms [Fig. 2A and B]. The right popliteal artery

showed complete occlusion with distal reformation through collaterals, and in view of the asymptomatic status, we decided for medical management. We continued dabigatran 110 mg twice daily to prevent recurrence with close follow-up.

In the vast majority of instances, the aortic thrombosis is secondary to atherosclerosis or embolism. Primary aortic thrombosis (PAT) is a rare and not much-known entity, which is defined as clotting of the aorta without any obvious or minimal atheromatous lesion.¹ It could be secondary to syphilitic aortitis, extrinsic pressure by tumors, pelvic peritonitis, irradiation to the abdomen, inflammatory diseases of the digestive tract, and acute episodes of pancreatitis.² Systemic conditions lead to hypercoagulable states such as cancer chemotherapy, cocaine intake, and essential thrombocythemia.

Intravenous contrast-enhanced multislice CT is the imaging modality of choice to investigate the disorder as it is widely available, noninvasive, and relatively cheap and can identify the extension of the thrombi and complications.²

Learmonth, Blackwood, and Richards recorded 4 cases in young adults in which peripheral arteries were affected and termed the condition 'localized arterial thrombosis of indeterminate origin' in 1944.³ Later, Leriche and Stricker reported a similar condition under the heading of "Spontaneous localized mono-arteritis of indeterminate origin". In all these previous studies, minute injuries, the result of muscular exertion or abnormally developed fascial bands, were considered to be possible causes.⁴ The most frequent location for the aortic thrombi is the region of the aortic isthmus and the

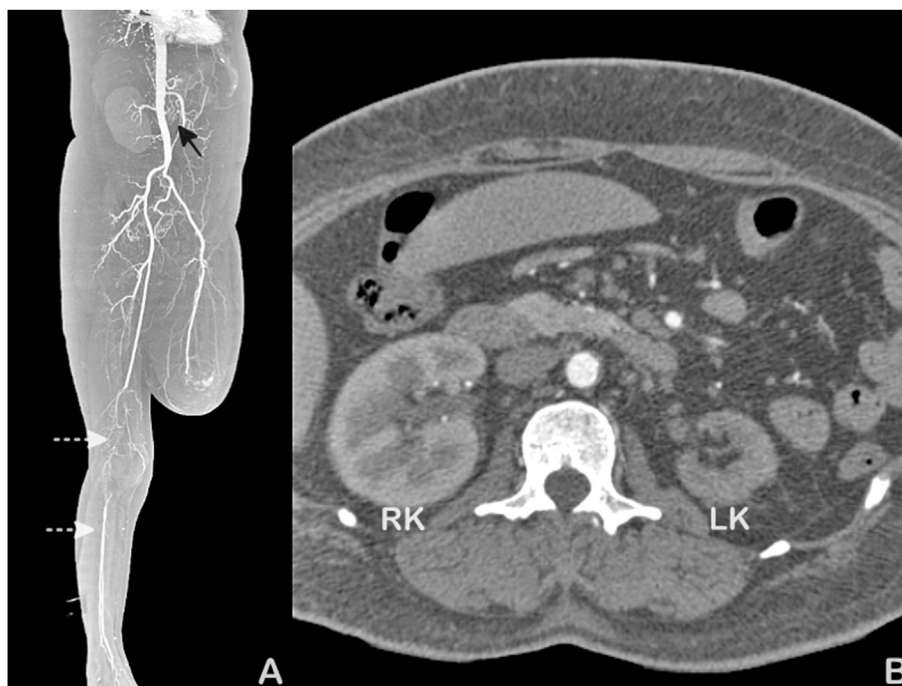


Fig. 2. (A, B): CT angiography of the aorta at the 1-year follow-up. The reconstructed image of the entire aorta (A) and cross-sectional view (B) showed the resolution of the aortic thrombus with occlusion of the left renal artery (solid black arrow) and shrunken LK. Also seen above knee amputated left lower limb with patent left iliofemoral system and occlusion of the left popliteal artery across the right knee joint with good opacification of the right tibioperoneal system through the collateral flow (dashed white arrows, A). RK, right kidney; LK, left kidney.

portion distal to the aortic arch, at the side opposite to the origin of the subclavian artery.¹

Varma et al. classified PAT into four types based on the anatomical location and morphological features of mural thrombus in the aorta. They described type III PAT as the presence of mural thrombus in the abdominal aorta extending from the coeliac artery to the lowest renal artery and type IV PAT as it extended below up to aortic bifurcation. They further classified the mural aortic thrombus into sessile and pedunculated subtypes depending upon the presence of floating component attached to the thrombus.⁵ In our case, it was combined type III and IV PAT and it was sessile subtype as there was no floating component. In their series, they studied 88 cases of peripheral embolization, out of which 19 cases were of PAT (21.6%). The thoracic aorta was a common site of location of thrombus followed by the infrarenal aorta and perivisceral aorta.

There is no general consensus for the management of this uncommon noncardiac cause of peripheral embolization. The treatment is based on the general guidelines for the management of acute limb ischemia. The definitive management of the PAT includes anticoagulation for sessile, small thrombus while endovascular stenting using stent graft for large or nonvisceral aortic thrombus. Open surgical aortic thrombectomy is reserved for the management of the visceral thoracoabdominal thrombus.^{6,7}

The anticoagulation was tried in some cases where they used intravenous heparin followed by oral anticoagulants in the form of vitamin K antagonists and reported complete resolution as in our case. But the risk of recurrent embolization was higher with the use of VKA; hence, many authors adopted an aggressive surgical or endovascular approach or combined hybrid approach in some of the cases where there was extensive thrombosis and risk of recurrent embolization was higher.⁸

Dabigatran is newer oral direct thrombin inhibitor (DOAC), which does not require monitoring and effective as a part of conservative medical management. Its efficacy was already

demonstrated in few cases where it leads to complete resolution of the left atrial and left ventricular thrombus.^{9,10} Also, humanized monoclonal antibody fragment (Fab), idarucizumab, is available when indicated in patients for the reversal of the anticoagulant effects in the event of life-threatening or uncontrolled bleeding.

In our case, dabigatran leads to complete resolution of PAT over the period of 6 weeks which was demonstrated during follow-up using CT aortography. There is no recurrence of the disease at 2 nd year follow-up. Our case is the first reported in the literature of resolution of the PAT using dabigatran.

With the availability of direct oral anticoagulants, the management of PAT should be relooked, and we need further evidence to demonstrate the efficacy of DOAC.

Conflict of interest

None.

Appendix A. Supplementary data

Supplementary data to this article can be found online at [55https://doi.org/10.1016/j.ihj.2019.03.005](https://doi.org/10.1016/j.ihj.2019.03.005).

References

- Fayad ZY, Semaan E, Fahoum B, Briggs M, Tortolani A, D'Ayala M. Aortic mural thrombus in the normal or minimally atherosclerotic aorta. *Ann Vasc Surg.* 2013;27:282–290.
- Verbeeck N, Cavez N, Plawny L, Weber J, Lens V. Primary aortic thrombosis: role of enhanced multislice CT demonstrated in three exceptional cases. *Jbr-Btr.* 2014;97:76–80.
- Learmonth JR, Blackwood W, Richards RL. Localised arterial thrombosis of indeterminate origin. *Edinb Med J.* 1944;2013:1.
- Ito S, Nakamura Y, Noumi T, Sasaki Y. Acute aortic thrombosis during cisplatin based chemotherapy for gastric cancer. *Intern Med.* 2013;52:973–975.
- Gaylis H. Primary aortic thrombosis. *Circulation.* 1958;XVII:941–944.

6. Verma H, Meda N, Vora S, George RK, Tripathi RK. Contemporary management of symptomatic primary aortic mural thrombus. *J Vasc Surg.* 2014;60:1524–1534.
7. Geha AS, El-Zein C, Massad MG, et al. Surgery for aortic arch thrombosis. *Thorac Cardiovasc Surg.* 2004;52:187–190.
8. Patrício C, Silva MM, Silva PE, Oliveira J, Bagulho L. Massive organ embolization from primary aortic thrombosis. *Rev Port Cardiol.* 2018;37:447.e1–447.e6.
9. Yamamoto T. Resolution of left ventricular thrombus after dabigatran therapy in two patients with old anteroseptal myocardial infarction. *Cardiovasc Pharmacol.* 2015;04:3–5.
10. Watanabe T, Shinoda Y, Ikeoka K, et al. Dabigatran therapy resulting in the resolution of rivaroxaban-resistant left atrial appendage thrombi in patients with atrial fibrillation. *Intern Med.* 2017;56:1977–1980.