

CASE REPORT

Sequence of oral manifestations in rhino-maxillary mucormycosis

Bharati R Doni, Basavaraj V Peerapur¹, Lathadevi Hassan Thotappa², Surekha B Hippargi³

Department of Oral Medicine and Radiology, Seema Dental College and Hospital, Rishikesh, Uttarakhand, Departments of ¹Microbiology, ²Ear Nose & Throat, and ³Pathology, B L D E University, Sri B M Patil Medical College, Hospital and Research centre, Bijapur, Karnataka, India

ABSTRACT

Mucormycosis, caused by saprophytic fungi of the order Mucorales of the class Zygomycetes, is a rare opportunistic fungal infection, which has a rapidly progressive and fulminant course with fatal outcome. These fungi are ubiquitous, found in soil, bread molds, decaying fruits and vegetables. The most common form of mucormycosis is rhinocerebral and is usually seen in uncontrolled diabetes mellitus or in immunocompromised patients. This fungus invades the arteries, leading to thrombosis that subsequently causes necrosis of hard and soft tissues. We report a case of palatal perforation by rhino-maxillary mucormycosis in an immunocompromised patient. The aim of this article is to draw attention to the clinical presentation and pathogenesis of mucormycosis and to emphasize the need for high degree of suspicion in its diagnosis and management.

Key words: Diabetes mellitus, mucormycosis, palatal perforation, rhino-maxillary

Received : 27-01-10
Review completed : 09-04-10
Accepted : 15-04-10

Mucormycosis is an opportunistic fungal infection caused by “bread mold fungi” of the genera *Mucor*, *Absidia*, *Rhizopus* and *Cunninghamella*, also collectively known as *Phycomycetes*.^[1,2]

Commonly, this disease occurs in persons with immunosuppression, diabetic ketoacidosis and those whom on antibiotics, steroid (or) cytotoxic therapy. Other predisposing factors include underlying malignancy, burns, malnutrition, blood dyscrasias and renal failure.^[3-21]

Biopsy confirms the diagnosis using hematoxylin and eosin (H and E), Gomori's methenamine silver (GMS), periodic acid-Schiff (PAS)^[1-4,6,7,15,16,22] and calcofluor white stains.^[2,22] It is cultured on Sabouraud's dextrose agar.^[5,8,16,18,23] However, negative culture results often appear despite positive histologic findings.^[19]

Address for correspondence:

Dr. Bharati R Doni
E-mail: bharatidoni@gmail.com

CASE REPORT

A 49-year-old male patient reported to the Department of Dentistry with chief complaint of pain and swelling on right side of the face since 7 days, ulcerative growth on right side of the palate since 4 days, and headache, earache and vomiting since 2 days. History revealed that the pain was sudden in onset, severe, throbbing and continuous in nature. It was associated with an extraoral swelling on right middle third of the face, followed by an intraoral ulcerative growth on the right side of palate. This ulcer growth was followed by earache, headache and later by vomiting.

Past medical history revealed that the patient was a known case of chronic renal failure with hypertension and type II diabetes mellitus and was on medication. He was on dialysis since 2 years. On general physical examination, the patient was moderately built and nourished with abnormal gait. His blood pressure was 180/90 mm of Hg, pulse rate was 92 beats/min and respiratory rate was 26 cycles/min. Extraoral examination revealed a diffuse swelling in middle third of the face, which was warm, tender and firm in consistency. The right submandibular lymph node was palpable, tender and mobile. Examination of nose revealed, foul-smelling brownish discharge from the right nostril [Figure 1].

On intraoral examination, maxillary lateral incisors were missing and fixed partial denture with mandibular anterior teeth and maxillary right posterior teeth was present. An

Access this article online	
Quick Response Code:	Website: www.ijdr.in
	DOI: 10.4103/0970-9290.84313

ulcerative lesion was noticed on the right half of the hard palate, which was measuring about 2×3 cm in diameter and covered with yellowish slough with everted borders and did not bleed on touch. It was extending from the right maxillary canine region to 1 cm in front of junction of hard and soft palate [Figure 2]. Based on these findings, a provisional diagnosis of squamous cell carcinoma of palate was made, and differential diagnosis of chronic granulomatous infection like fungal infection, tuberculosis and syphilis were included.

The patient was subjected to radiographs like maxillary occlusal and Water's projection. Occlusal radiograph revealed diffuse haziness on right half of the palate, and Water's projection revealed a diffuse, hazy lesion over right maxillary sinus with evidence of destruction of palatal bone with involvement of antrum. Considering the physical status, his past medical history and nasal discharge, the patient was referred to an ENT surgeon and a nephrologist for their opinion.

The ENT surgeon examined and arrived at clinical diagnosis of deep fungal infection. The patient was subjected to routine blood investigations, biochemical investigations, serological tests, biopsy and computed tomography (CT) scan. Hemogram showed reduced hemoglobin (5.2 g %), polymorphonuclear leukocytosis (total WBC count 12,000/mm³, N 90, L 10) and elevated erythrocyte sedimentation rate (ESR; 40 mm/1 hour). Biochemical investigations revealed random blood sugar 316 mg/dl, creatinine 3.7 mg/dl, urea 71 mg/dl, sodium 125 meq/l, and potassium 3.0 meq/l. Serological tests were normal.

Biopsy confirmed the diagnosis of mucormycosis using H and E, PAS and later by GMS stains. It revealed long, broad and nonseptate, irregularly folded hyphae which were branching at broad angles [Figure 3]. The fungal culture yielded no growth.

Contrast-enhanced CT scan of the coronal section (3/5 mm) of paranasal sinus revealed soft tissue density with sclerosis of bony wall in relation to right maxillary sinus and defect in maxillary bone in the floor of right maxillary sinus [Figure 4].

The patient was then managed by the ENT surgeon and nephrologist. Initially, surgical debridement of the affected tissue from right side of the nose with nose endoscopy was done, and after 1 week, he was managed by the nephrologist with anti-fungal and insulin therapy, i.e. Amphotericin-B given at dose of 1 mg/kg/day IV along with 5 ml of saline for 6 weeks. He was continuously monitored for signs of Amphotericin-induced renal toxicity. Daily monitoring of blood urea nitrogen (BUN), creatinine and blood sugar was continued throughout the therapy.

Sequence of events

1st and 2nd week: Surgical debridement with nose endoscopy was done and the case was diagnosed as mucormycosis after biopsy. Fixed partial denture in relation to maxillary right posterior region got dislodged by itself [Figure 2].

3rd–9th week: Amphotericin-B therapy + insulin therapy was started by nephrologists. During this course of treatment, headache, earache, vomiting and pain on right side of the face got reduced.

By the end of 9th week: The whole necrotic material of the hard palate got sloughed off, exposing the underlying bone, which was brownish in color [Figure 5].

10th week: Surgical debridement was repeated and further Amphotericin-B was continued for 2 more weeks.

At the end of 12th week: The bone got dislodged creating palatal perforation, and thus difficulty in feeding.

13th week: An obturator was given after which he was able to have semisolid and liquid food without much difficulty [Figure 6].

26th week: Surgical debridement was repeated, healing was noted.

30th week: Patient expired secondary to renal complication.

DISCUSSION

Mucormycosis is a rapidly progressive and often fatal opportunistic infection caused by fungi belonging to the class Zygomycetes/Phycomycetes, order mucorales.^[1-3,7-10,14,23] These fungi are ubiquitous,^[14,19,21,23,24] usually harmless and become pathogenic in man under certain conditions like immunosuppression, diabetic acidosis, antibiotic, steroids and cytotoxic therapy, with other predisposing factors like malignancy, burns, malnutrition, renal failure and blood dyscrasias.^[2-15,18-21] The present case had renal failure with hypertension and type II diabetes mellitus which is a well-known predisposing factor for mucormycosis. So, mucormycosis should be included in differential diagnosis whenever a patient with impaired immune response presents with spreading sinusitis or facial cellulitis with palatal ulcer.

This condition was first described by Paltauf in 1885 in human beings,^[8,16] but only in the past two decades the condition is being reported with increasing frequency.^[24] In dentistry, this condition gains increasing interest because of its first manifestation in the facial and oral tissue. Oral manifestations are usually in the palate where ischemic necrosis of the mucoperiosteum with bony denudation may occur,^[20] which was true in the case presented here.

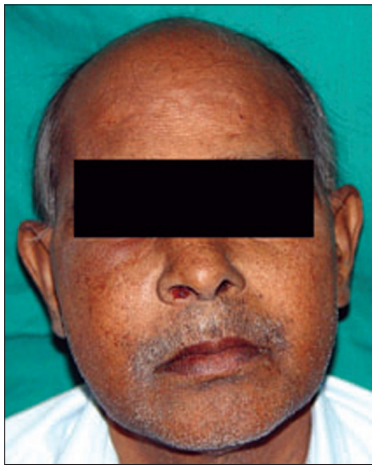

Figure 1: Extraoral photograph of the patient shows swelling on right middle third of the face and brownish discharge from the right nostril

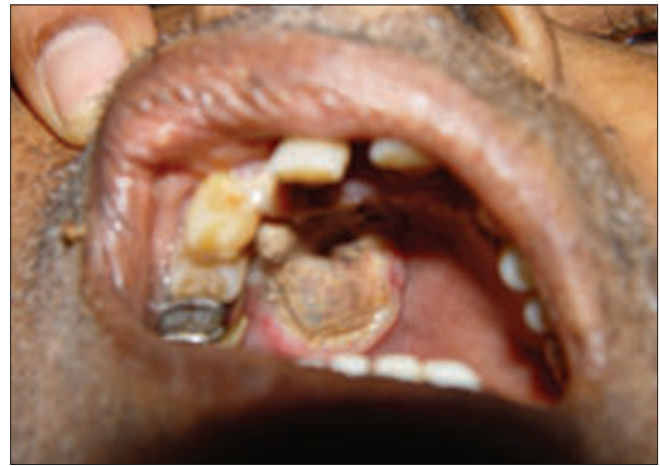

Figure 2: Intraoral photograph of the patient shows ulcerative lesion covered with yellowish slough with everted borders

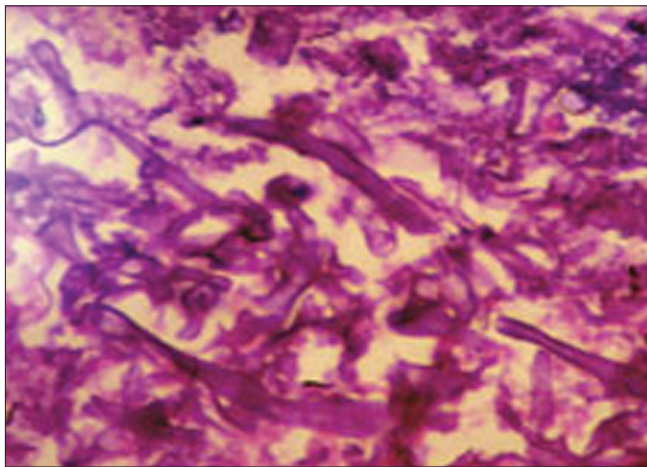


Figure 3: Photomicrograph of hard plate showing long, broad, nonseptate, irregularly folded mucormycosis hyphae branching at broad angles (H and E, $\times 400$)

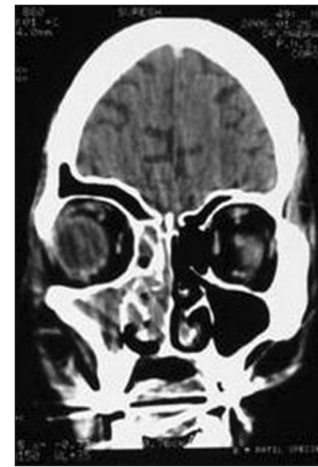

Figure 4: Coronal CT scan image reveals soft tissue density with sclerosis of bony wall of right maxillary sinus and defect in maxillary bone in the floor of right antrum

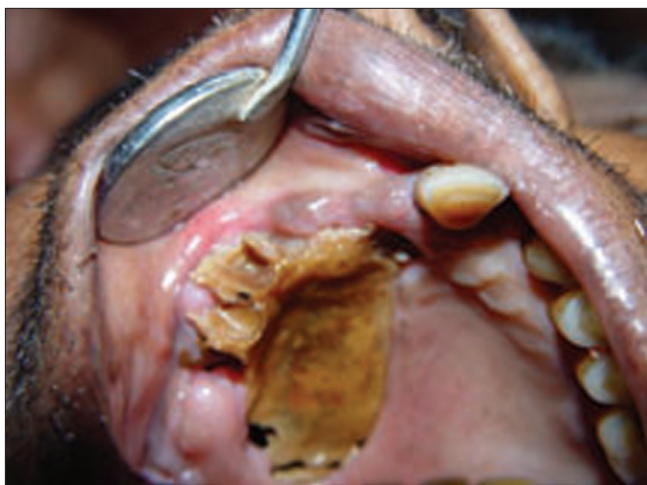

Figure 5: Intraoral photograph showing necrosis of palatal bone

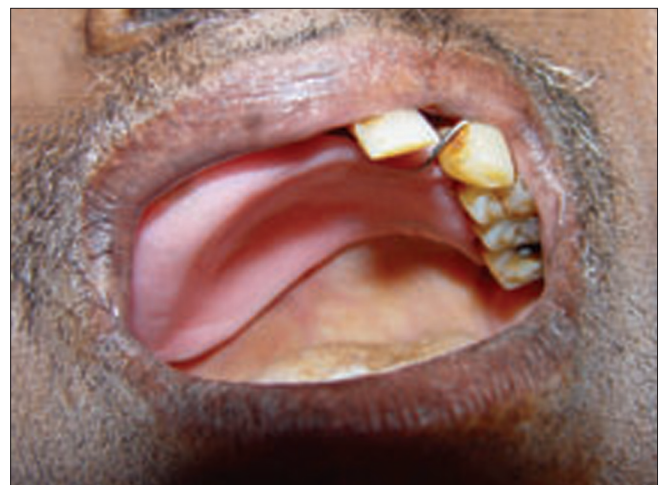

Figure 6: Intraoral photograph of the patient with obturator

But the ulcers of mucormycosis have also been reported on the gingiva, lips, alveolar ridge, cheeks, tongue and mandible.^[2,4,24]

The fungal spores enter through the nose or mouth in inhaled dirt particles and occasionally invade the orbit or open wounds.^[2-4,21,22] This infection usually begins in nasal

mucosa or palate and spreads into the paranasal sinuses, skin of the face, cribriform plate and brain, either by direct extension or through vascular channels.^[2,3,5,22,23,25] Once the fungus enters into the blood stream, it starts penetrating the arterial walls causing endothelial damage leading to intravascular thrombosis, infarction and tissue necrosis.^[3,5-8,10,12-14,16] Peripheral vascular disease in diabetic patients also causes local tissue ischemia and increased susceptibility to infection.^[6,15] Therefore, this relationship has been attributed to the development of palatal necrosis in this patient, with renal failure as an added factor.

Clinically, mucormycosis occurs in one of the four forms: rhinocerebral, pulmonary, gastrointestinal and disseminated.^[2-4,6,7,11,15,16,21] Rhinocerebral form is the most common,^[4,11] representing one-third to one-half of all cases of zygomycosis.^[2] This is further subdivided into two subtypes: a highly fatal rhino-orbito-cerebral form which is invasive and may involve the ophthalmic and internal carotid arteries and a less fatal rhino-maxillary form which involves the sphenopalatine and greater palatine arteries, resulting in thrombosis of the turbinate and necrosis of the palate.^[4,11,15]

Mucormycosis is aggressive and potentially fatal in diabetic patients because of impaired host defense mechanism and increased availability of micronutrients such as iron. Disseminated involvement of mucormycosis is observed in diabetic with ketoacidosis, which favors rapid proliferation of the fungus and its invasion into the orbit and cerebrum.^[6] In the case presented here, what is noteworthy is the fact that the infection did not spread to other organ systems in spite of uncontrolled diabetes mellitus and chronic renal failure. Therefore, the case is of rhino-maxillary form of the disease which is a subdivision of the well-documented rhinocerebral form.^[4,11,15] Therefore, a team of specialists including a dentist, an ENT surgeon, an ophthalmologist, a neurosurgeon, physicians and a maxillofacial surgeon is required for management of such patients. All published reports of mucormycosis state that the involvement of the hemi-palate is uncommon, being rarely recorded in cases of rhinocerebral mucormycosis.^[12] However, the present case showed involvement of hemi-palate during the course of the disease.

Involvement of the oral cavity usually appears as palatal ulceration or necrosis and later as perforation of the palate as a result of infection in the nasal cavity or paranasal sinuses via palatal vessels.^[4,16] In the early stage of disease, patients often exhibit facial cellulitis and anesthesia, nasal discharge, necrotic turbinates, fever, headache and lethargy.^[5,6,8,11,15,16,19,20,25] Except anesthesia, all these findings were present in this case.

Differential diagnosis of the lesion should include squamous cell carcinoma, chronic granulomatous infection like

tuberculosis, tertiary syphilis, midline lethal granuloma, Wegener's granulomatosis and other deep fungal infection.^[2,3,6,10,11,15,24] The case was provisionally diagnosed as squamous cell carcinoma of palate because squamous cell carcinoma presents as chronic persistent ulcer with raised margins and exposure of the underlying bone, with other features like local pain, swelling, epistaxis, nasal discharge, epiphora, diplopia or numbness.^[6,15] However, if the lesion is associated with diabetes mellitus or immunosuppression, a diagnosis of deep fungal infection is favored, which was later confirmed after histopathologic examination in this case. Recent reports have suggested that jaw necrosis can also occur in patients on bisphosphonate therapy.

Early diagnosis is critical because of rapid progression of this disease and is made on clinical findings, radiographic evaluation and identification of organisms by culture and histologic examination of the biopsy specimen. Radiographically, rhinocerebral mucormycosis demonstrated nodular thickening of the sinus necrosis, sinus opacification without fluid level and spotty destruction of paranasal sinuses.^[3,6,17] CT scan with contrast/magnetic resonance imaging (MRI) scan may demonstrate erosion or destruction of bone and may help to delineate the extent of the disease.^[2,3,8,23] as seen in our case. Culture on Sabouraud's dextrose agar is preferred, but histological examination of the biopsy specimen is conclusive which demonstrates long, broad, branching and nonseptate hyphae.^[18] In the present case, culture yielded no growth and the diagnosis was confirmed by histological examination of biopsy specimen using H and E, PAS and later by GMS stains.

As the disease progresses with alarming rapidity, prompt and aggressive therapy is essential.^[2] Successful treatment of mucormycosis consists of aggressive and repeated surgical debridement of necrotic tissue, systemic antifungal therapy and immediate control of underlying systemic diseases^[2-6,8,10-12,14-17,19-25] along with continuous monitoring of Amphotericin-induced nephrotoxicity.^[2-6,9,11,15,19,21,25] In the present case, surgical debridement of the affected tissue with nose endoscopy was performed along with Amphotericin-B (alternate day therapy) and insulin therapy. During this therapy, the patient was continuously monitored for signs of Amphotericin-induced renal toxicity by daily monitoring of BUN, creatinine and blood sugar. Rehabilitation of the patient, i.e. closure of palatal perforation, can be done surgically by using free flaps or by construction of a prosthetic appliance. In the present case, closure of palatal perforation was done with prosthetic appliance.^[3,15] Other treatment modalities include heparinization,^[25] avoidance of steroids,^[25] oral potassium iodide,^[9,18] supportive care with vitamin supplementation,^[18] hyperbaric oxygen therapy,^[2,8,10,24] granulocyte colony stimulating factor (G-CSF) and topical application of Amphotericin-B.^[10] But these treatment modalities were not tried in this case. A new triazole derivative, posaconazole, an oral antifungal agent,

has been tested recently.^[4,24] It has been used alone or in combination with Amphotericin-B with 80% cure rate.^[24] Mucormycosis was long regarded as a fatal infection with poor prognosis; but in the present case, the patient survived of mucormycosis and expired due to renal complication.

CONCLUSION

As is often the case, early diagnosis of the disease process is crucial for the success of subsequent treatment. We, dentists as oral physicians, often have the opportunity to make a diagnosis or proper referral during the incipient stage of a systemic disease, thereby reducing the mortality and morbidity rate secondary to systemic diseases.

ACKNOWLEDGMENTS

Dr. Ravindra L Minchnal, BDS, Senior Resident, Department of Dentistry, BLDE University, Sri BM Patil Medical College, Hospital and Research Centre, Bijapur, and Dr. Ravindra Madarki, Consulting Nephrologist and Director, Vaatsalya Hospital, Bijapur are gratefully acknowledged.

REFERENCES

- Samuelson J. Infectious Disease. In: Cotran RS, Vinaykumar, Collins T, editors. Robbins Pathologic Basis of Diseases. 6th ed, WB Saunders Company, Harcourt India Pvt Ltd: 2001. p. 380-81.
- Jayachandran S, Krithika C. Mucormycosis presenting as palatal perforation. Indian J Dent Res 2006; 17:139-42.
- Shetty SR, Punnya VA. Palatal mucormycosis: A rare clinical dilemma. Oral Surg 2008; 1:145-48.
- Woo SB, Greenberg MS. Ulcerative, vesiculous and bullous lesion. In: Greenberg MS, Glick M, Ship JA, editors. Burket's Oral Medicine. 11th ed, India; B C Decker Inc Hamilton: 2008. p. 74-5.
- Tabachnick TT, Levine B. Mucormycosis of the craniofacial structures. J Oral Surg 1975; 33:464-69.
- Tugsel Z, Sezer B, Akalin T. Facial swelling and palatal ulceration in a diabetic patient. Oral Surg Oral Med Oral Pathol Oral Radiol Endod 2004; 98:630-36.
- Hauman CH, Raubenheimer EJ. Orofacial Mucormycosis. Oral Surg Oral Med Oral Pathol 1989; 68:624-27.
- Goal S, Palaskar S, Shetty VP, Bushan A. Rhinomaxillary mucormycosis with cerebral extension. J Oral Maxillofac Pathol 2009; 13:14-7.
- Bhattacharyya AK, Deshpande AR, Nayak SR, Kirtane MV, Ingle MV, Vora IM. Rhinocerebral Mucormycosis: An unusual case presentation. J Laryngol Otol 1992; 106:48-9.
- Kyrmizakis DE, Doxas PG, Hajiioannou JK, Papadakis CE. Palatal ulcer due to mucormycosis. J Laryngol Otol 2002; 116:146-47.
- Cohen SG, Greenberg MS. Rhinomaxillary mucormycosis in kidney transplant patient. Oral Surg 1980; 50:33-8.
- Barrak HA. Hard palate perforation due to mucormycosis: Report of four cases. J Laryngol Otol 2007; 121:1099-102.
- MacSween RN, Whaley K. Microbial infections. In: Muir R, MacSween R, Roderick NM MacSween, Whaley K, editors. Muir's Text book of Pathology, 13th edn. US: Hodder Arnold; 1992. p. 334.
- Gluskin M, Solomon MP, Gold B, Corrado ML, Berger J. Mucormycotic slough of nasal floor and palate in the anephric patient. J Am Dent Assoc 1979; 98:224-27.
- Auluck A. Maxillary necrosis by mucormycosis: A case report and literature review. Med Oral Patol Oral Cir Bucal 2007; 12:E360-4.
- Jones AC, Bentsen TY, Freedman PD. Mucormycosis of the oral cavity. Oral Surg Oral Med Oral Pathol 1993; 75:455-60.
- Westhuijzen AJ, Grotepass FW, Wyma G, Padayachee A. A rapidly fatal palatal ulcer: Rhinocerebral mucormycosis. Oral Surg Oral Med Oral Pathol 1989; 68:32-6.
- Limongelli WA, Clark MS, Saglimbene R, Baden E, Washington JA, Williams AC. Successful treatment of mucocutaneous mucormycosis after dental extraction in a patient with uncontrolled diabetes. J Oral Surg 1975; 33:705-11.
- Breiman A, Sadowsky D, Friedman J. Mucormycosis. J Oral Surg 1981; 52:375-78.
- Ramon Y, Oberman M, Horowitz I, Freedman A. Extensive maxillary sequestration resulting from rhinocerebral mucormycosis. J Oral Surg 1977; 35:989-91.
- Cruickshank G, Vincent RD, Cherrick HM, Derby K. Rhinocerebral mucormycosis. J Am Dent Assoc 1977; 95:1164-168.
- Iatta R, Napoli C, Borghi E, Montagna MT. Rare mycoses of the oral cavity: A literature epidemiologic review. Oral Surg Oral Med Oral Pathol Oral Radiol Endod 2009; 108:647-55.
- Zapico ADV, Suarez AR, Encinas MP, Angulo CM, Pozuelo EC. Mucormycosis of the sinus in an otherwise healthy patient: Case report and literature review. J Laryngol Otol 1996; 110:471-73.
- Bonifaz A, Macias B, Farrera FP, Arias P, Ponce RM, Araiza J. Palatal zygomycosis: Experience of 21 cases. Oral Dis 2008; 14:569-74.
- Eilderton TE. Fatal postextraction cerebral mucormycosis in an unknown diabetic. J Oral Surg 1974; 32:297-300.

How to cite this article: Doni BR, Peerapur BV, Thotappa LH, Hippargi SB. Sequence of oral manifestations in rhino-maxillary mucormycosis. Indian J Dent Res 2011;22:331-5.

Source of Support: Nil, **Conflict of Interest:** None declared.