

Original Article

Intraocular soluble intracellular adhesion molecule-1 correlates with subretinal fluid height of diabetic macular edema

Dan Zhu, He Zhu, Chunyan Wang, Dayong Yang

Objective: To investigate the correlations between aqueous concentrations of vascular endothelial growth factor (VEGF), monocyte chemoattractant protein-1 (MCP-1), soluble intracellular adhesion molecule-1 (sICAM-1) and diabetic macular edema (DME). **Materials and Methods:** VEGF, MCP-1 and sICAM-1 concentrations in aqueous humor samples of 22 patients with DME and 23 patients with cataract of a control group were measured with solid-phase chemiluminescence immunoassay. **Results:** Aqueous VEGF (89.2 ± 58.5 pg/ml versus 48.5 ± 27.8 pg/ml, $P = 0.006$), MCP-1 (684.2 ± 423.4 pg/ml versus 432.4 ± 230.4 pg/ml, $P = 0.019$) and sICAM-1 (3213.8 ± 2581.6 pg/ml versus 260.2 ± 212.2 pg/ml, $P < 0.001$) all vary significantly between DME group and control group. Maximum height of submacular fluid measured by Optical coherence tomography (OCT) was significantly associated with aqueous sICAM-1 ($r = -0.45$, $P = 0.034$). The maximum height of macular thickness measured by OCT was not significantly associated with either VEGF ($P = 0.300$), MCP-1 ($P = 0.320$) or sICAM-1 ($P = 0.285$). **Conclusions:** Our results suggest that sICAM-1 may majorly contribute to the formation of subretinal fluid in DME patients and imply that MCP-1 and sICAM-1 may be the potential therapy targets, besides VEGF.

Key words: Diabetic macular edema, monocyte chemoattractant protein-1, soluble intracellular adhesion molecule-1, vascular endothelial growth factor

Access this article online

Website:
www.ijo.in

DOI:
10.4103/0301-4738.111184

Quick Response Code:



Diabetic Macular edema (DME) is the most common cause for visual damage in patients with diabetic retinopathy.^[1] Vascular endothelial growth factor (VEGF) is a vasopermeability factor^[2] and has been reported to be associated with DME.^[3] Encouraging outcome of intravitreal injections of anti-VEGF drugs for management of DME has been showed.^[4,5] However, as well as anti-VEGF pharmacotherapy, intravitreally administered anti-inflammatory substances as monotherapies have also showed positive effects in the therapy of DME.^[6-9] Particularly, a recent published randomized study showed that intravitreal triamcinolone appears to be more effective treatment for DME than bevacizumab, one widely used anti-VEGF drug.^[10] Therefore, in the era of anti-VEGF, one may postulate that the investigation of the roles of inflammatory factors in development of DME became more prominent.

Previous studies showed that vitreous levels of VEGF, monocyte chemoattractant protein-1 (MCP-1) and intercellular adhesion molecule-1 (ICAM-1) were related to retinal vascular permeability and the severity of DME.^[11] MCP-1 contributes to the recruitment of leukocytes to sites of injury in the angiogenesis,^[12,13] whereas more firm leukocyte-endothelial interactions and cell migration are governed by ICAM-1.^[14,15] Since the role of MCP-1 and ICAM-1 in DME have not been well established, it is the aim of this study to access the relationships between intraocular levels of MCP-1 and soluble ICAM-1 (sICAM-1), as well as VEGF, and the macular

characteristics of DME subjects showed by optical coherence tomography (OCT).

Materials and Methods

This study included 22 consecutive DME patients (22 eyes) who underwent intravitreal injection of triamcinolone and 23 consecutive cataract patients (23 eyes) who underwent cataract surgery. In our department, intravitreal triamcinolone was performed to the fovea-involved DME subjects with maximum fovea thickness over 250 μ m, based on the definition of clinically significant macular edema provided by the Early Treatment Diabetic Retinopathy Study group.^[1] Exclusion criteria included high myopia (refractive error < -6.00 diopter), glaucoma and other retinal diseases, such as age-related macular degeneration and retinal vascular occlusion. The cataract patients with diabetes history were also excluded.

Aqueous humor was collected during intravitreal injection or cataract surgery.^[9,16] All procedures conformed to the Declaration of Helsinki for research involving human subjects. This study was approved by the local Institutional Review Board and informed consent was obtained from all participants.

All patients underwent an ophthalmologic examination including refractometry, tonometry, and slit lamp assisted biomicroscopy of the anterior segment and posterior segment of the eye. For the diabetic macular edema patients, OCT (Topcon 3D OCT-1000) was performed. Subretinal fluid height and maximum retinal thickness of macula were manually measured by the same technician on OCT image using inbuilt software. Subretinal fluid height was defined as highest height between outer surface of neuroretina and retinal pigment epithelium reflection on OCT image of macula, and maximum retinal thickness of macula was defined as the vertical maximum distance between inner surface of neuroretina and outer surface of neuroretina on OCT image of macula.

Department of Ophthalmology, the Affiliated Hospital of Inner Mongolia Medical College, Hohhot, Inner Mongolia, China

Correspondence to: Prof. Dan Zhu, the Affiliated Hospital of Inner Mongolia Medical College, No.1 Tongdaobei Street, 010050, Hohhot, Inner Mongolia, P.R. China. E-mail: zhudnn@163.com

Manuscript received: 29.08.11; **Revision accepted:** 31.03.12

The concentration of aqueous VEGF, MCP-1 and sICAM-1 were measured using the suspension bead array technology on a LuminexTM 100 IS system. The method has been reported previously.^[17-20] Briefly, these mixtures of sample and capture microspheres were thoroughly mixed and incubated at room temperature for 1 h. Multiplexed cocktails of biotinylated reporter antibodies for each multiplex were then added robotically and were thoroughly mixed. Multiplexes were developed using an excess of streptavidin-phycoerythrin solution, which was thoroughly mixed into each multiplex and incubated. The volume of each multiplexed reaction was reduced by vacuum filtration and the volume increased by dilution into matrix buffer for analysis.

Statistical analysis was performed using commercial software (SPSS for Windows, version 13.0, SPSS, Chicago, IL). The OCT measurements were converted from millimeters to proportionally corresponding micrometers. Where appropriate, Pearson or Kendall's bivariate correlation test, and independent *t*-test were used. Two-tailed probabilities of less than 0.05 were considered to indicate statistical significance.

Results

There were 22 cases with diabetic macular edema as study group, as well as 23 cataract subjects as control group. Table 1 presents the clinical characteristics of the study participants. No significant differences were reached in characteristics including age, gender, intraocular pressure and spherical equivalent powers between diabetic macular edema cases and control subjects ($P > 0.05$).

Independent *t*-test showed that the aqueous VEGF vary significantly between DME group and control group (89.2 ± 58.5 pg/ml versus 48.5 ± 27.8 pg/ml, $P = 0.006$, Fig. 1). Similarly, aqueous MCP-1 (684.2 ± 423.4 pg/ml versus 432.4 ± 230.4 pg/ml, $P = 0.019$, Fig. 2) and sICAM-1 (3213.8 ± 2581.6 pg/ml versus 260.2 ± 212.2 pg/ml, $P < 0.001$, Fig. 3) also vary significantly between DME group and control group.

Pearson correlation test showed that the maximum height of submacular fluid measured by OCT was significantly associated with aqueous sICAM-1 ($r = -0.45$, $P = 0.034$; Fig. 4), and was not significantly associated with aqueous VEGF ($P = 0.395$) and MCP-1 ($P = 0.613$). According to the presence of subretinal fluid in macula, the DME patients were further divided into two groups (6 patients with submacular fluid and 16 patients without submacular fluid), and independent *t*-test showed that only sICAM-1 varied significantly between the two groups (Fig. 5, 1029.6

Table 1: Composition of the study population (mean \pm SD)

| | Diabetic Macular Edema | Cataract | <i>P</i> -value |
|--------------------------------------|------------------------|-----------------|-----------------|
| Number | 22 | 23 | |
| Age (years) | 71.0 \pm 5.6 | 74.4 \pm 10.3 | $P = 0.17$ |
| Female – no.(%) | 9 (41) | 11 (48) | $P = 0.64$ |
| Intraocular pressure (mmHg) | 15.4 \pm 3.3 | 16.1 \pm 3.5 | $P = 0.51$ |
| Spherical equivalent power(diopters) | 0.1 \pm 1.2 | -0.7 \pm 2.1 | $P = 0.15$ |

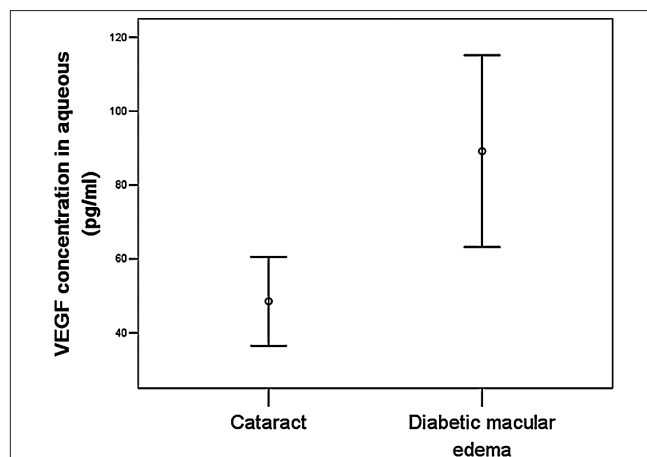


Figure 1: Error bar showing the vascular endothelial growth factor in aqueous humor between cataract patients (n = 23) and diabetic macular edema patients (n = 22) (independent *t*-test, 48.5 ± 27.8 pg/ml versus 89.2 ± 58.5 pg/ml, $P = 0.006$)

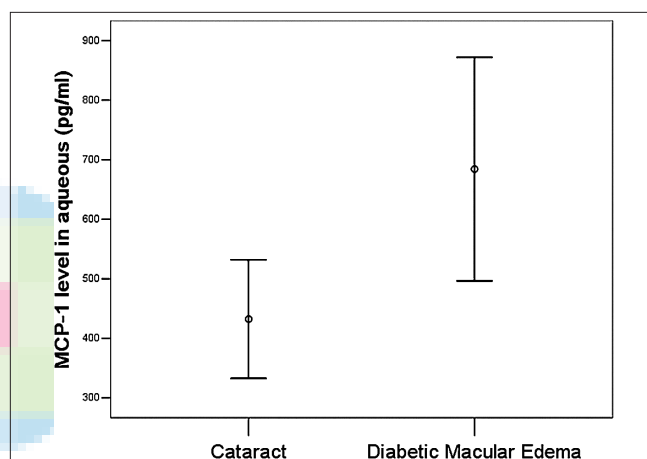


Figure 2: Error bar showing the monocyte chemoattractant protein-1 in aqueous humor between cataract patients (n = 23) and diabetic macular edema patients (n = 22) (independent *t*-test, 432.4 ± 230.4 pg/ml versus 684.2 ± 423.4 pg/ml, $P = 0.019$)

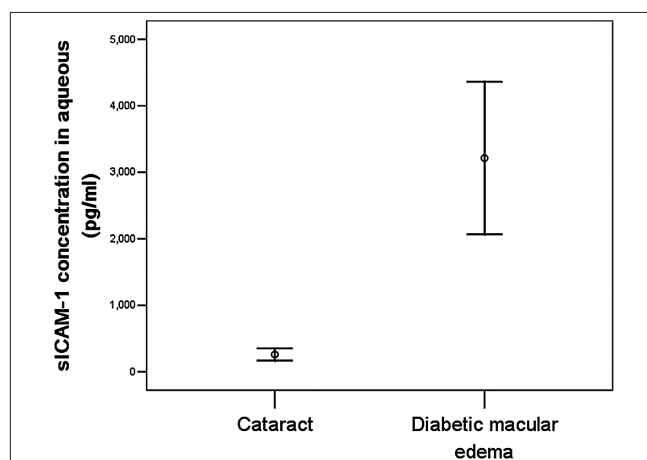


Figure 3: Error bar showing the soluble intercellular adhesion molecule-1 in aqueous humor between cataract patients (n = 23) and diabetic macular edema patients (n = 22) (independent *t*-test, 260.2 ± 212.2 pg/ml versus 3213.8 ± 2581.6 pg/ml, $P < 0.001$)

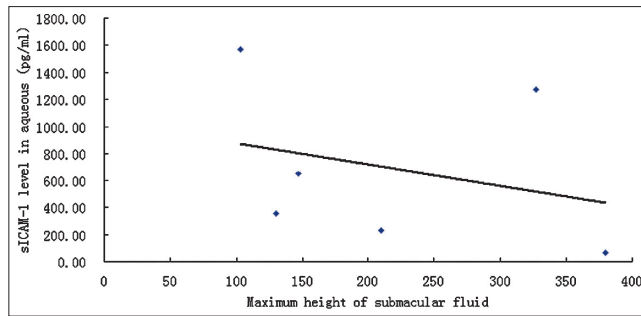


Figure 4: Regression figure showing that the maximum height of submacular fluid measured by OCT was negatively significantly associated with aqueous sICAM-1 ($r = -0.45$, $P = 0.034$)

± 542.1 pg/ml (95%Confidence interval: 460.7 pg/ml–1598.5 pg/ml) versus 4032.9 ± 2570.8 pg/ml (95% Confidence interval: 2663.0 pg/ml–5402.8 pg/ml); $P < 0.001$). MCP-1 (700.2 ± 463.2 pg/ml (95%Confidence interval: 214.1 pg/ml–1186.4 pg/ml) versus 678.2 ± 423.5 pg/ml (95%Confidence interval: 452.6 pg/ml–903.9 pg/ml); $P = 0.917$) and VEGF (103.5 ± 73.4 pg/ml (95% Confidence interval: 26.4 pg/ml–180.5 pg/ml) versus 83.8 ± 53.8 pg/ml (95%Confidence interval: 55.2 pg/ml–112.5 pg/ml); $P = 0.497$) did not vary significantly between the two groups.

Among all patients with DME, the maximum height of macular thickness measured by OCT was not significantly associated with either VEGF ($P = 0.300$), MCP-1 ($P = 0.320$) or sICAM-1 ($P = 0.285$).

Discussion

The results of this study showed that the aqueous level of VEGF, MCP-1 and sICAM-1 were all significantly higher in DME subjects than non-diabetes control, however, only the concentration of sICAM-1 was negatively significantly related with the height of submacular fluid ($r = -0.45$, $P = 0.034$). VEGF, MCP-1 and sICAM-1 were not significantly associated with the maximum height of macular thickness.

Immunoglobulin superfamily molecules, including ICAM-1, are key indicators of vascular endothelial cell activation.^[21] Blocking ICAM-1 activity with a neutralizing antibody suppresses both retinal leukostasis and breakdown of blood–retinal barrier.^[22] As might be expected, sICAM-1 binds competitively to ligands of membrane-bound ICAM-1, and therefore may have potential as a therapeutic to block leukocyte-endothelial interactions.^[23]

Despite that aqueous MCP-1 and VEGF were not significantly associated with the OCT measurements of macula, however, they were significantly higher than the non-diabetes control. Moreover, there are firm relationship between VEGF, MCP-1 and ICAM-1. It has been reported that VEGF can alter the conformation of tight junctions between retinal vascular endothelial cells^[24,25] and increases production of ICAM-1 by capillary endothelial cells in a dose- and time-dependent manner, while intravitreal injection of VEGF at pathophysiologically relevant concentrations increases ICAM-1 protein and mRNA levels in retinal vessel walls.^[26] Previous study showed that there was a significant correlation between

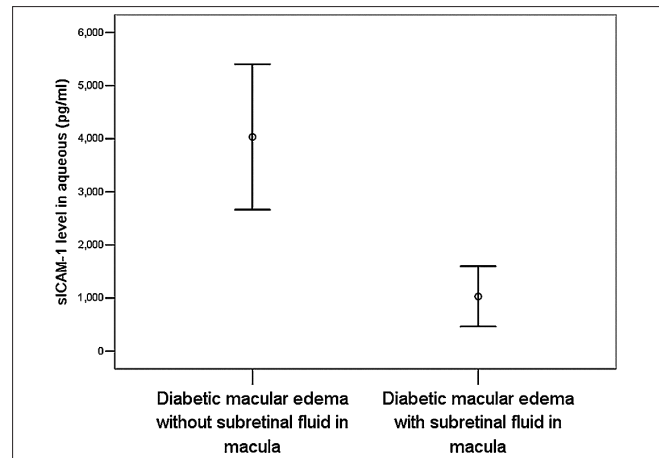


Figure 5: Error bar showing the soluble intracellular adhesion molecule-1 in aqueous humor between diabetic macular edema patients without subretinal fluid ($n = 16$) and diabetic macular edema patients with subretinal fluid ($n = 6$) (independent t -test, 4032.9 ± 2570.8 pg/ml versus 1029.6 ± 542.1 pg/ml; $P < 0.001$)

the vitreous fluid levels of MCP-1 and sICAM-1 ($r = 0.511$, $p < 0.001$) in the vitreous of proliferative diabetic retinopathy.^[27]

Recently, MCP-1 and its regulation by high glucose levels in vascular cells has been implicated in the pathogenesis of the inflammatory process associated with diabetes.^[28] *In vivo* angiogenesis assays showed that MCP-1-induced angiogenesis is as potent as that induced by VEGF.^[29]

Our results were in agreement with several previous studies. El-Asrar *et al.* found that vitreous levels of MCP-1 and sICAM-1 were higher in patients with active proliferative diabetic retinopathy compared with patients with inactive proliferative diabetic retinopathy and non-diabetic patients.^[27] Besides diabetic retinopathy, it was also reported that intraocular sICAM-1 level involved in the development of other retinal or choroidal vascular diseases. A recent published study showed that vitreous sICAM-1 levels were significantly higher in branch retinal vein occlusion patients with greater postoperative improvement of macular edema.^[30] Jonas *et al* found that intraocular MCP-1 concentrations were correlated with the amount of macular edema of neovascular age-related macular degeneration.^[19]

There were limitations in this study. First, the number of enrolled patients was not large, which may cover some minor significant association between factors. One may even argue that with a larger number of study participants, the correlations between aqueous concentrations of cytokines and thickness of macular edema may become statistically more significant. Second, only three cytokines were detected in this study, which fail to represent main pathological mechanism involved in the development of DME. Thirdly, aqueous humor samples may be not as valuable as vitreous fluid for the detection of cytokine concentration of fundus diseases. However, obtaining vitreous samples needs to expand the surgical intervention while DME was not the surgical indication of vitrectomy in the most cases. Fourthly, the negative correlation between sICAM-1 and the height of submacular fluid provides evidence to, but not mean that sICAM-1 induces the formation submacular fluid.

In conclusion, this study is the first to show that the aqueous level of sICAM-1 negatively significantly correlated with the subretinal fluid height of DME patients. The aqueous levels of VEGF, sICAM-1 and MCP-1 were significantly higher in DME subjects and control cases. As such, MCP-1 and ICAM-1, especially the latter, may be additional target molecules in therapy for development of DME.

References

- Klein R, Klein BE, Moss SE. Visual impairment in diabetes. *Ophthalmology* 1984;91:1-9.
- Aiello LP, Bursell SE, Clermont A, Duh E, Ishii H, Takagi C, *et al.* Vascular endothelial growth factor-induced retinal permeability is mediated by protein kinase C *in vivo* and suppressed by an orally effective beta-isoform-selective inhibitor. *Diabetes* 1997;46:1473-80.
- Campochiaro PA. Targeted pharmacotherapy of retinal diseases with ranibizumab. *Drugs Today (Barc)* 2007;43:529-37.
- Ozturk BT, Kerimoglu H, Bozkurt B, Okudan S. Comparison of intravitreal bevacizumab and ranibizumab treatment for diabetic macular edema. *J Ocul Pharmacol Ther* 2011;27:373-7.
- Witkin AJ, Brown GC. Update on nonsurgical therapy for diabetic macular edema. *Curr Opin Ophthalmol* 2011;22:185-9.
- Tao Y, Jonas JB. Intravitreal triamcinolone. *Ophthalmologica* 2011;225:1-20.
- Jonas JB, Kreissig I, Söfker A, Degenring RF. Intravitreal injection of triamcinolone for diffuse diabetic macular edema. *Arch Ophthalmol* 2003;121:57-61.
- Massin P, Audren F, Haouchine B, Erginay A, Bergmann JF, Benosman R, *et al.* Intravitreal triamcinolone acetate for diabetic diffuse macular edema: Preliminary results of a prospective controlled trial. *Ophthalmology* 2004;111:218-24; discussion 224-5.
- Meyer CH, Krohne TU, Holz FG. Intracocular pharmacokinetics after a single intravitreal injection of 1.5 mg versus 3.0 mg of bevacizumab in humans. *Retina* 2011;31:1877-84.
- Shahin MM, El-Lakkany RS. A prospective, randomized comparison of intravitreal triamcinolone acetate versus intravitreal bevacizumab (avastin) in diffuse diabetic macular edema. *Middle East Afr J Ophthalmol* 2010;17:250-3.
- Funatsu H, Noma H, Mimura T, Eguchi S, Hori S. Association of vitreous inflammatory factors with diabetic macular edema. *Ophthalmology* 2009;116:73-9.
- Ishida S, Yamashiro K, Usui T, Kaji Y, Ogura Y, Hida T, *et al.* Leukocytes mediate retinal vascular remodeling during development and vaso-obliteration in disease. *Nat Med* 2003;9:781-8.
- Nakao S, Kuwano T, Tsutsumi-Miyahara C, Ueda S, Kimura YN, Hamano S, *et al.* Infiltration of COX-2-expressing macrophages is a prerequisite for IL-1 beta-induced neovascularization and tumor growth. *J Clin Invest* 2005;115:2979-91.
- Cronstein BN, Weissmann G. The adhesion molecules of inflammation. *Arthritis Rheum* 1993;36:147-57.
- Mackay CR, Imhof BA. Cell adhesion in the immune system. *Immunol Today* 1993;14:99-102.
- Campochiaro PA, Choy DF, Do DV, Hafiz G, Shah SM, Nguyen QD, *et al.* Monitoring ocular drug therapy by analysis of aqueous samples. *Ophthalmology* 2009;116:2158-64.
- Sharma RK, Rogojina AT, Chalam KV. Bevacizumab therapy normalizes the pathological intraocular environment beyond neutralizing VEGF. *Mol Vis* 2010;16:2175-84.
- Sharma RK, Rogojina AT, Chalam KV. Multiplex immunoassay analysis of biomarkers in clinically accessible quantities of human aqueous humor. *Mol Vis* 2009;15:60-9.
- Jonas JB, Tao Y, Neumaier M, Findeisen P. Monocyte chemoattractant protein 1, intercellular adhesion molecule 1, and vascular cell adhesion molecule 1 in exudative age-related macular degeneration. *Arch Ophthalmol* 2010;128:1281-6.
- Jonas JB, Neumaier M. Vascular endothelial growth factor and basic fibroblast growth factor in exudative age-related macular degeneration and diffuse diabetic macular edema. *Ophthalmic Res* 2007;39:139-42.
- Long EO. ICAM-1: Getting a grip on leukocyte adhesion. *J Immunol* 2011;186:5021-3.
- Miyamoto K, Khosrof S, Bursell SE, Rohan R, Murata T, Clermont AC, *et al.* Prevention of leukostasis and vascular leakage in streptozotocin-induced diabetic retinopathy via intercellular adhesion molecule-1 inhibition. *Proc Natl Acad Sci U S A* 1999;96:10836-41.
- Lawson C, Wolf S. ICAM-1 signaling in endothelial cells. *Pharmacol Rep* 2009;61:22-32.
- Vinore SA, Derevanik NL, Ozaki H, Okamoto N, Campochiaro PA. Cellular mechanisms of blood-retinal barrier dysfunction in macular edema. *Doc Ophthalmol* 1999;97:217-28.
- Gardner TW, Antonetti DA, Barber AJ, Lieth E, Tarbell JA. The molecular structure and function of the inner blood-retinal barrier. *Penn State Retina Research Group. Doc Ophthalmol* 1999;97:229-37.
- Lu M, Perez VL, Ma N, Miyamoto K, Peng HB, Liao JK, *et al.* VEGF increases retinal vascular ICAM-1 expression *in vivo*. *Invest Ophthalmol Vis Sci* 1999;40:1808-12.
- El-Asrar AM, Nawaz MI, Kangave D, Geboes K, Ola MS, Ahmad S, *et al.* High-mobility group box-1 and biomarkers of inflammation in the vitreous from patients with proliferative diabetic retinopathy. *Mol Vis* 2011;17:1829-38.
- Dragomir E, Simionescu M. Monocyte chemoattractant protein-1—a major contributor to the inflammatory process associated with diabetes. *Arch Physiol Biochem* 2006;112:239-44.
- Hong KH, Ryu J, Han KH. Monocyte chemoattractant protein-1-induced angiogenesis is mediated by vascular endothelial growth factor-A. *Blood* 2005;105:1405-7.
- Noma H, Funatsu H, Mimura T, Eguchi S, Shimada K. Visual prognosis and vitreous molecules after vitrectomy for macular edema with branch retinal vein occlusion. *Clin Ophthalmol* 2011;5:223-9.

Cite this article as: Zhu D, Zhu H, Wang C, Yang D. Intracocular soluble intracellular adhesion molecule-1 correlates with subretinal fluid height of diabetic macular edema. *Indian J Ophthalmol* 2014;62:295-8.

Source of Support: Nil, **Conflict of Interest:** None declared.