

Subcutaneous local recurrence of parathyroid carcinoma

R Fernando¹, KCD Mettananda², BLH Balasooriya³ and HJ de Silva⁴

A 50-year old man, diagnosed with hyperparathyroidism secondary to a parathyroid carcinoma, presented with abdominal pain and a recurrent left-sided neck lump (Figure 1).

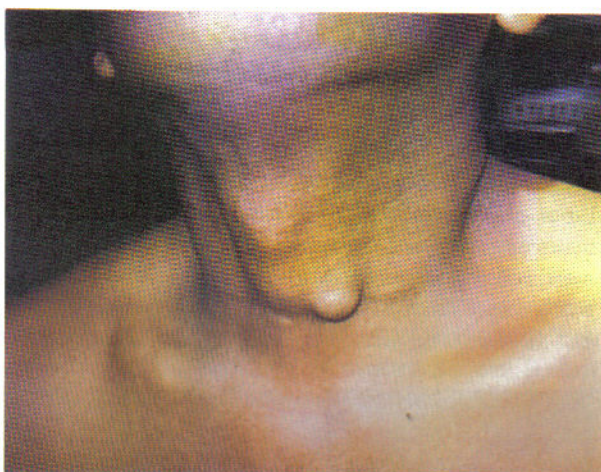


Figure 1. Lump in front of neck.

He had undergone excision of a left parathyroid nodule 7 years ago followed by left thyroid lobectomy after histology confirmed a parathyroid carcinoma. Two years later he was re-explored, and a thyroid bed local recurrence of parathyroid carcinoma was found. This was excised along with complete thyroidectomy, and he was referred for radiotherapy. He was then asymptomatic for 5 years.

On the current presentation, he had a subcutaneous left-sided neck lump. Serum calcium was 3.6 mmol/l and PTH was 476 pg/ml. FNAC of the lump suggested a secondary deposit of parathyroid carcinoma. Tc-methoxyisobutylisonitrile scan revealed faint tracer localization on left side of neck. A wide local excision of the secondary deposit was performed, and excision biopsy showed an encapsulated lesion measuring 6.5mm in diameter with

moderate cellular atypia, and fibrous septa extending through the tumour (Figure 2), indicating a local recurrence of parathyroid carcinoma.

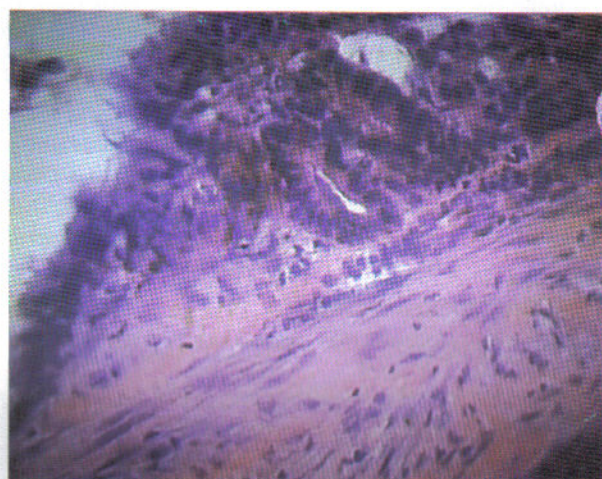


Figure 2. Histology of excised lump.

Parathyroid carcinoma is rare, and accounts for 1% to 5% of all cases of primary hyperparathyroidism [1]. In spite of en bloc resection [2], recurrence of the tumour occurs in 30% to 70% of patients. Aggressive resection of operable metastatic lesions is advocated even with multiple metastases, as the reduction in volume of tumour improves hypercalcaemia and prognosis. The present case describes subcutaneous local recurrence of a parathyroid carcinoma.

References

1. Poissonnet G, Castillo L, Bozec A, Peyrottes I, Ettore F, Santini J, et al. Parathyroid carcinoma. *Bulletine du Cancer* 2006; **93**: 283-7.
2. Fujimoto Y, Obara T. How to recognize and treat parathyroid carcinoma. *Surgical Clinics of North America* 1987; **67**: 343-57.

¹ Senior Lecturer, Department of Surgery, Faculty of Medicine, University of Kelaniya. ^{2,3} Intern Medical Officers, Professorial Surgical Unit, North Colombo Teaching Hospital, Ragama. ⁴ Professor of Medicine, Faculty of Medicine, University of Kelaniya, Sri Lanka. Received 7 July and accepted 15 November 2006.
Correspondence: KCDM, e-mail: <Chamilametta@hotmail.com>