

Original Article

Surgical outcomes of microincision vitrectomy surgery in eyes with retinal detachment secondary to retinopathy of prematurity in Indian population

Parveen Sen, Pramod Bhende, Tarun Sharma, Lingam Gopal, Aditya Maitray, Prateek Shah, Yogendra Oke

Purpose: To analyze and report outcomes of microincision vitrectomy surgery (MIVS) for Stage 4 and 5 retinopathy of prematurity (ROP). **Methods:** Medical records of 202 eyes of 129 premature children undergoing MIVS for Stage 4/Stage 5 ROP between January 2012 and April 2015 were evaluated. The primary outcome measure was the proportion of eyes with anatomical success (defined as attached retina at the posterior pole at last follow-up). Complications associated with MIVS were noted and analysis of risk factors associated with poor anatomical outcome was also done using logistic regression. **Results:** Mean age of presentation of babies with Stage 4 ROP (2.9 ± 1.75 months) was lower than those with stage 5 disease (5.62 ± 2.55 months) ($P < 0.005$). One hundred seventeen eyes (56% or 58%) had Stage 5, 38 (19%) had Stage 4a, and 47 (23%) Stage 4b. Ninety-four eyes (47%) had received prior treatment (laser and/or anti-vascular endothelial growth factors [VEGF]). Lens-sparing vitrectomy (LSV) was performed in 58 (29%) eyes while lensectomy with vitrectomy (LV) was performed in 144 (71%) eyes. At a mean follow-up of 32.5 weeks, 102 (50.5%) eyes achieved anatomical success, including 74% eyes in Stage 4a and 4b and 33% in Stage 5. Complications included intraoperative break formation (19%), postoperative vitreous hemorrhage (28%), raised intraocular pressure (12.7%), and cataract progression (2.4%). Factors significantly associated with favorable anatomical outcome were Stage 4 disease (vs. Stage 5) (odds ratio [OR] 5.8; confidence interval [CI] = 2.6–13.8, $P < 0.005$), prior treatment (laser \pm anti-VEGF) (OR 2.5; CI 1.4–4.7, $P < 0.005$) surgery with 25G MIVS (vs. 23G) (OR: 1.7; CI = 0.98–3.00, $P = 0.05$) and LSV (vs. LV) (OR 7; CI = 3.4–14.6, $P < 0.005$). Retinal break was significantly associated with poor anatomical outcome (OR 0.21; CI = 0.09–0.5, $P < 0.005$). **Conclusion:** MIVS along with wide angle viewing systems allow surgeons to effectively manage ROP surgeries while at the same time reducing complication rate in these eyes which have complex pathoanatomy and otherwise grim prognosis.

Key words: Microincision vitrectomy surgery, retinal detachment, retinopathy of prematurity, Stage 4, Stage 5, surgical outcome, vitrectomy

Retinopathy of prematurity (ROP) develops in premature and low birth weight infants born with incomplete retinal vascularization. CRYO-ROP and ETROP (Early treatment Retinopathy of prematurity) trials gave an insight into the natural history of the disease and established management guidelines.^[1,2] The ETROP study showed that, despite screening and prompt management, approximately 12% of the eyes can progress to retinal detachment due to proliferative retinopathy.^[2] Furthermore, lack of awareness, lack of availability of specialized care and access to timely screening further complicates the management of this potentially blinding disease in developing countries like India, especially in view of improved survival of extremely premature infants (22–26 week gestational age).^[3] Once tractional retinal detachment (TRD) sets in, surgical intervention in the form of vitrectomy becomes essential to relieve the traction and to eliminate the scaffold for further fibrovascular growth as well as remove the excessive levels of vascular endothelial growth factors (VEGF).^[4,5]

Microincision vitrectomy surgery (MIVS) has the advantage of minimal ocular surface disruption, increased the ability to

access in between tight retinal folds by the surgeon and reduced surgical trauma resulting in faster and better postoperative recovery.^[6] It is being almost universally used for most of the vitreoretinal procedures. The present study reports the anatomical outcome of MIVS performed in eyes with retinal detachment due to ROP in Indian infants.

Methods

This study adhered to the tenets of Declaration of Helsinki. Prior institutional review board approval was obtained. Retrospective analysis of medical case records of the premature babies that had undergone surgical intervention with MIVS for Stage 4a, 4b, or 5 ROP between January 2012 and April 2015 was performed. The data collected included gestational age, birth weight, age at presentation, mean age at surgical intervention, ROP stage at initial presentation, lens status, prior treatment

This is an open access journal, and articles are distributed under the terms of the Creative Commons Attribution-NonCommercial-ShareAlike 4.0 License, which allows others to remix, tweak, and build upon the work non-commercially, as long as appropriate credit is given and the new creations are licensed under the identical terms.

For reprints contact: reprints@medknow.com

Cite this article as: Sen P, Bhende P, Sharma T, Gopal L, Maitray A, Shah P, et al. Surgical outcomes of microincision vitrectomy surgery in eyes with retinal detachment secondary to retinopathy of prematurity in Indian population. Indian J Ophthalmol 2019;67:889-95.

Department of Vitreoretinal Services, Shri Bhagwan Mahavir Vitreoretinal Services, Sankara Nethralaya, Chennai, Tamil Nadu, India

Correspondence to: Dr. Parveen Sen, Shri Bhagwan Mahavir Vitreoretinal Services, Sankara Nethralaya, 18, College Road, Chennai - 600 006, Tamil Nadu, India. E-mail: parveensen@gmail.com

Manuscript received: 24.10.17; **Revision accepted:** 28.11.17

Access this article online

Website:

www.ijo.in

DOI:

10.4103/ijo.IJO_1030_17

Quick Response Code:



received before progression to RD (laser, intravitreal anti-VEGF injection), surgical details including type of surgery, gauge of vitrectomy, intraoperative events, postoperative complications, and anatomical outcome at the last follow-up.

The primary outcome measure was the proportion of eyes that achieved anatomical success, defined as attached retina at the posterior pole at the last follow-up. Complications associated with MIVS were noted and analysis of risk factors associated with poor anatomical success was done.

Surgical technique

All surgeries were performed under general anesthesia after obtaining an informed written consent for surgery from the parents. 23, 25, or 27 gauge (G) systems were used [Fig. 1 a]. The Alcon Constellation system was used with a vacuum of 100–300 and cutting rates of 1000–5000 cuts per minute. In eyes with posterior synechiae/inadequately dilating pupil, temporary iris hooks (Grieshaber, Switzerland) were used.

In lens-sparing vitrectomies (LSVs), sclerotomies were placed 1–1.5 mm from limbus, carefully avoiding areas with presence of anterior retinal folds as seen after indirect ophthalmoscopy, to avoid the occurrence of retinal break or dialysis during vitrectomy. Three-port vitrectomy was done as it allows easy exchange of instruments during surgery without causing hypotony. Some modifications from the conventional MIVS technique were necessary for these small eyes. For superior two sclerotomies trocar, cannulas were not used if the palpebral fissure was too small to allow manipulations with the trocar cannulas *in situ*. In those cases, direct sclerotomies were made using microvitrectoretinal (MVR) blade. To facilitate bimanual membrane dissection, combination instruments like infusion cannula with light pipe were used whenever deemed necessary as per surgeons' judgment. 25 G chandelier illumination was used for 4-port vitrectomy as and when required [Fig. 1b] Preretinal membrane removal to the extent possible was done without causing iatrogenic breaks. Purpose of the surgery was removal of preretinal membranes and proliferative tissue causing "ridge to ora serrata," "ridge to ridge," and "ridge to lens" traction.

Lensectomy with vitrectomy (LV) was performed in all cases with Stage 5 ROP with retrolental fibroplasia (RLF) [Fig. 1c and d], and selective Stage 4 cases where traction was too peripheral or the ridge was too close to the posterior capsule to spare the lens. Limbal approach for surgery was preferred for some cases where the retina was pulled up very anteriorly while pars plicata approach similar to LSV was done in others. In the limbal approach side ports at the limbus were used to introduce the 23/25/27G instruments in the eye to remove the lens as well as complete the dissection. The lens was removed using a vitrectomy probe under low suction. In Stage 5 ROP with RLF, this was followed by cruciate incisions into the RLF to expose the underlying retina. Although initial dissection was performed bimanually under viscoelastic fill under coaxial illumination of the operating microscope, anterior chamber (AC) maintainer to keep the IOP under control during surgery was used in all cases. The preretinal tissue was removed to extent possible using 23/25 gauge intraocular forceps and scissors (Alcon, Fort Worth, Tex). The dissection was continued till the posterior funnel was opened up with removal of the

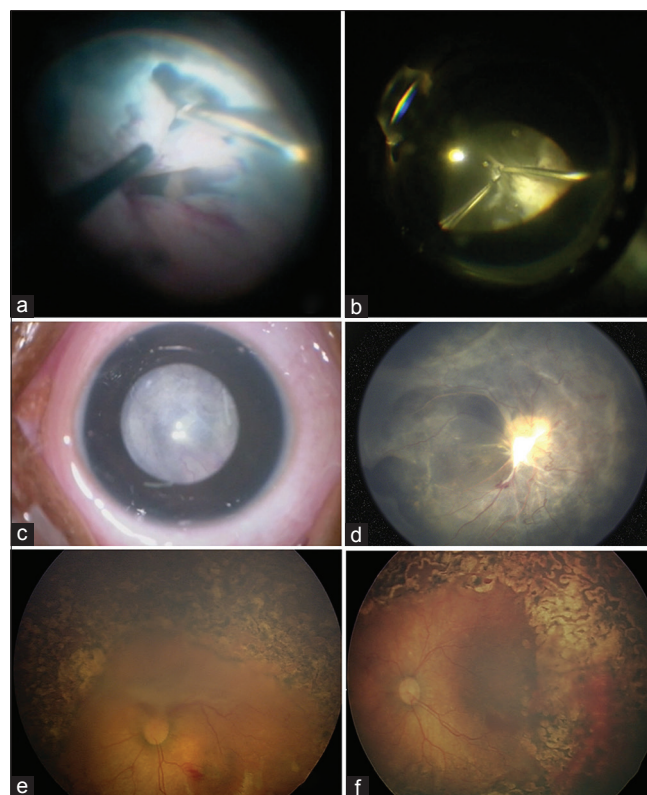


Figure 1: (a) Intraoperative image of microincision vitrectomy surgery for Stage 5 retinopathy of prematurity; opening up of the peripheral trough is seen. (b) Intraoperative image of microincision vitrectomy surgery for "falciform fold" seen in retinopathy of prematurity using a 25 G Chandelier. (c) Stage 5 retinopathy of prematurity with retrolental fibroplasia in a 4 months old child. (d) Postoperative (6 weeks) fundus image of the same child showing well attached retina with trimmed fibrovascular proliferative tissue over disc. (e) Stage 4b retinopathy of prematurity with traction at posterior pole and laser marks from prior treatment. (f) Postoperative fundus image shows well attached retina

fibrous stalk from the optic nerve head (ONH) that held the retina along the central axis. Peripheral trough (formed between peripheral avascular retina and retinal fold from ridge) was then opened up all around by careful dissection using the Microvit and/or curved scissors using Binocular Indirect Ophthalmic Microscope ([OCULUS Optikgeräte GmbH, Germany]) for wide angle view intraoperatively [Fig. 1a].

The sclerotomies were sutured as and when required with 7-0 vicryl (Ethicon US) and the limbal stab incision sutured with 10-0 nylon (Ethicon, USA) making sure the eye is normotensive at closure after careful removal of the AC-maintainer.

The babies were followed up in the initial postoperative period as well as at 1–2 months interval to evaluate the retinal status using indirect ophthalmoscopy. Eyes with minimum of 6 weeks follow-up were included in the analysis.

Statistical analysis was performed with SPSS version 15 (IBM Corporation, Armonk, New York, United States). Categorical data were analyzed using Chi-square test, and continuous data were analyzed using Mann–Whitney U-test and one-way ANOVA. Univariate and multivariate analyses were done by logistic regression for evaluating possible prognostic factors associated with anatomical outcomes.

Results

A total of 202 eyes of 129 premature infants underwent MIVS for TRD secondary to ROP during the study period. Mean gestational age was 29.5 ± 2.8 weeks (range 24–38 weeks). Mean birth weight was 1327 ± 440 g (600–2600 g) and mean age at first presentation was 18.15 ± 12.3 weeks (4–48 weeks). Both eyes underwent surgery in 73 (56%) of 129 children and 52% were male infants [Table 1]. Mean age at presentation in Stage 4 ROP (2.9 ± 1.75 months) was lower than that in Stage 5 (5.62 ± 2.55) ($P < 0.005$). Mean age at the time of surgery was 22.2 ± 11.5 weeks (range 6.1–66 weeks).

Of the eyes which underwent surgery, 117 (58%) were Stage 5, 38 (19%) were Stage 4a, and 47 eyes (23%) were

Stage 4b [Fig. 1e and f]. A total of 94 eyes (47%) had received prior treatment in the form of laser, anti-VEGF or both [Table 2]. As shown in Table 2, a total of 88 eyes undergoing surgery had received prior laser treatment, of these 34 eyes (39%) were Stage 4a, 32 (36%) were Stage 4b, and 22 (25%) were Stage 5. Of the remaining 114 eyes that did not receive prior laser, 4 (3.5%) eyes were Stage 4a, 14 (12.5%) eyes were Stage 4b, and 96 were Stage 5 (84%). This difference was statistically significant ($P < 0.0001$ for comparison between proportion of Stage 4 and 5 eyes in prior laser vs. no prior laser groups, Fisher exact test). Only 6 eyes received anti-VEGF alone as presurgery treatment. However, 20 (53%), 24 (51%), and 13 (11%) eyes had a history of receiving both laser treatment and anti-VEGF in Stage 4a, 4b, and Stage 5 groups, respectively. The corresponding figures for only laser-treated eyes were 14 (37%), 8 (17%), and 9 (8%) in Stage 4a, 4b, and Stage 5, respectively ($P = 0.6$ for comparison of Stage 4 and Stage 5 eyes in combination treatment vs. only prior laser group).

Fifty-three percent of the eyes had no treatment at all before the presentation, and almost 80% of the eyes with Stage 5 ROP had no prior treatment. Plus disease was present in 22 (26%) of the 85 eyes with Stage 4 ROP. A total of 53% of Stage 4a eyes and 59.6% of Stage 4b eyes received intravitreal injection bevacizumab before surgery due to the presence of active vascular disease at the time of surgery.

Preoperative ultrasonography was available in 82 (70%) eyes with Stage 5 ROP. Forty-four (54%) of these eyes showed close-close configuration of retinal detachment (8 [10%] had open-open, 28 [34%] open-close, and 2 [2.5%] close-open).

LSV was performed in 58 (29%) of the eyes while LV had to be performed in 144 (71%) of the eyes [Table 3]. Among LV surgeries, 23, 25, and 27G MIVS systems were used in 73 (50.7%), 69 (47.9%), and 2 (1.4%) eyes, respectively. For LSVs, 23G and 25G systems were used in 23 (40%) and 35 (60%) eyes, respectively. Limbal entry was performed in 56 (47.8%) eyes undergoing LV.

After a mean follow-up of 32.5 weeks (6–156 weeks), a total of 102 (50.5%) eyes achieved anatomical success, which included

Table 1: Demographics and baseline features

Characteristic	n (%)
Normal delivery	72 (56)
Cesarean section	57 (44)
Male	67 (52)
Gestational age, weeks (mean \pm SD, range)	29.5 \pm 2.8, 24-38
Birth weight, g (mean \pm SD, range)	1327 \pm 440.1, 600-2800
Age at presentation, weeks (mean \pm SD, range)	18 \pm 12.3, 4-48
ROP stage	
Stage 4A	38 (19)
Stage 4B	47 (23)
Stage 5	117 (56)
Plus disease	25 (12)
RD configuration on USG	82
Open-open	8 (10)
Open-close	28 (34)
Close-open	2 (2.5)
Close-close	44 (54)

SD: Standard deviation, RD: Retinal detachment, USG: Ultrasonography, ROP: Retinopathy of prematurity

Table 2: Surgical intervention details and prior treatment received

ROP stage	Prior treatment (n=94)			LSV, n (%)	LV, n (%)
	Laser, n (%)	Anti-VEGF, n (%)	Laser + anti-VEGF, n (%)		
Stage 4A (n=38)	14 (37)		20 (53)	30 (79)	8 (21)
Stage 4B (n=47)	8 (17)	4 (8.5)	24 (51)	23 (49)	24 (51)
Stage 5 (n=117)	9 (8)	2 (1.7)	13 (11)	5 (4)	112 (96)
Total (n=202)	31 (15)	6 (3)	57 (28)	58 (29)	144 (71)

LSV: Lens-sparing vitrectomy, LV: Lensectomy with vitrectomy, VEGF: Vascular endothelial growth factor, ROP: Retinopathy of prematurity

Table 3: Anatomical outcomes

Type of surgery	Anatomical success			
	Stage 4A (n=38), n (%)	Stage 4B (n=47), n (%)	Stage 5 (n=117), n (%)	Total (n=202), n (%)
LSV	24/30 (80)	20/23 (87)	2/5 (40)	46/58 (79)
LV	4/8 (50)	15/24 (63)	37/112 (33)	56/144 (39)
Total	28 (74)	35 (74)	39 (33)	102 (50.5)

LSV: Lens-sparing vitrectomy, LV: Lensectomy with vitrectomy

74% eyes in Stage 4a and 4b each and 33% eyes in Stage 5 [Table 3]. The overall outcome of Stage 4 was significantly better than that of Stage 5 ($P = 0.0001$). Comparison between outcomes of LSV and LV revealed better outcome when lens could be spared (LSV) in all stages (Stage 4 [83% vs. 60%], Stage 4a [80% vs. 50%], Stage 4b [87% vs. 63%], and Stage 5 [40% vs. 33%]). Overall success rates for LSV were almost 80% while that of LV were 39%.

Eyes that had prior laser had 3.27 times higher chance of retinal reattachment as compared to eyes without laser ($P < 0.005$); eyes with anti-VEGF injection with or without laser had 2.51 times better chance of anatomical success ($P < 0.005$). Thirty-eight of 57 eyes (67%) in combined pretreatment group versus 19 of 31 eyes (61%) that received only prior laser achieved anatomical success ($P = 0.6$). Eyes which received any prior treatment (laser and/or anti-VEGF) were associated with better anatomical outcome compared to those with no prior treatment (odds ratio [OR] 2.3, 95% confidence interval [CI] (1.3–4.0), $P = 0.003$).

Intraoperative and postoperative complications were recorded. Intraoperative break occurred in a total of 38 (19%) eyes (5 in Stage 4a, 2 in Stage 4b, and 31 in Stage 5). Surgery was continued in 14 of these eyes with additional retinopexy (cryotherapy or endolaser) with or without endotamponade. Silicone oil was used in 7 and C3F8 in 2 eyes. However, SOR at the last follow-up was done only in 1 patient. In other eyes, oil was *in situ* till last follow-up (mean follow-up 48 weeks). Only 8 (21%) of these 38 eyes achieved anatomical success. Of these, 3 eyes were Stage 4, and 5 were stage 5.

Postoperative vitreous hemorrhage was seen in 28% (56 of 202) eyes. It was seen in 34% (33 of 96) eyes operated using 23G MIVS while it was 22% in the 25G group (23 of 104 eyes) ($P = 0.05$). Of the total 63 eyes which received prior anti-VEGF, postoperative vitreous hemorrhage was noted in 16 (25%)

eyes. In the remaining 139 eyes, it was noted in a total of 40 eyes (29%) ($P = 0.7$). Raised intraocular pressure during postoperative period was encountered in 13 (12.7%) of the 102 eyes with attached retina at final follow-up. This included 10 of 56 eyes with retinal reattachment (17.8%) following LV surgery versus 3 of 58 eyes (5.2%) that underwent LSV ($P = 0.04$). Three of these required a glaucoma filtering procedure while the others were managed on topical antiglaucoma medications. Postoperative cataract progression requiring surgical intervention occurred in 2 of the eyes (2.4%) that underwent LSV.

None of the eyes developed endophthalmitis, postsurgery choroidal detachment, or hypotony.

Univariate logistic regression analysis [Table 4] showed that factors that were significantly associated with positive anatomical outcome were Stage 4 disease, prior treatment (laser \pm anti-VEGF), and LSV. Eyes undergoing surgery with 25 G MIVS did better than those with 23 G MIVS (OR: 1.7; CI = 0.98–3.00; $P = 0.05$) On the other hand, a retinal break was significantly associated with poor anatomical outcome (OR 0.21; CI = 0.09–0.5, $P < 0.005$).

Discussion

ROP in India is on the rise. With India being in the third epidemic, the number of eyes needing surgery is also increasing.^[3] The babies in our study were seen to have an average birth weight of 1327 g, with 28% of babies having birth weight of more than 1500 g, and 15% babies having birth weight of more than 1750 g. Among Stage 5 babies 14.5% had birth weight more than 1750 g emphasizing yet again the increased prevalence of the disease in heavier babies in Indian subcontinent as seen by other authors.^[7,8] Fifty-three percent of the eyes had no treatment at all before presentation, and almost 80% of these eyes with no prior treatment had Stage 5 ROP, the severest form of the disease. The lack of proper screening

Table 4: Univariate and multivariate analysis by logistic regression for potential factors associated with anatomical outcomes

Parameters	Univariate analysis				Multivariate analysis			
	OR	95% CI		P	OR	95% CI		P
		Lower	Upper			Lower	Upper	
Age	0.999	0.995	1.002	0.48				
Gestational age	1.01	0.92	1.12	0.77				
Birth weight	1.001	1	1.001	0.16				
Stage 4A*	5.79	2.58	13.82	<0.005	5.04	1.81	14.04	0.002
Stage 4B*	3.71	1.82	7.54	<0.005	5	1.9	12.9	0.001
Plus	1.57	0.67	3.68	0.3				
Prior laser	3.27	1.81	1.75	<0.005	1.786	0.512	6.2	0.363
Prior anti-VEGF	2.51	1.36	4.65	<0.005	1.243	0.49	3.16	0.647
LSV	6.99	3.35	14.61	<0.005	0.739	0.364	1.5	0.403
Chandelier system/irrigating endoillumination	1.33	0.66	2.64	0.42				
Vitreous hemorrhage	0.65	0.35	1.22	0.19				
25G**	1.72	0.98	3.00	0.05				
Break	0.21	0.09	0.50	<0.005	0.281	0.113	0.695	0.006
USG configuration of RD***	0.54	0.18	1.62	0.27				

*Compared to Stage 5, **Compared to 23G, ***Open funnel versus closed funnel configuration in Stage 5 ROP. CI: Confidence interval, LSV: Lens-sparing vitrectomy, RD: Retinal detachment, USG: Ultrasonography, ROP: Retinopathy of prematurity, OR: Odds ratio, VEGF: Vascular endothelial growth factor

and timely treatment leading to Stage 5 disease has also been seen by Sanghi *et al.*^[9]

The margin of error is extremely low, due to the peculiar vitreoretinal pathoanatomy of detachments associated with ROP. The outcomes for Stage 4 and Stage 5 ROP after vitrectomy with 20 G have been between 62%–92% and 13%–42%, respectively.^[10–14] With 25-gauge vitrectomy, the outcomes reported are 81%–100% for Stage 4.^[15–17] There are not many reports for MIVS in Stage 5 ROP especially for those presenting with RLF. In the present study, we present our experience with MIVS in both Stage 4 and 5 ROP.

Smaller gauge of instruments allows easy access is allowing better and safer removal of fibrovascular tissue in these small eyes. The higher cut rate, smaller internal diameter, and low controlled vacuum of dual pneumatic cutters allow superior cutting efficiency and increased cut rate, without affecting flow and duty cycle (amount of time during the cutting cycle that the port is open).^[6] Hence, flow through cutter can be maintained at higher cut rates with less traction when working close to retina.^[6] Furthermore, the presence of the cutter port close to the cutter tip in MIVS reduces likelihood of inadvertent increased vitreoretinal traction and retinal break formation intraoperatively. We were able to complete the surgery in 81% eyes without retinal break formation.

Twenty-five Gauge chandelier system with powerful light sources like LED also allows 4-port vitrectomy which makes bimanual surgery possible throughout the procedure, allowing access to the tough preretinal membranes. Four-port PPV was done in 20% eyes in our study. MIVS also allows use of combination instruments; for example, in nearly 20% of eyes in our series, infusion cannula with endoilluminator was used, again facilitating bimanual surgery. Anatomical outcome with 23/25 G MIVS [Table 4] was similar to the anatomical outcome with 20 G LSV as reported earlier from our center.^[14] However, the results for Stage 5 were significantly improved. The use of wide angle viewing system along with a smaller gauge of microvit or curved scissors immensely improved the ability of the surgeon to visualize and access the “peripheral trough” allowing complete opening up of the RD so as to achieve a better result. A previous report from our center reported the successful anatomic outcome in up to 23% of eyes with Stage 5 ROP as compared to 33% seen in the present study with MIVS.^[10] Furthermore, smaller gauge of instruments permits entry through the limbus for LV, thereby reducing the risk of dialysis which can occur during entry from pars plicata sclerotomies in advanced Stage 5 ROP with RLF. In our study, limbal entry was made in 48% of eyes. Limbal entry with the use of iris hooks and use of wide angle viewing devices also obviated the need to cut or disinsert the iris as was described by previous surgeons in Stage 5 surgeries.^[10,18] This considerably reduces the surgical trauma.

Although earlier reports of LSV described in literature are 2-port vitrectomies,^[19] increasingly 3-port vitrectomy is being preferred by various surgeons.^[20] This ensures continuous flow of infusion and allows surgeon to switch hands without risk of transient hypotony. Because of the smaller gauge of instruments used in MIVS, 3-port vitrectomy is almost always possible. Elevation of IOP during surgery is also very prompt and effective with improved fluidic system in MIVS. This is particularly useful to prevent intraoperative bleed during

surgery in extremely vascular eyes. Postoperative vitreous hemorrhage was seen in 28% of eyes in our study (34% in 23G vs. 22% in 25G; $P=0.05$). Choi *et al.* in their series of Stage 4 and 5 ROP with 20 G reported postoperative intraocular hemorrhage in nearly 43% of cases.^[11] Lens opacities after LSV have been documented in 5%–37% of eyes with increasing incidence after prolonged follow-up.^[21,22] In our case series, it was 2.4% though our follow-up was less.

Nearly, 72% (147/202) of the eyes needed suturing after MIVS; 90.6% in 23G and 55.2% in 25G surgeries needed suturing ($P<0.01$). Sclerotomy closure was definitely necessary when MVR was used to make sclerotomies without the use of the cannula. There was no statistically significant difference in the incidence of postoperative IOP rise between the two systems (23G [12.5%] vs. 25G [8%], $P=0.3$).

This modification of technique with suturing of the sclerotomies as well as conjunctiva for infants undergoing pars plicata MIVS has also been described by Gonzales *et al.*^[23] It is often necessary because of the low scleral rigidity in pediatric eyes because of which self-sealing effect of the MIVS may not always be successful. Furthermore, even a minimal transient hypotony in these eyes may result in bleeding from the vascular ridge. We also found that partial fluid air exchange at the end of surgery as was advocated earlier at the end of LSV is also not necessary since with the reduced size of sclerotomies vitreous prolapse is minimal. This along with sutureless sclerotomies in some cases can reduce surgery time as well.

MIVS in these young infants also has many associated challenges/difficulties requiring special consideration. Due to the small interpapillary fissure, sclerotomies need to be placed closer to the horizontal meridian, to allow more room for manipulation of instruments. At times these instruments may need to be used without the trocars to create space for manipulation and rotation of the globe without hindering or distorting the surgeon's view. Furthermore, sclera in these children is too thin to support the weight of cannula, which has a tendency to rotate/torque easily possibly causing a lens touch or suprachoroidal/subretinal infusion. Hence, it must be secured by use of a sterile adhesive tape. The length of the present MIVS instruments is long (32 mm); inadvertent injury to the pulled up or folded retina may happen with the sharp tip while inserting the trocar. A sudden jerky movement while inserting the trocar assembly may also increase the risk of injury to retina. This can be minimized by use of MVR to make sclerotomies. Future use of short pediatric 25+ instruments with smaller shaft size has been made to address this issue.^[6] In the early period of the study, 25G instruments did show some malleability issues, but over time the instrument rigidity and designs have significantly improved.^[6] We had more surgeries with 23 G in the early time period and more with 25 G later. This is also the reason because of which in this time period hardly any 27G instruments have been used.

Table 5 summarizes other recent studies reporting surgical outcomes in ROP.^[10–17,24–27] In the 20G era, the reported outcome for Stage 4 ROP ranges from 60% to 90%, decreasing to 13%–40% for Stage 5 disease. Reattachment rates, similar to our series after LSV, were reported to be 82.1% for Stage 4a, 69.5% for Stage 4b, and 42.6% for Stage 5 in a large case series by Nudleman *et al.*^[26] Phenotypes of ROP may differ in different parts of the world due to differences in resources available for

Table 5: Literature review

Study	Number of eyes	Gauge	Successful anatomical outcome		Complications			
			Stage 4	Stage 5	Cataract	Glaucoma	Vitreous hemorrhage	Others
Gopal L <i>et al.</i> , 2000	96	20	-	22.5%	NA	10%		Intra-operative retinal dialysis 14.6% Posterior retinal break 3.1%
Hartnett <i>et al.</i> , 2004	11	20	72%	-	-	-	-	
Cusick <i>et al.</i> , 2006	608	20	-	33%	-	-	-	
Choi <i>et al.</i> , 2011	21	20	4b 62%	13%	19%	33%	43%	
Capone <i>et al.</i> , 2001	40	20	4a 90%	-	-	5%	-	
Hubbard <i>et al.</i> , 2004	37	20	4a 84% 4b 92%	-	Nil	8%	-	
Capone <i>et al.</i> , 2015	496	20	82% 69%	42%	5.9%	-	-	
Bhende <i>et al.</i> , 2009	39	20	74%	-	13%	-	33%	
Kychenthal <i>et al.</i> , 2008	13	25	4a 92%	-				Choroidal detachment 7.7%
Gonzales <i>et al.</i> , 2006	15	25	4a 81% 4b 100%	-	6.6%		13.3%	
Shah <i>et al.</i> , 2015	20	25	4a 100% 4b 89%	-				
Gadkari <i>et al.</i> , 2015	31	23	4b 90%	45.4%				
Current study	202	23/25	4a 74% 4b 74%	33%	10.3%	2.4%	16%	

NA: Not available

prenatal care as well as oxygen regulation, and hence, statistical comparisons may not always be justified.^[28]

In our study, Stage 4 was seen in patients who had progressive disease in spite of previous treatment in most of the cases. Plus disease was seen in 52% of Stage 4a and 25.5% of Stage 4b; also large number of eyes with Stage 4a and 4b received prior anti-VEGF treatment because of active disease at the time of surgery (51% and 59.5% for 4a and 4b, respectively). Presence of plus disease and active neovascularization at the time of surgery are known poor prognostic factors for successful reattachment of the retina.^[29] In our study, 15 of the 22 eyes (68%) with Stage 4 plus disease achieved anatomical success vis-a-vis 48 of 63 eyes (76%) without plus disease ($P = 0.6$). There was also no significant difference in the incidence of intra/postoperative hemorrhage among the 2 groups (seen in 8 out 22 eyes [36%] with plus disease vs. 26 of 63 eyes [41%] with no plus disease, $P = 0.8$). This could be a drawback of retrospective analysis (selection bias/confounding). Cases with plus disease were also more likely to receive prior anti-VEGF injections and laser treatment which are independent factors influencing anatomical outcome in our study.

Stage 5 disease was largely cicatricial with a history of preoperative anti-VEGF in only 12.8% eyes. The need to perform lensectomy-vitreotomy as seen in our study has also been reported to be associated with poor surgical outcome.^[30] This could be expected since lensectomy was in general performed in eyes with more advanced and/or anteriorly located pathology. Stage 5 ROP had significantly worse

anatomical outcomes compared to Stage 4 cases and expectedly so.^[10,11,27] We also divided the babies who underwent surgery for Stage 5 into 3 age groups: <3 months of age, 3–9 months, and >9 months of age and found that proportion of eyes with stage 5 ROP achieving anatomical success postsurgery was two times higher in the 3–9 months (28/83; 34%) age group as compared to <3 months (3/20; 15%) group ($P = 0.05$). However, Stage 4 eyes did not reveal a difference in outcome among different age groups (40/48 [71%] in <3 months group and 23/28 (82%) in 3–9 months group; $P = 0.9$). This signifies that children reaching Stage 5 very early on had very severe disease to start with and the outcome was poorer in these eyes. Severe disease in these eyes may have caused early onset of Stage 5 disease which even if operated early had a poor prognosis.

Prior treatment with laser or anti-VEGF or both showed significant association with good anatomical outcome on univariate analysis but was not significant on multivariate logistic regression analysis [Table 5]. This can be explained by the fact that significantly higher proportion of Stage 4a (90%) and 4b (77%) eyes had received prior treatment compared to Stage 5 (20%) eyes [Table 3] which was an independent factor influencing surgical outcome.

This is one of the largest series reporting surgical outcomes for advanced ROP with MIVS in the Indian population. Retrospective design, limited long-term follow-up are limitations of our study. Furthermore, experience with 27 G MIVS is limited because of non-availability of all the instruments at the time of this study.

Conclusion

Advanced ROP needing surgery is here to stay, and MIVS along with wide angle viewing systems and dual use instruments has increased options available to surgeons to manage these complex surgeries. Smaller gauge is better, especially for smaller eyes. Almost all cases can be done with it. It improved our Stage 5 RD reattachment rates and reduced the complication of cataract and vitreous hemorrhage for Stage 4 ROP as compared to previous studies with 20 G. Still many more innovations and modifications need to be made to make MIVS more suitable for these small eyes. Still many more innovations and modifications need to be made to make MIVS more suitable for these small eyes. Instrumentation however, may not be the only factor governing the outcome of the disease and challenges remain. Better screening strategies allowing timely treatment to prevent these advanced stages of ROP is the best way forward.

Financial support and sponsorship

Nil.

Conflicts of interest

There are no conflicts of interest.

References

- Multicenter trial of cryotherapy for retinopathy of prematurity. Preliminary results. Cryotherapy for Retinopathy of Prematurity Cooperative Group. Arch Ophthalmol 1988;106:471-9.
- Good WV; Early Treatment for Retinopathy of Prematurity Cooperative Group. Final results of the early treatment for retinopathy of prematurity (ETROP) randomized trial. Trans Am Ophthalmol Soc 2004;102:233-48.
- Gilbert C. Retinopathy of prematurity: A global perspective of the epidemics, population of babies at risk and implications for control. Early Hum Dev 2008;84:77-82.
- Kuprjanowicz L, Kubasik-Kładna K, Modrzejewska M. Outcomes of surgical management of retinopathy of prematurity – An overview. Klin Oczna 2014;116:138-41.
- Hartnett ME. Studies on the pathogenesis of avascular retina and neovascularization into the vitreous in peripheral severe retinopathy of prematurity (an American Ophthalmological Society Thesis). Trans Am Ophthalmol Soc 2010;108:96-119.
- Mohamed S, Claes C, Tsang CW. Review of small gauge vitrectomy: Progress and innovations. J Ophthalmol 2017;2017:6285869.
- Shah PK, Narendran V, Kalpana N, Gilbert C. Severe retinopathy of prematurity in big babies in India: History repeating itself? Indian J Pediatr 2009;76:801-4.
- Patwardhan SD, Azad R, Gogia V, Chandra P, Gupta S. Prevailing clinical practices regarding screening for retinopathy of prematurity among pediatricians in India: A pilot survey. Indian J Ophthalmol 2011;59:427-30.
- Sanghi G, Dogra MR, Katoch D, Gupta A. Demographic profile of infants with stage 5 retinopathy of prematurity in North India: Implications for screening. Ophthalmic Epidemiol 2011;18:72-4.
- Gopal L, Sharma T, Shanmugam M, Badrinath SS, Sharma A, Agraharam SG, et al. Surgery for stage 5 retinopathy of prematurity: The learning curve and evolving technique. Indian J Ophthalmol 2000;48:101-6.
- Choi J, Kim JH, Kim SJ, Yu YS. Long-term results of lens-sparing vitrectomy for stages 4B and 5 retinopathy of prematurity. Korean J Ophthalmol 2011;25:305-10.
- Capone A Jr., Trese MT. Lens-sparing vitreous surgery for tractional stage 4A retinopathy of prematurity retinal detachments. Ophthalmology 2001;108:2068-70.
- Hubbard GB 3rd, Cherwick DH, Burian G. Lens-sparing vitrectomy for stage 4 retinopathy of prematurity. Ophthalmology 2004;111:2274-7.
- Bhende P, Gopal L, Sharma T, Verma A, Biswas RK. Functional and anatomical outcomes after primary lens-sparing pars plana vitrectomy for stage 4 retinopathy of prematurity. Indian J Ophthalmol 2009;57:267-71.
- Kychenthal A, Dorta P. 25-gauge lens-sparing vitrectomy for stage 4A retinopathy of prematurity. Retina 2008;28:S65-8.
- Gonzales CR, Boshra J, Schwartz SD. 25-gauge pars plicata vitrectomy for stage 4 and 5 retinopathy of prematurity. Retina 2006;26:S42-6.
- Shah PK, Narendran V, Kalpana N. Safety and efficacy of simultaneous bilateral 25-gauge lens-sparing vitrectomy for vascularly active stage 4 retinopathy of prematurity. Eye (Lond) 2015;29:1046-50.
- Shah PK, Narendran V, Kalpana N, Tawansy KA. Anatomical and visual outcome of stages 4 and 5 retinopathy of prematurity. Eye (Lond) 2009;23:176-80.
- Maguire AM, Trese MT. Lens-sparing vitreoretinal surgery in infants. Arch Ophthalmol 1992;110:284-6.
- Lakhanpal RR, Sun RL, Albini TA, Holz ER. Anatomic success rate after 3-port lens-sparing vitrectomy in stage 4A or 4B retinopathy of prematurity. Ophthalmology 2005;112:1569-73.
- Ferrone PJ, Harrison C, Trese MT. Lens clarity after lens-sparing vitrectomy in a pediatric population. Ophthalmology 1997;104:273-8.
- Lakhanpal RR, Davis GH, Sun RL, Albini TA, Holz ER. Lens clarity after 3-port lens-sparing vitrectomy in stage 4A and 4B retinal detachments secondary to retinopathy of prematurity. Arch Ophthalmol 2006;124:20-3.
- Gonzales CR, Singh S, Schwartz SD. 25-gauge vitrectomy for paediatric vitreoretinal conditions. Br J Ophthalmol 2009;93:787-90.
- Hartnett ME, Maguluri S, Thompson HW, McColm JR. Comparison of retinal outcomes after scleral buckle or lens-sparing vitrectomy for stage 4 retinopathy of prematurity. Retina 2004;24:753-7.
- Cusick M, Charles MK, Agrón E, Sangiovanni JP, Ferris FL 3rd, Charles S, et al. Anatomical and visual results of vitreoretinal surgery for stage 5 retinopathy of prematurity. Retina 2006;26:729-35.
- Nudleman E, Robinson J, Rao P, Drenser KA, Capone A, Trese MT, et al. Long-term outcomes on lens clarity after lens-sparing vitrectomy for retinopathy of prematurity. Ophthalmology 2015;122:755-9.
- Gadkari S, Kamdar R, Kulkarni S, Kakade N, Taras S, Deshpande M, et al. Vitreoretinal surgery for advanced retinopathy of prematurity: Presentation and outcomes from a developing country. Can J Ophthalmol 2015;50:54-60.
- Hartnett ME. Pathophysiology and mechanisms of severe retinopathy of prematurity. Ophthalmology 2015;122:200-10.
- Lakhanpal RR, Fortun JA, Chan-Kai B, Holz ER. Lensectomy and vitrectomy with and without intravitreal triamcinolone acetonide for vascularly active stage 5 retinal detachments in retinopathy of prematurity. Retina 2006;26:736-40.
- Hartnett ME. Features associated with surgical outcome in patients with stages 4 and 5 retinopathy of prematurity. Retina 2003;23:322-9.