E-ISSN:2454-9894 P-ISSN: 2454-9886

International Archives of
BioMedical and Clinical Research
(An Official Publication of "Ibn Sina Academy of Medieval Medicine & Sciences")
WWW.IABCR.ORG

Section General Surgery

Case Report

Placental Site Trophoblastic Tumour – A Rare Cause of Uncontrollable Post- Operative Hemorrhage in Obstetric Cases

Bushra Siddiqui[1], Dipanjan Sinha[2], Shahbaz Habib Faridi[3], Mohd. Feroz Alam[1]

[1]Assistant Professor; [2]Junior Resident, Department of Pathology; [3]Assistant Professor Department of Surgery, JN Medical College, Aligarh Muslim University, Aligarh, Uttar Pradesh, India.

ABSTRACT

Placental site trophoblastic tumour (PSTT) is a rare variant of gestational trophoblastic disease developing from intermediate trophoblasts. PSTTs are incredibly rare tumours with 1 in 100000 pregnancies and only about 200 cases reported till date with mortality reaching up to 25% in undiagnosed cases. We present the case of a 37year old female, gravida 4 para 3, presenting with uncontrollable post caesarean haemorrhage for which she underwent subtotal hysterectomy. Histopathological examination revealed Placental site trophoblastic tumour. Placental site trophoblastic tumour, being a rare entity, pose difficulties in its early diagnosis. Delayed diagnosis can lead to distant metastases, thus worsening the prognosis.

Keywords: *Post- Operative Hemorrhage, Trophoblastic Tumour*

Article History
Received: 01.06.2022
Accepted: 25.07.2022

***Corresponding Author**

Dr. Shahbaz Habib Faridi,
Department of Surgery, JN Medical College, AMU, Aligarh, Uttar Pradesh, India
Email: drshahbazfaridi@gmail.com

INTRODUCTION

Placental site trophoblastic tumor (PSTT) is a rare type of gestational trophoblastic disease that develops from intermediate trophoblasts (ITs). PSTT was first described in 1976 by Kurman as syncytial endometritis, designated as trophoblastic pseudotumor.[1] However, in 1981, Scully recognized its neoplastic nature, naming it as PSTT.[2] It was formally acknowledged by world health organization in 1986 and adopted the terminology of PSTT.[3] It is considered to be commonly occurring in women having history of miscarriage, termination of pregnancy, or even normal or pathological ongoing pregnancy. It constitutes 1-2% of all gestational trophoblastic neoplasia, about 1 in 100000 pregnancies with only about 200 reported till date. Mortality in undiagnosed cases reaches about 25%. Due to its rare occurrence and uncharacteristic clinical features, diagnosis and management of PSTT is quite challenging in nature.[4]

METHODS

A 37year old female presented to Antenatal Clinic for a planned Caesarean section. Routine antenatal ultrasound had revealed 'central placental previa'. She had a history of two live births followed by a spontaneous abortion. The menstrual history was also normal and there was no history of taking any contraceptives or insertion of intrauterine device. The patient was normotensive and non-diabetic. Physical examination of the various systems were within normal limits.

Caesarean section was uneventful and patient was shifted out of the operation theatre for observation where she had uncontrollable hemorrhage in the immediate post-operative period. As all the conservative methods of hemostasis failed. The patient was immediately transferred to the operation theatre where a a subtotal hysterectomy was done. Specimen was sent for histopathological examination.

Access this article online	
Website: www.iabcr.org	Quick Response code
DOI: 10.21276/iabcr.2022.8.3.4	

How to cite this article: Siddiqui B., Sinha D, Faridi SH, Alam MF. Placental Site Trophoblastic Tumour – A Rare Cause of Uncontrollable Post- Operative Hemorrhage in Obstetric Cases. Int Arch BioMed Clin Res. 2022;8(3):CR1–CR3.

Source of Support: Nil, **Conflict of Interest:** None

Grossly, the specimen measured (14x13x6.5) cms. Endometrium with myometrium measured 2.5cm. A perforation was seen on the anterior surface measuring 3 cm in diameter. On examining the specimen, no adnexal structures were identified. On serial cut sectioning, whitish areas along with hemorrhagic areas were identified. The specimen was photographed and relevant representative sections were taken (Fig.1 and 2)

Microscopically, Hematoxylin & Eosin stained sections showed sheets, small nests and singly dispersed intermediate trophoblastic cells invading the myometrium. The cells were large, polyhedral to round with eosinophilic to clear cytoplasm, pleomorphic nuclei with coarsely clumped chromatin and prominent nucleoli. Multinucleated cells were also seen, 1-2 mitosis/ 10 high power field were appreciated. Focal vascular invasion was appreciated. Surrounding areas showed sheets of decidualized cells along with necrosis and congested blood vessels. The findings were suggestive of Placental Site Trophoblastic Tumor. (Fig.3 and Fig.4)

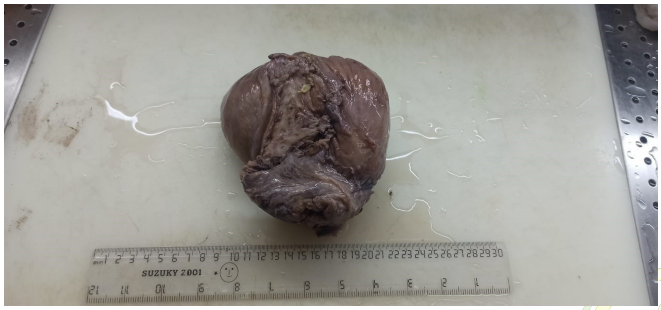

Fig.1: Gross specimen of Subtotal Hysterectomy with anterior perforation.

Fig.2: Cut Section showing whitish areas with areas of Hemorrhage.

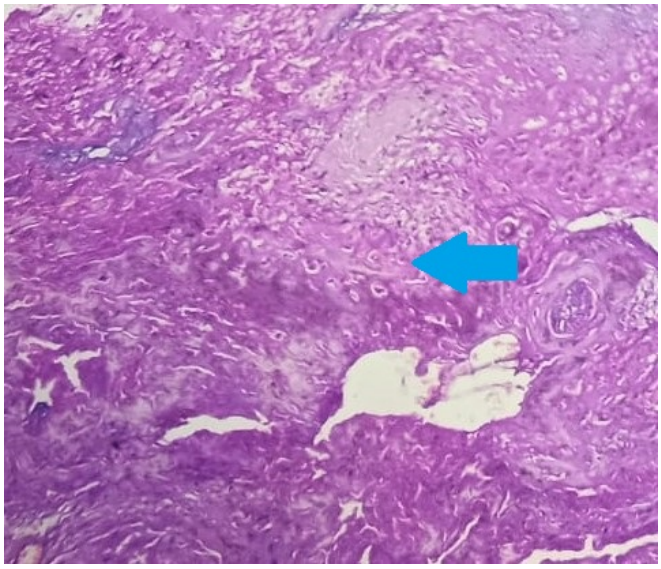

Fig.3: H&E X 100 – Section showing sheets, small nests and singly dispersed intermediate trophoblastic cells invading the myometrium. (Marked with Solid Blue Arrow)

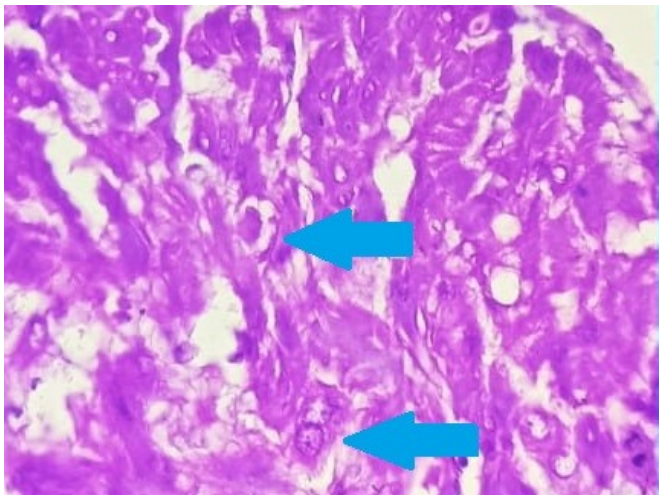

Fig.4: H&E X 400 – Section showing large, polyhedral to round cells with eosinophilic to clear cytoplasm, pleomorphic nuclei with coarsely clumped chromatin and prominent nucleoli (Marked with Solid Blue Arrows)

DISCUSSION

Gestational trophoblastic disease (GTD) is a group of related lesions due to abnormal proliferation of trophoblastic tissue. As an entity it comprises of: hydatidiform mole (partial and complete), invasive mole, choriocarcinoma, epithelioid trophoblastic tumor and placental site trophoblastic tumor, with last four being termed as gestational trophoblastic neoplasia (GTN).[5,6]

Placental site trophoblastic tumor (PSTT) is a rare type of GTN which arises from placental implantation site. Though PSTT has benign clinical course, it can metastasize and even relapse showing malignant behavior.

In normal pregnancies, trophoblasts differentiate from the fertilized ovum forming the outer layer of blastocysts. Placental trophoblastic cells comprise of cytotrophoblasts, syncytiotrophoblasts and intermediate trophoblasts. The basal layer is formed by cytotrophoblast, the syncytiotrophoblast produce human chorionic gonadotrophin hormone and invade endometrial stroma. The intermediate trophoblasts migrate from placenta to remodel spiral arterioles to lower resistance to blood flow towards placenta [(4)]. PSTT arises from neoplastic proliferation of intermediate trophoblastic cells. Most of the times it occurs after a normal pregnancy, however some cases can occur after miscarriage, an abortion or a molar pregnancy. It is suggested that a paternal X chromosome and an absence of Y chromosome may be necessary for development of PSTT.[7,8]

PSTT can manifest months or even years after pregnancy. It shows varied clinical presentation like vaginal bleeding, amenorrhea, abdominal mass or even as postmenopausal bleeding in certain cases.[9] Unusual symptoms like nephrotic syndrome and virilization may be encountered.[10] PSTT can metastasize to lungs and vagina. It shows higher preponderance to lymphatic metastasis.[11]

Grossly, it presents as a well localized or ill-defined myometrial mass. It may be associated with hemorrhage. It is usually associated with deep uterine penetration, and even perforation.[12]

Microscopically, PSTT is characterized by large trophoblastic cells having abundant eosinophilic cytoplasm and nuclear pleomorphism with myometrial and vascular invasion.[13]

Immunohistochemically, PSTT has a strong reactivity for HPL and a weaker, focal reactivity for Human Chorionic Gonadotropin. It is also positive for cytokeratin, CD146 (Mel-CAM), HLA-G, inhibin, CD66a (CEACAM1) and Pregnancy associated major basic protein.[12] There is associated raised level of Ki67, which is, however, lower than choriocarcinoma.[13]

PSTT has more nuclear pleomorphism, vascular invasion and an infiltrative pattern of growth as compared to epithelioid trophoblastic tumor [(13)]. Lack of expression of p63 acts as a differentiating factor from epithelioid tumor.[14] Lack of dimorphic population of cytotrophoblast and syncytiotrophoblasts, lack of hemorrhage and muscle invasion of interdigitating pattern distinguishes PSTT from choriocarcinoma.[15]

Surgery is the main modality of treatment for PSTT, as it is relatively resistant to chemotherapy. However, patients with metastatic diseases or high mitotic rate should be subjected to multi agent adjuvant chemotherapy.[16]

CONCLUSION

PSTT is an extremely rare type of gestational trophoblastic neoplasia. It is a rarely documented entity. It shows a wide range of symptoms which may present months and years after pregnancy. Being a rare variety of GTN, difficulties regarding its early diagnosis are often encountered. Delayed diagnosis can lead to distant metastases, thus worsening the prognosis.

What this study adds:

1. What is known about this subject?
   Placental site trophoblastic tumour (PSTT) is a rare variant of gestational trophoblastic disease developing from intermediate trophoblasts. PSTTs are incredibly rare tumours with 1 in 100000 pregnancies

2. What new information is offered in this study?
   PSTT can be a rare but fatal cause of postoperative cases in obstetrics. If not diagnosed and managed timely mortality reaches about 25%. Due to its rare occurrence and uncharacteristic clinical features, diagnosis and management of PSTT is quite challenging in nature.

Patient Consent: Informed and written consent was taken from the patient for publication of manuscript and photographs.

Ethical approval: Not required.

REFERENCES

1. Kurman RJ, Scully RE, Norris HJ. Trophoblastic pseudotumor of the uterus: an exaggerated form of "syncytial endometritis" simulating a malignant tumor. Cancer. 1976;38(3):1214-26.
2. Scully RE & Young RH. Trophoblastic pseudotumor: a reappraisal. Am J Surg Pathol. 1981;5(1):75-6.
3. Zeng X, Liu X, Tian Q, Xue Y, An R. Placental site trophoblastic tumor: A case report and literature review. Intractable Rare Dis Res. 2015;4(3):147-151.
4. Bouquet de la Jolinière J, Khomsi F, Fadhlaoui A, Ben Ali N, Dubuisson JB, Feki A. Placental site trophoblastic tumor: a case report and review of the literature. Front Surg. 2014;1:31.
5. Kaur B. Pathology of gestational trophoblastic disease (GTD). Best Pract Res Clin Obstet Gynaecol. 2021;74:3-28.
6. Valzacchi GM, Odetto D, Chacon CB, Wernicke A, Xiang Y. Placental site trophoblastic disease. Int J Gynecol Cancer. 2020;30(1):144-9.
7. Hui P, Wang HL, Chu P, Yang B, Huang J, Baergen RN, et al. Absence of Y chromosome in human placental site trophoblastic tumor. Mod Pathol. 2007;20(10):1055-60.
8. Hui P, Parkash V, Perkins AS, Carcangiu ML. Pathogenesis of placental site trophoblastic tumor may require the presence of a paternally derived X chromosome. Lab Invest. 2000;80(6):965-72.
9. Lee HJ, Shin W, Jang YJ, Choi CH, Lee JW, Bae DS, et al. Clinical characteristics and outcomes of placental site trophoblastic tumor: experience of single institution in Korea. Obstet Gynecol Sci. 2018;61(3):319-27
10. Young, R., Scully, R., Mccluskey, R.A. Distinctive Glomerular Lesion Complicating Placental Site Trophoblastic Tumour: Report of Two Cases. Hum.Pathol. 1985;16:35-42.
11. Lan C, Li Y, He J, Liu J. Placental site trophoblastic tumor: lymphatic spread and possible target markers. Gynecol Oncol.2010;116:430–7.
12. Shih IM & Kurman RJ. p63 expression is useful in the distinction of epithelioid trophoblastic and placental site trophoblastic tumors by profiling trophoblastic subpopulations. Am J Surg Pathol. 2004;28(9):1177-83.
13. Shih IM & Kurman RJ. Ki-67 labeling index in the differential diagnosis of exaggerated placental site, placental site trophoblastic tumor, and choriocarcinoma: a double immunohistochemical staining technique using Ki-67 and Mel-CAM antibodies. Hum Pathol. 1998;29(1):27-33.
14. Shih IM & Kurman RJ. Epithelioid trophoblastic tumor: a neoplasm distinct from choriocarcinoma and placental site trophoblastic tumor simulating carcinoma. Am J Surg Pathol. 1998;22(11):1393-403.
15. Gari, A. Placental site trophoblastic tumor and choriocarcinoma: an unusual presentation. BMC Res Notes. 2015;8(1):1-4.
16. Alexander AL, Strohl AE, Maniar KP, Lurain JR. Placental site trophoblastic tumor: successful treatment of 13 cases. Gynecol Oncol Rep. 2020;32:100548.