

Unusual Presentation of Bronchogenic Carcinoma

Sir,

Bronchogenic carcinoma presents commonly with symptoms like cough, dyspnoea or hemoptysis. While bone metastases from bronchogenic carcinoma is a familiar problem, their significance as the first tumor manifestation, has been underestimated.¹

A 40 years non smoker female patient came with history of painful bony swellings over skull and mandible since 1

month and history of diplopia since 15 days. There were no complaints of cough, breathlessness, fever, vomiting or hemoptysis. On examination, she was afebrile, pulse was 86/min, blood pressure of 130/80 mm Hg, respiratory rate of 18/min and an arterial oxygen saturation of 98%. She had pallor, but no icterus, cyanosis, clubbing or significant lymphadenopathy. Multiple tender bony swellings measuring 1 - 2 cm were present over frontal, parietal, temporal bone and over angle of mandible. No other bony tenderness was found. Her respiratory system examination,

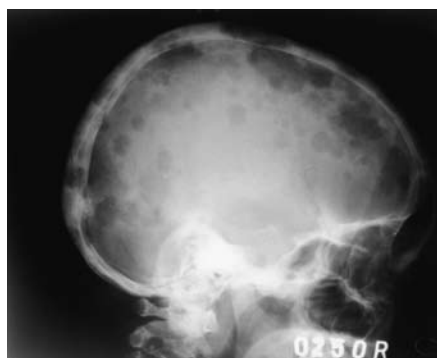

Fig. 1 : X-ray Skull showing multiple lytic lesions

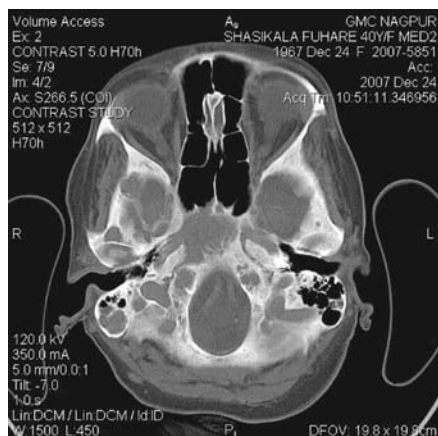

Fig. 2 : CT Head showing destruction of base of skull

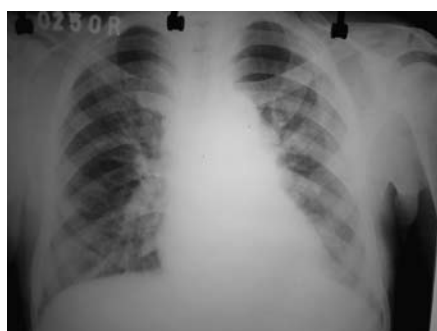


Fig. 3 : Chest X-ray PA view showing left hilar enlargement

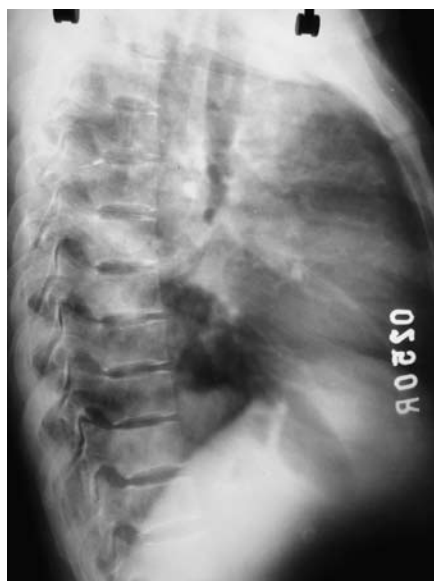

Fig. 4 : Chest X-ray left lateral view showing increased opacity in posterobasal segment of lung

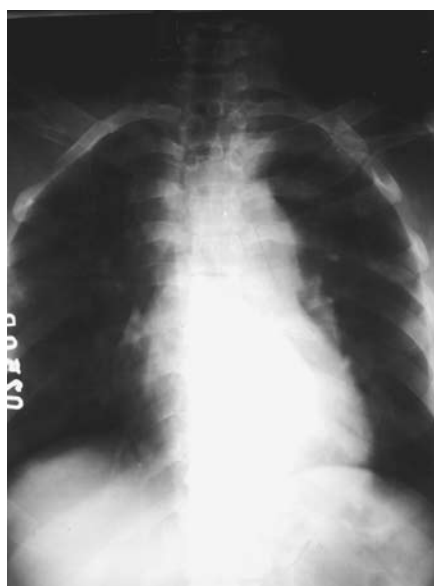

Fig. 5 : Chest X-ray AP view showing retrocardiac shadow

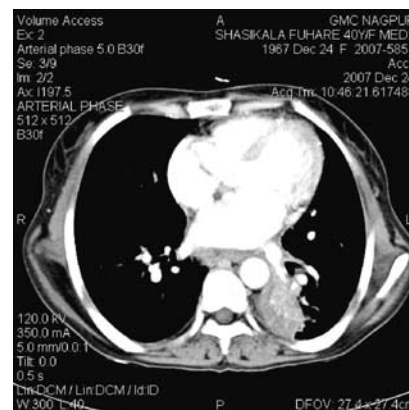

Fig. 6 : CT Thorax showing moderately enhancing heterogenous mass in the superior and posterior basal segment of left lower lobe of lung

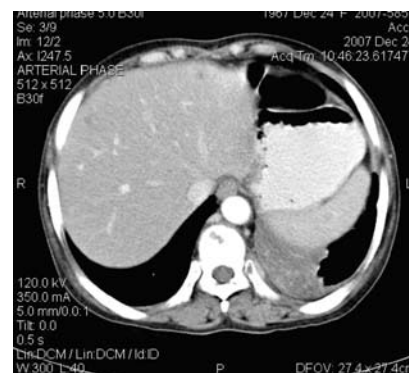

Fig. 7 : CT Abdomen showing multiple metastasis in liver and body of vertebra

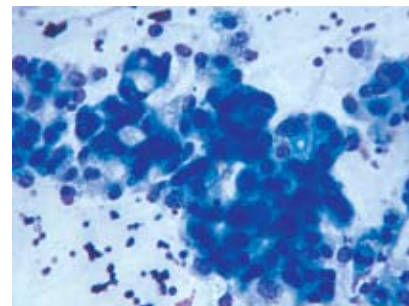


Fig. 8 : FNAC from lung mass suggestive of adenocarcinoma

cardiovascular and abdominal system examinations were within normal limits. She had right side lateral rectus palsy but rest of her neurological examination was normal. There was no lump in breast.

Laboratory reports: hemoglobin of 6.1 gm%, peripheral smear showed normocytic normochromic red blood cells, white blood cell count of 6000/mm³ (Differential count : within normal limits), kidney function and liver function test along with serum electrolytes were within normal limits. X-ray skull was suggestive of multiple lytic lesions (Fig. 1) and computed tomography of head showed multiple lytic lesion involving skull vault, with destructive lesion involving clivus & basis sphenoid - ? Multiple myeloma (Fig. 2). Cerebrospinal fluid analysis was within normal limits. Bone marrow aspiration was suggestive of few atypical cells – epithelial malignancy (adenocarcinoma). Her X-rays chest (Posteroanterior, left lateral and Anteroposterior view, Figs. 3, 4, and 5 respectively) were done. PA view showed hilar enlargement and in AP view a retrocardiac mass shadow was seen. Computed tomography of her chest (Fig. 6) and abdomen (Fig. 7) was suggestive of i) well defined lobulated moderately heterogeneously enhancing soft tissue density mass lesion in left parahilar, apical and posteriorbasal segment of left lower lobe with mediastinal lymphadenopathy ii) Multiple lytic destructive lesions in bony skeleton and iii) Multiple hepatic metastases. CT guided FNAC from lung mass was suggestive of adenocarcinoma (Fig. 8).

A diagnosis of adenocarcinoma of lung with multiple bony and hepatic metastases including bone marrow was made. Patient was put on chemo-radiation therapy

Bone metastasis usually occurs late in the course of the disease, but in some patients it is the first manifestation of lung cancer.² Metastases to bone marrow of prostate, breast, pancreas, gastric adenocarcinoma and small cell carcinoma of lung have been frequently reported, but bone marrow involvement in pulmonary adenocarcinoma is not expected.³

Occurrence of sixth nerve palsy as sole neurodeficit in a patient of lung cancer without brain parenchymal lesion is yet unreported to the best of our knowledge. Our patient had involvement of sixth cranial nerve, not because of brain parenchymal lesion or raised intracranial tension but because of destructive lytic lesion involving clivus & basis sphenoid.

Neetu N Agrawal*, MS Ghogare*, YV Bansod**

*Postgraduate Residents; **Professor of Department of Medicine, Government Medical College, Nagpur.

Received : 28.2.2008; Revised : 28.5.2008; Accepted : 29.9.2008

REFERENCES

1. Yasumitsu Hirano, Makoto Oda, et al. Long term survival cases of lung cancer presented as solitary bone metastasis. *Ann Thorac Cardiovasc Surg* 2005;11.
2. Kagohashi K, Satoh H, Ishikawa H, Ohtsuka M, Sekizawa K. Bone metastasis as the first manifestation of lung cancer. *Int J Clin Pract* 2003;57:184-6.
3. Mustafa Kolsuz, et al. A Pulmonary Adenocarcinoma with Miliary Lung Metastases and Bone Marrow Involvement. *Turkish Respiratory Journal* 2000;1.