


## Successful treatment of aggressive posterior retinopathy of prematurity with diode laser in ocular albinism: A case report

*Anil B Gangwe, Swapnil M Parchand, Raj Vardhan Azad<sup>1</sup>, Deepshikha Agrawal<sup>2</sup>, Priyavrat Bhatia<sup>3</sup>*

Access this article online	
Quick Response Code:	Website: <a href="http://www.ijo.in">www.ijo.in</a>
	DOI: 10.4103/ijo.IJO_768_18

Vitreoretina Services, MGM Eye Institute, Raipur, <sup>1</sup>Raj Retina and Eye Care Hospital, Patna, Bihar, <sup>2</sup>Cornea and Anterior segment Services, MGM Eye Institute, <sup>3</sup>MGM Eye Institute, Raipur, India

**Correspondence to:** Dr. Anil B Gangwe, MGM Eye Institute, 5<sup>th</sup> mile Vidhan Sabha Road, Raipur, Chhattisgarh - 493 111, India. E-mail: [anil@mgmeye.org](mailto:anil@mgmeye.org)

Manuscript received: 07.05.18; Revision accepted: 13.09.18

Oculocutaneous albinism is characterized by partial or complete absence of melanin in retinal pigment epithelium (RPE) and uveal melanocytes. Absence of typical fundal background from RPE and choroid makes it difficult to diagnose retinal disorders in ocular albinism. Lack of melanin in RPE makes the laser photocoagulation very challenging in these cases. This report

This is an open access journal, and articles are distributed under the terms of the Creative Commons Attribution-NonCommercial-ShareAlike 4.0 License, which allows others to remix, tweak, and build upon the work non-commercially, as long as appropriate credit is given and the new creations are licensed under the identical terms.

**For reprints contact:** [reprints@medknow.com](mailto:reprints@medknow.com)

**Cite this article as:** Gangwe AB, Parchand SM, Azad RV, Agrawal D, Bhatia P. Successful treatment of aggressive posterior retinopathy of prematurity with diode laser in ocular albinism: A case report. Indian J Ophthalmol 2019;67:962-4.

presents a unique case of preterm infant of oculocutaneous albinism diagnosed as aggressive posterior retinopathy of prematurity (APROP), which was successfully treated with diode laser photocoagulation. The parameters of the laser used in this case were higher than usual, just enough to achieve blanching of retina. This report highlights the fact that the diagnosis of APROP and its treatment with laser is challenging in the presence of oculocutaneous albinism, but it is possible to achieve complete regression using diode laser at higher parameters.

**Key words:** Aggressive posterior retinopathy of prematurity, laser photocoagulation, ocular albinism, retinopathy of prematurity

Oculocutaneous albinism is a relatively uncommon inborn error of metabolism affecting the activity of enzyme tyrosine kinase. It is characterized by either complete absence or reduced synthesis of melanin involving skin, uvea, and retinal pigment epithelium (RPE). Glare, nystagmus, and refractive error are the predominant causes of low vision in both ocular and oculocutaneous albinism. Owing to absence or reduced amount of melanin in uvea and RPE, the diagnosis and management of retinal disorders have been challenging. Difficulties in visualization of retinal tears and application of endolaser have been reported in cases of ocular albinism developing retinal detachment.<sup>[1]</sup>

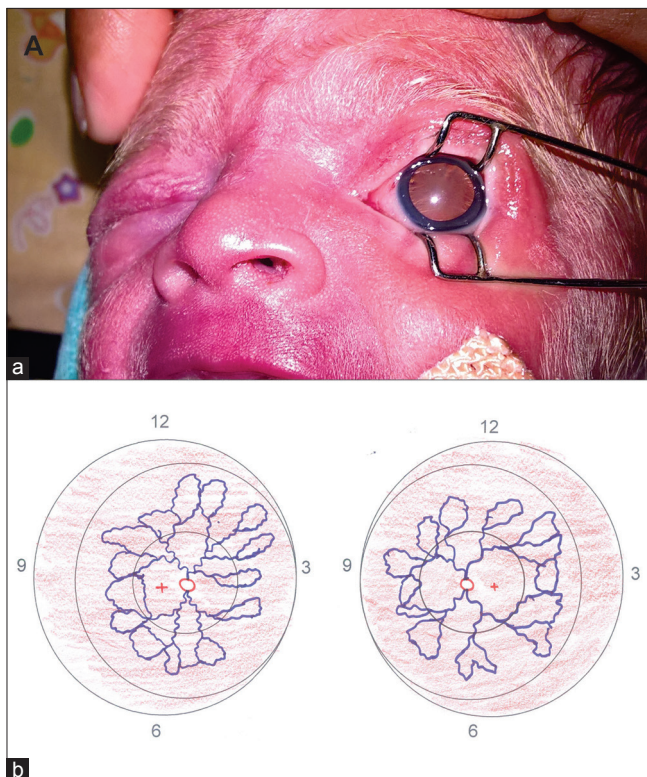
## Case Report

A preterm female child of a mother with oculocutaneous albinism born at 30 weeks of gestation with a birth weight

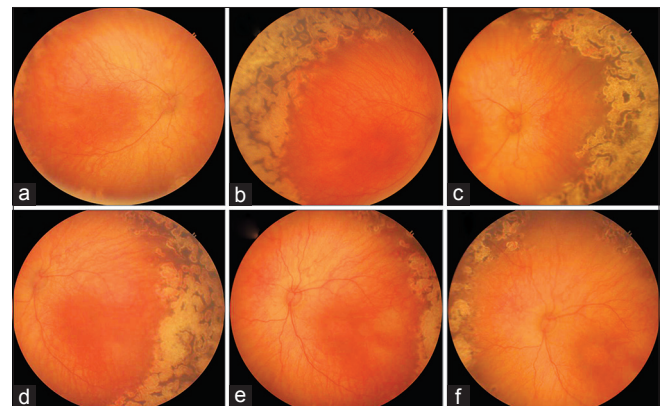
of 1140 g was screened for retinopathy of prematurity at 33 weeks of postmenstrual age. Physical examination revealed fair complexion with golden hair over skin and scalp. Ocular examination revealed light pigmentation of iris in both eyes. Bilateral pupil was well dilated [Fig. 1a]. Fundus examination revealed clear media with orange glow and hypopigmentation of RPE and choroid. Retinal blood vessels were identified by their origin from center of optic nerve head and characteristic dichotomous branching. There were arteriovenous shunts enclosing avascular retina along with multiple flat neovascularization in zone 2 [Fig. 1b]. There was no demarcation line, ridge, or extraretinal fibrovascular proliferation at the junction of vascular and avascular retina. Retinal vessels at posterior pole were dilated and tortuous. On the basis of findings of clinical examination, it was diagnosed as a case of oculocutaneous albinism with zone 2 aggressive posterior retinopathy of prematurity (APROP).

After parental counselling, the baby was planned for laser photocoagulation under topical anesthesia. The procedure was carried out using diode laser indirect ophthalmoscope. It was started with parameters of 250 mW power, 200 ms duration. As no visible reaction of laser or RPE blanching was noted with the above parameters, the power and duration were gradually raised up to 500 mW and 350 ms, respectively. Using these parameters about 200 laser spots were applied over the avascular retina, but no immediate visible laser reaction was noted. Further increase of parameter was avoided due to possible risk of retinochoroidal and Bruch membrane rupture. The procedure was temporarily suspended and the fundus was examined after 5 min. It revealed very mild blanching of retina. The procedure was resumed and entire avascular retina including avascular area within arteriovenous shunt was ablated using the same laser parameters. Topical prednisolone acetate 1% four times a day and homatropine hydrobromide 2% twice daily were prescribed for both eyes for a week.

During procedure, the baby did not experience any complications such as desaturation, apnea, tachycardia, which could have been attributed to the use of high laser energy. During follow-up, there were no features of excess inflammation such as posterior synechiae, vitreous haze, or choroidal effusion. There was no evidence of retinal tear or



**Figure 1:** (a) Baby's face photo showing golden colored hairs, fair complexion, well-dilated pupil, and hypopigmented iris. (b) Fundus drawing for both eyes depicting arteriovenous shunts or loops in zone 2 and avascular retina beyond it along with disease



**Figure 2:** Regressed APROP at 6 weeks after laser photocoagulation. (a-c) Fundus photographs of right eye. (d-f) Fundus photographs of left eye

choroidal hemorrhage, which could have possibly resulted from use of high laser energy during the procedure. No skip areas were noted and no repeat laser treatment was needed. APROP regressed completely by 6 weeks of follow-up [Fig. 2]. Cycloplegic refraction using atropine at 6 months showed +2.5 D sphere in each eye.

## Discussion

We had options of intravitreal anti-vascular endothelial growth factor (VEGF) and laser photocoagulation or cryoablation of avascular retina, for the management of this case. Role of intravitreal anti-VEGF has been established in the management of treatable ROP. It has distinctive advantages in infants or neonates with zone I disease or aggressive posterior ROP and also has a higher rate of recurrence of ROP, so a careful and longer follow-up is mandatory.<sup>[2]</sup> We did not prefer to use anti-VEGF because of lack of standardization about its indication, dose in neonates with ROP, as well as our limited experience about its use in ROP. Cryotherapy needs general anesthesia and is associated with more pain and inflammation, so it was not preferred as the mode of treatment in this case.

Lack of melanin in RPE makes it theoretically difficult to achieve laser burns in ocular albinism. There are reports with variable opinion about laser reaction in ocular albinism. Yang *et al.* in a case of rhegmatogenous retinal detachment (RRD) and Hanson *et al.* in case of proliferative diabetic retinopathy could not achieve laser reaction during pars plana vitrectomy due to associated ocular albinism.<sup>[3,4]</sup> Both the cases needed cryoablation of retina to complete the treatment. Sinha *et al.* in a series of six cases of RRD in ocular albinism have reported that after settling the detached retina, visible laser reaction could be achieved in three out of six cases using Argon green laser (532 nm) with power 200–400 mW and a duration of 150–300 ms.<sup>[5]</sup> Huang *et al.* have suggested using Argon yellow laser with a longer duration (300–500 ms) to achieve adhesion between neurosensory retina, RPE, and choriocapillaris in a case of RRD associated with ocular albinism.<sup>[6]</sup> Laser reaction has also been documented using Krypton red laser in a case of RRD with ocular albinism.<sup>[7]</sup> In our case, we used diode laser (810 nm), which has relatively deeper penetration in choroid, compared to yellow green lasers. This possibly resulted in laser uptake by hemoglobin in choriocapillaris as well as choroidal melanocytes, with resultant effect of photocoagulation involving RPE and outer retinal layers. To the best of our knowledge, this is the first report where APROP has been reported in association with ocular albinism which has been successfully treated with

laser photocoagulation. We do not have pretreatment fundus images for the case, which could be a limitation of this report.

## Conclusion

To conclude, it is theoretically difficult and technically challenging to perform retinal photocoagulation in ocular albinism but our case report suggests that it can be successfully done using the diode laser at higher parameter to achieve regression of APROP without any complications or sequelae.

## Declaration of patient consent

The authors certify that they have obtained all appropriate patient consent forms. In the form the patient(s) has/have given his/her/their consent for his/her/their images and other clinical information to be reported in the journal. The patients understand that their names and initials will not be published and due efforts will be made to conceal their identity, but anonymity cannot be guaranteed.

## Financial support and sponsorship

Nil.

## Conflicts of interest

There are no conflicts of interest.

## References

1. Jackson TL, Kwan AS, Laidlaw AH, Aylward W. Identification of retinal breaks using subretinal trypan blue injection. *Ophthalmology* 2007;114:587-90.
2. Vander Veen DK, Melia M, Yang MB, Hutchinson AK, Wilson LB, Lambert SR. Anti-vascular endothelial growth factor therapy for primary treatment of type 1 retinopathy of prematurity: A report by the American Academy of Ophthalmology. *Ophthalmology* 2017;124:619-33.
3. Yang JW, Kang SB, Park YH. A case of retinal detachment surgery in albinism patient. *J Korean Ophthalmol Soc* 2008;49:840-4.
4. Hanson RJ, Rubinstein A, Bates RA. Therapeutic challenges in the management of proliferative diabetic retinopathy in oculo-cutaneous albinism. *Invest Ophthalmol Vis Sci* 2005;46:346.
5. Sinha MK, Chhablani J, Shah BS, Narayanan R, Jalali S. Surgical challenges and outcomes of rhegmatogenous retinal detachment in albinism. *Eye* 2016;30:422-5.
6. Huang XY, Wang Y, Wang R, He GG, Gabrielian A, Mac Cumber MW. Diagnostic and therapeutic challenges. *Retina* 2012;32:399-2.
7. Hiroshi M, Hiroyuki M. A case of ocular albinism with rhegmatogenous retinal detachment. *Jpn Rev Clin Ophthalmol* 1999;93:861-4.