

Case Report

Malignant Melanoma of Anal Canal – A Diagnostic Dilemma

Bushra Siddiqui^{1*}, Shahbaz Habib Faridi², Syed Shamshad Ahmad¹, Kafil Akhtar¹, Suhailur Rehman¹, Mohsin Aijaz¹

¹Department of Pathology, JN Medical College, Aligarh Muslim University, Aligarh, Uttar Pradesh, India

²Department Of Surgery, JN Medical College, Aligarh Muslim University, Aligarh, Uttar Pradesh, India.

ABSTRACT

A 50-year-old male presented with major complaints of bleeding per -rectum and generalized weakness for past one and a half month. Digital rectal examination (DRE) and colonoscopy revealed a thrombosed internal haemorrhoid, which was surgically excised. Histopathological examination (HPE) was pointing towards anal malignant melanoma, which was further confirmed by positive immunohistochemistry (IHC) for HMB-45. As the patient had no secondaries or lymph node enlargement, he was referred for loco-regional radiotherapy. Primary ano-rectal melanoma is a rare but locally aggressive neoplasm capable of early metastasis. Owing to its non-specific clinical presentation it may be mistaken for benign conditions like haemorrhoids and may prove fatal. Surgical treatment may range from wide local excision (WLE) to abdomino-perineal resection (APR) with controversial role of chemo-radiation in advanced cases. Prognosis is usually bleak with a 5-year survival rate of less than 20%. Owing to the rarity of ano-rectal melanoma and importance of its early detection and management, this case is being reported here.

Keywords: Malignant Melanoma, cutaneous Malignancies, Anal Canal

INTRODUCTION

Malignant melanoma comprises nearly 5% of all cutaneous malignancies.^[1] After skin the next two most common locations of melanoma are retina and ano-rectum.^[2] Primary anorectal melanoma is one of the rare tumours of gastrointestinal tract and accounts for around 1-4% of all GI malignancies and 0.6-1.6% of all melanomas.^[3,4,5]


Predominantly females are affected, mostly in fifth or sixth decade of life.^[6] Patients usually present with non-specific complaints like blood streaked stools, pain, altered bowel habits or an anal mass leading to confusion with benign conditions like haemorrhoids and in turn delayed diagnosis and management.^[7, 8]

Treatment of ano-rectal melanoma is controversial ranging from wide local excision or abdominoperineal resection to loco-regional radiotherapy or chemotherapy in advanced cases.^[9] The prognosis is generally poor with 5 year survival of less than 20%.^[12]

The present case highlights the importance of early treatment of haemorrhoids, especially in elderly patients as it may be harbouring some malignant condition.

CASE SUMMARY

A 50-year-old male with no significant past medical history presented to surgical out-patient department with complaints of blood-streaked stools for 1½ months. He also complained of generalized weakness for the same duration. On general examination, the patient had mild pallor and no

Access this article online	
Website: www.iabcr.org	Quick Response code
DOI: 10.21276/iabcr.2016.2.2.17	

Received:08.03.16 **Revised:**01.04.16 **Accepted:**05.04.16

Corresponding Author

Dr. Bushra Siddiqui
Assistant Professor, Department of Pathology
JN Medical College, AMU, Aligarh-202002

Copyright: © the author(s) and publisher. IABCR is an official publication of Ibn Sina Academy of Medieval Medicine & Sciences, registered in 2001 under Indian Trusts Act, 1882. This is an open access article distributed under the terms of the Creative Commons Attribution Non-commercial License, which permits unrestricted non-commercial use, distribution, and reproduction in any medium, provided the original work is properly cited.

other significant clinical findings. His vital signs were normal. Digital examination of the rectum (DRE) revealed a thrombosed internal pile at 6'o clock position. No external mass or piles were observed. Colonoscopy confirmed the DRE findings. The patient underwent haemorrhoidectomy and the resected tissue specimen was sent for histopathological examination (HPE). Grossly, the specimen was partially skin covered and 2x1x1cm in size (Fig 1).

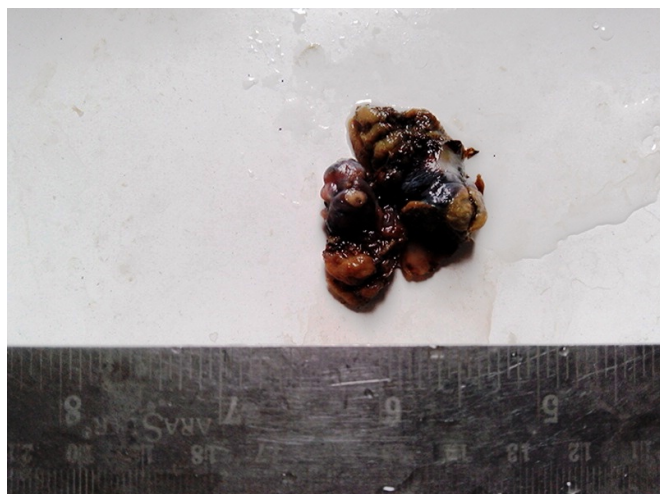

Fig 1: Gross specimen of thrombosed haemorrhoid, which turned out to be anal malignant melanoma.

On HPE, sections showed normal keratinized stratified squamous epithelium along with glands of anal mucosa. Underlying tissue showed infiltrating sheets and nests of round to ovoid to elongated atypical cells (Fig. 2). The cells had enlarged and pleomorphic nuclei with clumped chromatin. Nuclei of some cells showed prominent eosinophilic nucleoli. An area showed abundant intracellular as well as extracellular melanin pigment (Fig.3).

Areas of hemorrhage and necrosis were also seen along with dense lympho-plasmacytic infiltrate. Abnormal mitotic figures were also present. A differential diagnosis of poorly differentiated squamous cell carcinoma or malignant melanoma was made and immunohistochemistry (IHC) was advised.

On IHC analysis, tumour cells showed cytoplasmic positivity for HMB-45 (Fig. 4)

Whereas they were negative for cytokeratin. Thus, a confirmatory diagnosis malignant melanoma of anal canal was made. There was no lymphadenopathy or secondaries and the patient was referred for loco-regional radiotherapy.

DISCUSSION

Primary gastrointestinal (GI) melanomas are rare, majority being secondary melanomas. In GI melanomas the most common primary site is ano-rectum.^[10] The incidence of ano-rectal melanomas has significantly increased over the last two decades which may be attributed either to actual rise in the number of cases or improved diagnostic techniques.^[9] The melanocytes distal to the dentate line are the precursors for anorectal melanoma which per se is a

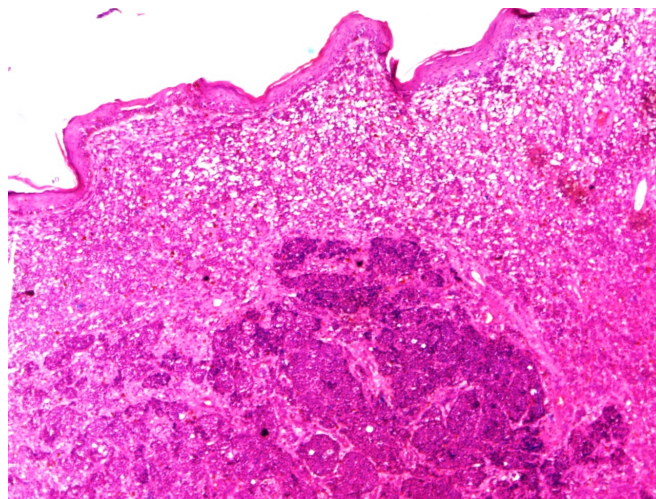


Fig 2: Hematoxylin & Eosin X 40: Section showing nests of malignant cells with surrounding desmoplastic reaction. Overlying stratified squamous epithelium of anal region also seen.

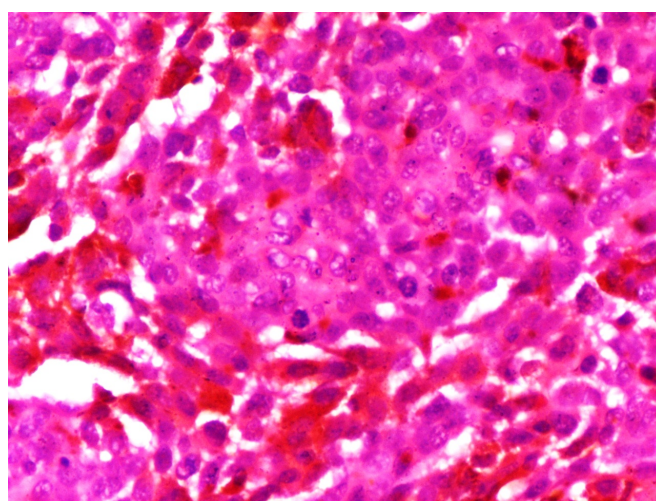


Fig 3: Hematoxylin & Eosin X 400: high power view of malignant cells with pleomorphic nuclei with clumped chromatin and prominent nucleoli along with intracytoplasmic melanin formation.

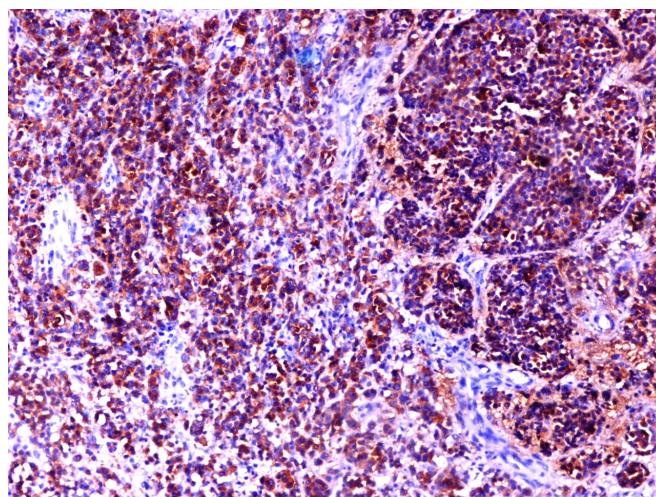


Fig 4: HMB-45X100: Section showing cytoplasmic positivity for HMB-45 immunomarker.

rare and lethal condition comprising only 0.1% – 4.6% of all ano-rectal malignancies^[1, 2] Patients usually present late when distant metastases has already occurred.^[11] Higher incidence is seen in females, elderly patients in fifth or sixth decade and in Caucasians.^[9] The reason for delayed

diagnosis of ano-rectal melanoma is its non-specific presentation mimicking other conditions like haemorrhoids, polyp, rectal ulcer or adenocarcinoma.^[12] Also, only 20% cases show gross melanin pigmentation, rest are amelanotic.^[2] Patients usually complain of blood in stools, pain, tenesmus, altered bowel habits or anorectal mass.^[13] Our patient was a 50 year old male who was having blood streaked stools and generalized weakness for the past one and a half month. On digital rectal examination (DRE) and colonoscopy, it was thought to be a simple case of a thrombosed haemorrhoid and was surgically excised. There was no gross pigmentation; however, histopathological examination showed sheets and nests of malignant cells, round to elongated in shape with raised nucleo-cytoplasmic ratio, hyperchromasia and prominent eosinophilic nucleoli. There was extracellular and intracellular melanin production, desmoplastic reaction and necrosis. A differential diagnosis of poorly differentiated squamous cell carcinoma and malignant melanoma was made and immunohistochemistry was advised for confirmation. The immunohistochemical panel of S-100, Melan-A, HMB-45 and tyrosinase is useful for confirming melanoma.^[9] Our case was positive for HMB-45 and negative for cytokeratin, thereby it was confirmed to be a rare case of ano-rectal malignant melanoma.

Owing to delay in diagnosis and aggressive behaviour of ano-rectal melanomas, secondaries to liver, lungs, pelvis or brain are common and may be seen in around 60% of cases at the time of diagnosis.^[2,13] Hence, before planning treatment, imaging studies like chest X-ray, CECT chest/abdomen and pelvis along with PET scan should be done to rule out secondaries and to stage the tumour.^[6,13] In the present case the tumor was in early stage and whole body imaging studies ruled out any distant metastases.

As far as the management of ano-rectal melanomas is concerned, the choice of ideal surgical procedure is still debatable with some recent studies emphasizing that sphincter saving local excision with loco-regional radiotherapy is apt for small tumours and it results in lesser morbidity. While for larger and obstructing tumors abdomino-perineal resection (APR) should ideally be done.^[6] The role of adjuvant chemotherapy is controversial however, malignant melanoma owes its aggressiveness to loss of c-kit and hence, tyrosine kinase inhibitors like imatinib may prove beneficial.^[2,9] Immune mediators like interferon 2 alpha and interleukin 2 may also play some role in patients with metastatic malignant melanoma.^[13]

Despite of all these treatment modalities prognosis is still grave for the patient and depends on the depth of invasion, stage, duration, size of the tumor and lymph node status.^[2,9] The 5 year survival rates for patients with local, regional and metastatic ano-rectal malignant melanoma are 32%, 17% and 0% respectively.^[13] In our patient as the tumour was of small size, detected in early stage with no secondaries, local excision was done and patient underwent loco-regional radiotherapy.

CONCLUSION

Anorectal melanoma is a rare, aggressive and lethal neoplasm with early metastases. Clinically it may be confused with a number of other benign or malignant conditions most commonly with haemorrhoids. Its possibility should always be kept in mind whenever surgeons are dealing with an elderly patient with bleeding per rectum or ano-rectal mass. Whole body imaging should be done to rule out metastases before doing any surgical procedure which may range from local excision with loco-regional radiotherapy for small tumors or abdomino-perineal resection (APR) for large tumors. Prognosis is poor and depends on the stage of the tumor indicating the importance of early detection of ano-rectal melanomas. Studies are being done to provide effective adjuvant chemotherapy for the patients.

What this study adds

1. What is known about this subject?

Ano rectal malignant melanoma is a very rare primary malignancy of lower gastrointestinal tract. It is the third most common site of predilection of malignant melanoma after skin and eye. It has poor prognosis with early distant metastasis and less than 20 percent 5-year survival rate.

2. What new information is offered in this study?

Clinically ano rectal malignant melanoma may be confused with a number of other benign or malignant conditions of this region, most commonly with hemorrhoids. Its possibility should always be kept in mind whenever surgeons are dealing with an elderly patient with bleeding per rectum or ano-rectal mass as in our patient.

REFERENCES

- Carcoforo P, Raiji MT, Palini GM, Pedriali M, Maestroni U, Soliani G et al. Primary anorectal melanoma: an update. *J Cancer* 2013; 3:449e453.
- Tomioka K, Ojima H, Sohda M, Tanabe A, Fukai Y, Sano A et al. Primary malignant melanoma of the rectum: report of two cases. *Case Rep Surg.* 2012;2012:247348.
- Trzcinski R, Kujawski R, Mik M, Sygut A, Dziki L, Dziki A. Malignant melanoma of the anorectum-a rare entity. *Langenbecks Arch Surg.* 2010;395:757-60.
- Nivatvongs S. Perianal and anal canal neoplasms. In: Gordon PH, Nivatvongs S, eds. *Colon, Rectum and Anus.* 3rd ed. New York: Informa Healthcare; 2007:369-390.
- Garrett K, Kalady MF. Anal neoplasms. *Surg Clin North Am* 2010; 90:147-161.
- Van Schaik P, Ernst M, Meijer H, Bosscha K. Melanoma of the rectum: A rare entity. *World Journal of Gastroenterology* : WJG. 2008;14:1633-1635.
- Singer M, Mutch MG. Anal melanoma. *Clin Colon Rectal Surg* 2006;19:78-87.
- Roviello F, Cioppa T, Marrelli D, Nastri G, De Stefano A, Hako L et al. Primary ano-rectal melanoma: considerations on a clinical case and review of the literature. *Chir Ital* 2003;55:575-80

9. Khan M, Bucher N, Elhassan A, Barbaryan A, Ali AM, Hussain N *et al.* Primary Anorectal Melanoma. *Case Reports in Oncology*. 2014;7:164-170.
10. Akaraviputh T, Arunakul S, Lohsiriwat V, Iramaneerat C, Trakarnsanga A. Surgery for gastrointestinal malignant melanoma: Experience from surgical training center. *World Journal of Gastroenterology : WJG*. 2010;16:745-748.
11. Chute DJ, Cousar JB, Mills SE. Anorectal malignant melanoma: morphologic and immunohistochemical features. *Am J ClinPathol* 2006; 126:93–100.
12. Zhang S, Gao F, Wan D. Effect of misdiagnosis on the prognosis of anorectal malignant melanoma. *J Cancer Res Clin Oncol* 2010;136:1401–1405.
13. Praveen L, Kumar V, Pujahari AK. Lesson Learnt in Anal Melanoma: A Case Report. *Indian Journal of Clinical practice* 2014; 25: 678-679

How to cite this article: Siddiqui B, Faridi SH, Ahmad SS, Akhtar K, Rehman S, Aijaz M. Malignant Melanoma of Anal Canal – A Diagnostic Dilemma. *Int Arch BioMed Clin Res*. 2016 April;2(2):79-82.DOI: 10.21276/iabcr.2016.2.2.17

Source of Support: Nil, **Conflict of Interest:** Nil