Case Report

Left atrial ball thrombus with acute mesenteric ischemia: Anesthetic management and role of transesophageal echocardiography

Neeti Makhija, Dhananjay Malankar[1], Pooja Singh, Sameer Goyal, Kartik Patel[1], Priya Jagia[2]

Departments of Cardiac Anaesthesia, [1]Cardiothoracic and Vascular Surgery, and [2]Cardiovascular and Interventional Radiology, Cardiothoracic Centre, All India Institute of Medical Sciences, New Delhi, India

ABSTRACT

A 62 year old female with severe mitral stenosis, large left atrial ball thrombus and acute mesenteric ischemia emergently underwent mitral valve replacement, left atrial clot removal and emergency laparotomy for mesenteric ischemia. Peri-operative management issues, particularly, the anesthetic challenges and the role of transesophageal echocardiography are discussed.

Received: 25-08-13
Accepted: 12-02-14

Key words: Acute mesenteric ischemia; Combined cardiac and non-cardiac surgery; Left atrial clot; Mitral stenosis; Superior mesenteric artery embolism

INTRODUCTION

Free floating ball thrombus in the left atrium (LA) is rare and carries the risks of total obstruction of mitral valve and systemic embolization;[1] and requires prompt removal. Acute mesenteric ischemia is a life-threatening condition with a mortality rate of 60-80%, especially if intestinal infarction has occurred and surgical intervention becomes emergent.[2] We describe anesthetic management of a patient undergoing emergent open heart surgery for removal of LA ball thrombus, mitral valve replacement and exploratory laparotomy in the same sitting.

Video available on www.annals.in

Access this article online
Website: www.annals.in
DOI: 10.4103/0971-9784.129868
Quick Response Code:

CASE REPORT

A 62-year-old female patient presented with the history of pain in the abdomen and vomiting for 2 days. Seven weeks back patient had presented with hemiparesis and was diagnosed to have cerebral embolism with rheumatic severe mitral stenosis. She was put on warfarin, β-blocker, digoxin and diuretic therapy, but often skipped medication. On examination, the pulse was irregularly irregular, the rate was 110 beats/min and blood pressure was 118/80 mmHg. On auscultation, the first heart sound was loud and there was an opening snap and a mid-diastolic murmur in the apical area. Abdominal examination revealed periumbilical and epigastric tenderness with decreased bowel sounds. Chest X-ray posteroanterior view showed cardiomegaly with LA enlargement and pulmonary congestion. Electrocardiogram (ECG) showed atrial fibrillation with fast ventricular rate. Transthoracic echocardiography showed mitral valve area of 0.8 cm^2, a large free floating ball in LA, moderate tricuspid regurgitation and normal left ventricular function. Computed tomographic angiogram of the chest showed a large ball in LA. Computed tomographic angiogram of the abdomen showed superior mesenteric artery (SMA) occlusion at L3 level [Figure 1]. Coronary angiography was normal. Laboratory investigations revealed hemoglobin 13.2 g%, total leukocytes count 13,700 cells/cu mm, platelet count 152 × 10^3/μl, prothrombin time 16 s with a control of 11.6 s, blood urea 69 mg/dl, serum creatinine 1.3 mg/dl and blood lactate concentration 1.6 mmol/L. A diagnosis

Address for correspondence: Dr. Neeti Makhija, Department of Cardiac Anaesthesia, Room No. 9, 7th Floor, Cardiothoracic Centre, All India Institute of Medical Sciences, Ansari Nagar, New Delhi - 110 029, India. E-mail: neetimakhija@hotmail.com

of rheumatic heart disease, severe mitral stenosis with atrial fibrillation, large LA ball thrombus, SMA embolic occlusion and acute mesenteric ischemia was made. Antibiotic therapy with intravenous cefotaxime 1 g and metrogyl 500 mg was started 8 hourly. Initially, after coronary angiography, an attempt to re-canalize the SMA was made, which failed. A bolus of 5,000 IU of unfractionated heparin was administered during the procedure, followed by heparin infusion at 18 IU/Kg/h. The patient was taken for emergency LA clot removal, mitral valve replacement and an emergency laparotomy for mesenteric ischemia.

In the operation theater, monitoring started with ECG, pulse oximetry (SpO_2) and invasive radial artery pressure. Patient was pre-oxygenated with 100% oxygen for 3 min and rapid sequence anesthetic induction was performed using intravenous fentanyl 200 μg, midazolam 2 mg and thiopentone 150 mg. Sellick's maneuver was applied immediately after the loss of consciousness and concomitantly, rocuronium 50 mg was administered to facilitate tracheal intubation. Anesthesia was maintained with fentanyl, midazolam, vecuronium and isoflurane 0.5-1% in oxygen. Intermittent positive pressure ventilation was targeted to maintain normocapnia. Additional monitoring included end-tidal carbon dioxide, central venous pressure (right internal jugular vein), nasopharyngeal temperature, urine output, serum electrolytes, arterial blood gases (ABG), blood glucose, activated coagulation time (ACT), transesophageal echocardiography (TEE) and bispectral index. During TEE examination, mid esophageal 4-chamber view showed a severely stenotic mitral valve with thickened and calcified leaflet, severe LA dilatation with spontaneous echo contrast and a free floating LA ball with regions of echolucency [Video 1]. The LA ball thrombus measured 4.5 × 2.7 cm [Figure 2].

On standard hypothermic cardiopulmonary bypass (CPB) and myocardial protection with antegrade infusion of hyperkalaemic cold blood solution, the LA ball thrombus was removed [Figure 3], LA appendage was ligated and the mitral valve was replaced with size 31 Hancock II porcine bioprosthetic valve. After aortic cross clamp removal a bolus of 150 mg amiodarone was administered over 10 min followed by an infusion of 5.0 μg/kg/min. Patient continued to remain in atrial fibrillation although ventricular rate was controlled. During re-warming nitroglycerine (NTG) 0.5 μg/kg/min and dobutamine 5 μg/kg/min were stared. At the time of separation from CPB, dopamine 5 μg/kg/min, noradrenaline 0.05-1.0 μg/kg/min

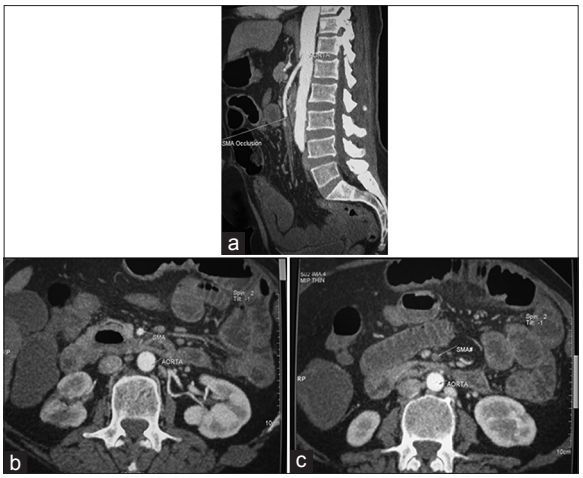

Figure 1: (a) Sagittal maximum intensity projection image of computed tomographic angiogram showing a superior mesenteric artery (SMA) occlusion at L3 level. (b) Axial intensity projection computed tomographic angiogram shows patent proximal SMA lumen, (c) Caudal image shows distal occlusion of SMA at L3 level

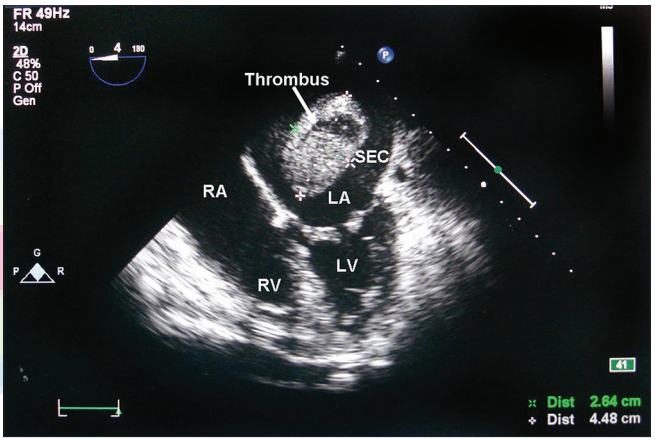

Figure 2: Midesophageal four chamber view shows a severely stenotic mitral valve with thickened and calcified leaflets and associated severe left atrial dilatation with spontaneous echo contrast and a free floating left atrial ball thrombus. SEC: Spontaneous echo contrast, LA: Left atrium, LV: Left ventricle, RA: Right atrium, RV: Right ventricle

Figure 3: Ball thrombus retrieved from the left atrium

were started and NTG was stopped. Aortic cross clamp and CPB times were 81 and 55 min, respectively. Heparin was reversed with protamine 1.3 mg/100 U of heparin. The ACT after protamine administration was 179 s. An additional 1 mg/kg of protamine was administered and an ACT of 140 s was achieved. Post CPB, TEE examination revealed no paravalvular leak, no residual thrombus in LA and the pressure gradient across the prosthetic valve was normal. Overall, the patient was transfused 1 unit of packed red blood cell (PRBC) during CPB; and 1 unit each of PRBC, platelet concentrate and fresh frozen plasma after separation from CPB. After chest closure patient was handed over to gastrointestinal surgical team for laparotomy.

On laparotomy, middle ileum was gangrenous and the adjoining 10 cm of both proximal and distal ileum was dusky. A foul smelling serous exudate was present in moderate amounts in the peritoneal cavity. Liver, spleen, stomach, duodenum, jejunum and colon were normal. Ileocaecal resection with jejuno-ascending colon anastomosis was done. During resection and anastomosis multiple episodes of tachyarrhythmias and hypotension occurred. Based on TEE and ABG examination, hypovolemia, hematocrit and electrolytes were corrected by transfusing 1 unit of PRBC and infusing appropriate doses of potassium chloride and sodium bicarbonate over 30 min. ABG and electrolytes were repeated at 30 min interval and maintained in the normal range. Patient was transferred to intensive care unit for elective ventilation and extubated on the post-operative day 2. Post-operative recovery of the patient was uneventful.

DISCUSSION

A large LA ball thrombus is a rare complication of severe mitral stenosis.[3,4] In recent years many cases of ball thrombus have been reported due to wide spread use of echocardiography.[5-7] Reported symptoms of thrombus in LA include paroxysmal nocturnal dyspnea, syncope and symptoms due to peripheral arterial embolism.[1] The clinical setting of mitral stenosis and LA enlargement with atrial fibrillation, favors the diagnosis of thrombus but LA myxoma may also simulate a thrombus. In a clinical setting that favors thrombus, anticoagulation and echocardiographic follow-up can help to differentiate between a myxoma and thrombus.[8] The thrombus may organize or dissolve with anticoagulant therapy whereas no change will occur in myxoma with anticoagulant therapy.

Mesenteric artery embolism is an acute abdominal emergency. A high index of suspicion is required for diagnosis. Mesenteric artery embolism accounts for 25-30% of patients with intestinal ischemia. On an average 90-95% of emboli arise from heart. The presence of cardiac arrhythmias in a patient with onset of diffuse, severe, unremitting and generalized abdominal pain should raise the possibility of SMA occlusion. The embolus usually lodges just beyond the origin of middle colic artery where the caliber of SMA narrows rapidly. Computed tomography (CT) mesenteric angiography is the most reliable diagnostic tool and helps locating the exact site of blockage.[9] Contrast enhanced CT detects acute mesenteric ischemia with sensitivity rates exceeding 90%.[10] CT findings include focal and segmental thickening, submucosal edema, or hemorrhage, pneumatosis and portal venous gas.[11] Biphasic multi-detector row CT with mesenteric CT angiography has sensitivity of 96% and specificity of 94%.[12] In the present patient the CT angiography revealed SMA block.

Intra-arterial infusion of thrombolytic agents, streptokinase, urokinase, or a recombinant tissue plasminogen activator, has been shown to be effective when used within 12 h of the onset of symptoms.[13] Surgical management of the patient presenting with symptomatic ball thrombus with severe mitral stenosis with acute mesenteric ischemia is not clear. Initially, the emergency situation of bowel ischemia can be dealt with followed by mitral valve surgery later. This approach was described by Misawa *et al*. for infective endocarditis of mitral valve with SMA thrombosis.[14] This approach may be disadvantageous as the patient is still at high risk of embolization and death as cardiac pathology is not treated. Alternatively, both pathology can be tackled simultaneously as we did in our patient. With this approach, the patient is at no more risk for repeated embolization.

Anesthetic management of such a case is challenging due to multiple risks such as embolization during induction of anesthesia and surgery, possibility of sudden obstruction of mitral valve, presence of arrhythmias, pulmonary hypertension, marked hemodynamic instability and risks associated with surgery in presence of intestinal ischemia such as acid base and electrolyte imbalance and septicemia. In addition, our patient was on warfarin, digoxin and diuretic therapy. However, in our patient the coagulation profile was not deranged, therefore, intra-operatively bleeding was not a major

concern and the patient did not require much of fresh frozen plasma and platelet concentrates.

In the present case, TEE confirmed the pre-operative diagnosis and ruled out any additional thrombus in the LA and any other pathology. With the help of TEE the presence of thrombus can be monitored; however, one cannot do anything if the thrombus embolize. TEE is helpful in de-airing and in confirming complete removal of thrombus, functioning of prosthetic valve and response to inotropic agents. In the present case, TEE also helped in the assessment of cardiac and volume status during intestinal resection anastomosis thus helping in fluid resuscitation and pharmacological management.

To summarize, severe mitral stenosis with atrial fibrillation, large free floating ball thrombus in LA with acute mesenteric ischemia due to SMA embolic occlusion is a rare life-threatening condition. Surgical treatment is emergent. Simultaneous mitral valve replacement and bowel resection is feasible approach as was carried out in this case. The anesthetic management is challenging and TEE helps in the management of anesthesia.

REFERENCES

1. Wrisley D, Giambartolomei A, Lee I, Brownlee W. Left atrial ball thrombus: Review of clinical and echocardiographic manifestations with suggestions for management. Am Heart J 1991;121:1784-90.
2. Vitin AA, Metzner JI. Anesthetic management of acute mesenteric ischemia in elderly patients. Anesthesiol Clin 2009;27:551-67.
3. Fraser AG, Angelini GD, Ikram S, Butchart EG. Left atrial ball thrombus: Echocardiographic features and clinical implications. Eur Heart J 1988;9:672-7.
4. Lie JT, Entman ML. "Hole-in-one" sudden death: Mitral stenosis and left atrial ball thrombus. Am Heart J 1976;91:798-804.
5. Lee AY, Chang MC, Chen TJ, Chang WF. Left atrial and ventricular ball thrombi complicating rheumatic heart disease with combined mitral and aortic stenosis. Echocardiography 2001;18:159-61.
6. Misumi T, Kudo M, Ito T, Matsubara T, Kumamaru H. Floating ball thrombus in the left atrium with mitral stenosis. Jpn J Thorac Cardiovasc Surg 2003;51:387-9.
7. Leung DY, Davidson PM, Cranney GB, Walsh WF. Thromboembolic risks of left atrial thrombus detected by transesophageal echocardiogram. Am J Cardiol 1997;79:626-9.
8. Diaconu CC. Left atrial thrombus: A case report. J Med Life 2011;4:417-8.
9. Boley SJ, Brandt LJ, Sammartano RJ. History of mesenteric ischemia. The evolution of a diagnosis and management. Surg Clin North Am 1997;77:275-88.
10. Laissy JP, Trillaud H, Douek P. MR angiography: Noninvasive vascular imaging of the abdomen. Abdom Imaging 2002;27:488-506.
11. Sheehan SR. Acute mesenteric ischemia: Recent advances in diagnosis and endovascular therapy. Emerg Radiol 2000;7:231-6.
12. Kirkpatrick ID, Kroeker MA, Greenberg HM. Biphasic CT with mesenteric CT angiography in the evaluation of acute mesenteric ischemia: Initial experience. Radiology 2003;229:91-8.
13. Simó G, Echenagusia AJ, Camúñez F, Turégano F, Cabrera A, Urbano J. Superior mesenteric arterial embolism: Local fibrinolytic treatment with urokinase. Radiology 1997;204:775-9.
14. Misawa S, Sakano Y, Muraoka A, Yasuda Y, Misawa Y. Septic embolic occlusion of the superior mesenteric artery induced by mitral valve endocarditis. Ann Thorac Cardiovasc Surg 2011;17:415-7.

Cite this article as: Makhija N, Malankar D, Singh P, Goyal S, Patel K, Jagia P. Left atrial ball thrombus with acute mesenteric ischemia: Anesthetic management and role of transesophageal echocardiography. Ann Card Anaesth 2014;17:148-51.

Source of Support: Nil, **Conflict of Interest:** None declared.