

Original Research Article

Usefulness of serology in diagnosis of different clinical presentations of ocular toxoplasmosis

Saritha V. Krishnankutty*, Reni Philip, Vijayamma Narayani

Department of Ophthalmology, Government Medical College, Kottayam, Kerala, India

Received: 05 January 2020

Revised: 16 January 2020

Accepted: 21 January 2020

*Correspondence:

Dr. Saritha V. Krishnankutty,
E-mail: drsarithavk@yahoo.com

Copyright: © the author(s), publisher and licensee Medip Academy. This is an open-access article distributed under the terms of the Creative Commons Attribution Non-Commercial License, which permits unrestricted non-commercial use, distribution, and reproduction in any medium, provided the original work is properly cited.

ABSTRACT

Background: Large proportions of acquired cases of ocular toxoplasmosis are reported with atypical presentations. The objectives of the study were to find out whether any correlation existed between serological findings of typical and atypical presentations of ocular toxoplasmosis as compared to cases presenting with non-toxoplasmic uveitis and to find out the proportion of various atypical presentations of ocular toxoplasmosis.

Methods: It was a prospective observational study. The study subjects of ocular toxoplasmosis were tested for immunoglobulin M (IgM) and immunoglobulin G (IgG) toxoplasma antibody levels in serum by ELISA (enzyme-linked immunosorbent assay) technique. The proportion of atypical presentation among total toxoplasma cases and distribution of atypical cases were calculated. Fisher's exact test, one-way analysis of variance and Kruskal-wallis test were used as applicable.

Results: Among the cases (n=35) thirteen patients had typical presentation of a retinochoroidal focus with an adjacent scar and 22 patients had atypical features. Control group consisted of 24 patients. Various types of presentations in atypical cases were retinitis patch without an adjacent scar (31.8%), intermediate uveitis (27.3%), papillitis (22.7%) retinal vasculitis and dense vitritis (9.09% each). Mean IgG levels in typical cases (85.3±82.9 IU/ml) and atypical cases (47.5±66.2) were significantly higher than control group (6.6±3.4, p<0.001).

Conclusions: Serology is a useful tool in the diagnosis of ocular toxoplasmosis with a compatible clinical picture as serum IgG levels are significantly elevated in both typical and atypical presentations of ocular toxoplasmosis as compared to cases presenting with non-toxoplasmic uveitis.

Keywords: Ocular, Toxoplasmosis, Typical, Atypical, Serology

INTRODUCTION

Toxoplasma is the most common cause of posterior uveitis in immunocompetent individuals.¹ The incidence of ocular toxoplasmosis among individuals infected with toxoplasma gondii is approximately 2% and it varies with region.² Though previously considered a congenital disease, large proportion of acquired cases are reported recently with atypical presentations which support the view that acquired infections might be a more important cause of ocular disease than congenital ones.³⁻⁵ Many of

the acquired forms have atypical presentations even in patients without any immune deficiency.

The diagnosis of ocular toxoplasmosis is mainly clinical. There are many tests for diagnosis however none are 100% sensitive or specific, hence diagnosis is mainly based on clinical findings. However especially in the atypical clinical presentations where other differential diagnoses have to be kept in mind, investigations aid in diagnosis.⁶ Serological detection of immunoglobulin M (IgM) and immunoglobulin G (IgG) toxoplasma

antibodies is a relatively cheap and less invasive method. Though previously thought to exclude toxoplasmosis when a negative value was obtained, recent studies indicate a positive serology could be useful in diagnosis.^{7,8}

This study was aimed to look into the various presentations of ocular toxoplasmosis and its correlation with serological antibody titers in these patients. The primary objective of our study was to find out whether any correlation existed between serological findings of typical and atypical presentations of ocular toxoplasmosis as compared to cases presenting with non-toxoplasmic uveitis. The secondary objective was to find out the proportion of various atypical presentations of ocular toxoplasmosis.

METHODS

It was a prospective observational study conducted at Government Medical College, Kottayam, Kerala after obtaining Institutional Ethical Committee clearance (SBMR-IRC:P/03/2014 dated 01.04.2014) and patients' consent. All cases of uveitis with no evidence of immunosuppression presenting to the Ophthalmology outpatient department for a period of two years were recruited from April 2014 to March 2016. Patients were selected after careful slit lamp examination and indirect ophthalmoscopy. A fresh retinitis patch adjacent to an old pigmented retinochoroidal scar with moderate to severe vitritis was taken as the typical presentation of ocular toxoplasmosis.⁶ Patients having any of the following features of ocular toxoplasmosis like fresh retinitis patch, retinochoroiditis, retinal vasculitis, neuroretinitis, papillitis, punctuate outer retinal toxoplasmosis, dense vitritis, scleritis or retinal vascular occlusions with vasculitis were included in the atypical presentation.⁶ Both presentations of ocular toxoplasmosis were tested for IgM and IgG toxoplasma antibody levels in serum by ELISA (enzyme-linked immunosorbent assay) technique [Toxo IgG 96T-Diatek]. Serology was done at presentation and repeated after 3 weeks. Those patients tested positive for IgM and/or having positive and persistently elevated levels of IgG were inducted in the study. Patients with negative IgG toxoplasma antibodies were taken as not having ocular toxoplasmosis and were excluded from the study. Patients presented with typical toxoplasmic retinochoroiditis constituted Group A whereas those with atypical presentations formed Group

B. The control Group C consisted of patients presenting with known uveitic entities other than toxoplasma. The serum immunoglobulin levels of all patients were compared and statistically analyzed. The proportion of atypical presentation among total toxoplasma cases and the distribution of atypical cases were calculated.

Fisher's exact test was used to compare the gender and One-way ANOVA to compare the age between the groups. Kruskal-wallis test and One-way ANOVA were used to compare the IgG levels of cases and controls. Statistical analyses were conducted using SPSS Version 20.0 for Windows (IBM Corporation ARMONK, NY, USA).

RESULTS

Fifty-nine patients were included in the study of which thirty-five patients were having features suggestive of ocular toxoplasmosis. Among the cases (n=35) in our study thirteen patients had typical presentation of a retinochoroidal focus with an adjacent scar (37.1%), and twenty-two patients had atypical presentation (62.9%) of toxoplasma. All the patients in groups A and B showed moderate to severe vitritis indicating that all cases had disease activity. The control group consisted of twenty-four patients presenting with non toxoplasmic uveitis.

Mean age and distribution of gender in all the groups were comparable ($p>0.05$) (Table 1).

Various types of presentations in atypical cases were retinitis patch without an adjacent scar (31.8%), intermediate uveitis (27.3%), papillitis (22.7%) retinal vasculitis and dense vitritis (9.09% each) (Figure 1).

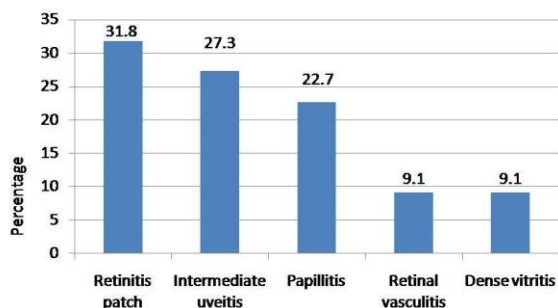
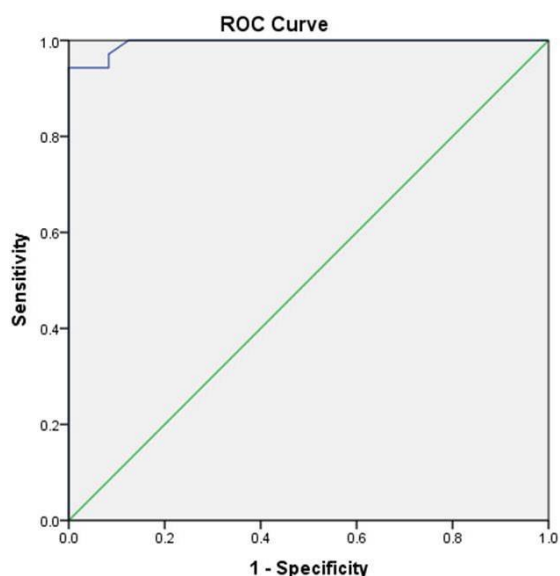
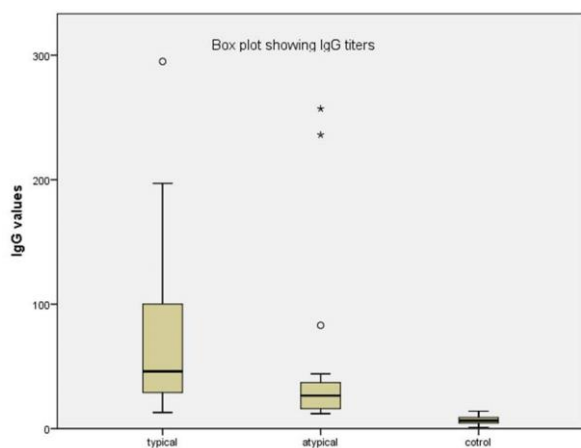
Only one patient (7.69%) in Group A presented with a high IgM titer whereas five patients (22.72%) in Group B were found positive for IgM indicating a primary ocular infection in the recent past. The mean serum IgG levels among the three groups were compared. Mean IgG levels in Group A was 85.3 ± 82.9 international units (IU/ml) (n=13), mean value of Group B was 47.5 ± 66.2 IU/ml (n=22) and Group C had a mean IgG value of 6.6 ± 3.4 IU/ml (n=24). Statistical analysis showed a significant association between high levels of serum toxoplasma IgG titers in various clinical presentations of ocular toxoplasmosis when compared to controls ($p<0.001$) (Table 2).

Table 1: Demographic data.

Variables	Typical	Atypical	Control	P value
Age (mean\pmSD)	40.2 \pm 15.7	40.6 \pm 14.1	41.4 \pm 20.9	0.976
Gender, N (%)				
Female	5 (38.5)	15 (68.2)	13 (54.2)	0.259
Male	8 (61.5)	7 (31.8)	11 (45.8)	

Table 2: Comparison of IgG values.

IgG values	Typical	Atypical	Control	P value
Mean±SD	85.3±82.9	47.5±66.2	6.6±3.4	<0.001
Median (min-max)	45.8 (13.2-295.4)	26.5 (12.4-256.8)	6.3 (1.3-18.7)	

**Figure 1: Atypical presentations.****Figure 2: ROC curve.****Figure 3: Boxplot.**

Only 3 patients from the control group showed high IgG titers (false positives). While comparing mean values between typical versus atypical cases of toxoplasmosis it was found that Group A had significantly higher serum IgG values compared to Group B patients ($p=0.03$). Similar results were observed when the data of serum toxoplasma IgG titers was analyzed using median values as well.

To find out the cut off level of serum IgG values with maximum sensitivity and specificity, ROC curve was plotted (Figure 2). Based on these data, the ELISA test showed a sensitivity of 97.1% and a specificity of 91.7% at cut off value of 12.5 IU/l.

Figure 3 is the boxplot showing the comparison of ELISA titers for toxoplasmic antibodies (IgG) in patients with typical and atypical clinical presentations of ocular toxoplasmosis and the control group.

DISCUSSION

The diagnosis of ocular toxoplasmosis is based on the typical clinical presentation. When the clinical diagnosis cannot be made definitely by ophthalmoscopic examination, serological tests including serum anti-toxoplasma titers of IgM and IgG may be needed to support the diagnosis. Literature review shows that the role of toxoplasmic serology in ocular toxoplasmosis has been underestimated.

Our study showed that in both typical and atypical cases of ocular toxoplasmosis serology could be rewarding. In the present study we have observed that serum IgG levels are significantly elevated in both typical and atypical presentations of ocular toxoplasmosis as compared to cases presenting with non-toxoplasmic uveitis suggesting a potential role of IgG titres in the diagnosis of ocular toxoplasmosis ($p<0.001$).

Study by Papadia et al found that the mean toxoplasmosis IgG levels by ELISA was significantly higher in patients with active chorioretinitis (147.75 IU/ml) compared with patients with other types of uveitis (18.35 IU/ml).⁸ We got a similar result in the statistical analysis. It was observed in our study that the serum IgG levels in atypical toxoplasma cases were significantly lower than that of typical cases ($p=0.03$). It may be due to the higher number of newly acquired infection in the atypical cases with positive IgM titers with low IgG values rather than reactivation of old infection.

Approximately one-third of humans worldwide are estimated to be chronically infected with *T. gondii* and the seroprevalence varies in different populations^{9,10}. In the study by Papadia et al, 48% patients in the control group (false positives) had elevated IgG titers.⁸ Our study showed only three out of twenty four patients had positive serology in the control group (8.33%) indicating that the seroprevalence may be low in our population. This adds to the significance of testing serum antibody titers in our patients presenting with a clinical picture compatible with ocular toxoplasmosis.

Based on the results from our study, the ELISA test for serum IgG levels showed a sensitivity of 97.1% and a specificity of 91.7% at cut off value of 12.5 IU/L. There was not much overlap between the mean titers of patients with ocular toxoplasmosis and non-toxoplasmic uveitis patients in our study (Figure 3). So, it can be inferred that serology is a useful tool in the diagnosis of ocular toxoplasmosis compatible with a clinical picture of ocular toxoplasmosis both in typical and atypical cases.

In our study we got a significant proportion of atypical presentations of toxoplasmosis (62.9%). They formed fresh retinitis patch, papillitis, intermediate uveitis and dense vitritis. This is in concordance with the recent studies that the proportion of acquired cases with atypical presentations is on the rise even in the healthy population.

There are some limitations to our study. Although the ELISA detection method we used is one of the most common commercially available methods, there are several other methods in clinical use. Because there is variability between results from different ELISA kits, our results may not be directly comparable to those using different methods.

CONCLUSION

Serology is a useful tool in the diagnosis of ocular toxoplasmosis with a compatible clinical picture as serum IgG levels are significantly elevated in both typical and atypical presentations of ocular toxoplasmosis as compared to cases presenting with non-toxoplasmic uveitis.

Funding: No funding sources

Conflict of interest: None declared

Ethical approval: The study was approved by the Institutional Ethics Committee (SBMR-IRC: P/03/2014 dated 01.04.2014)

REFERENCES

1. Furtado JM, Winthrop KL, Butler NJ, Smith JR. Ocular toxoplasmosis. I. Parasitology epidemiology and public health. *Clin Exp Ophthalmol*. 2013;41:82–94.
2. Hollad GN. Ocular toxoplasmosis: a global reassessment. Part 1: epidemiology and course of disease. *Am J Ophthalmol*. 2003;136:973-88.
3. Glasner PD, Silveira C, Kruszon-Moran D, Martins MC, Júnior MB, Silveira S, et al. An unusually high prevalence of ocular toxoplasmosis in southern Brazil. *Am J Ophthalmol*. 1992;114:136–44.
4. Holland GN. Ocular toxoplasmosis: new directions for clinical investigation. *Ocul Immunol Inflamm*. 2000;8:1–7.
5. Atmaca LS, Simsek T, Batioglu F. Clinical features and prognosis in ocular toxoplasmosis. *Jpn J Ophthalmol*. 2004;48:386–91.
6. Smith JR, Cunningham ET. Atypical presentations of ocular toxoplasmosis. *Curr Opin Ophthalmol*. 2002;13:387-92.
7. Montoya JG, Liesenfeld O. Toxoplasmosis. *Lancet*. 2004;363:1965–76.
8. Papadia M, Aldigeri R, Herbolt CP. The role of serology in active ocular toxoplasmosis. *Int Ophthalmol*. 2011;31:461–5.
9. Subauste CS, Ajzenberg D, Kijlstra A. Review of the series 'Disease of the year 2011: toxoplasmosis' pathophysiology of toxoplasmosis. *Ocul Immunol Inflamm*. 2011;19:297–306.
10. Tenter AM, Heckeroth AR, Weiss LM. *Toxoplasma gondii*: from animals to humans. *Int J Parasitol*. 2000;30:1217–58.

Cite this article as: Krishnankutty SV, Philip R, Narayani V. Usefulness of serology in diagnosis of different clinical presentations of ocular toxoplasmosis. *Int J Community Med Public Health* 2020;7:517-20.