ORIGINAL RESEARCH

Role of trabecular bone in visibility of laminadura: A cross-sectional radiographic study

Rajesh Singh T, Sanjeev Jindal[1], Anshu Singla[2], Vinod Kumar AR[3], Ajit Damera[3]

Department of Oral Medicine and Radiology, Qassim University Dental College, Buraydah, Saudi Arabia, [1]Departments of Oral Medicine and Radiology and [2]Pedodontics and Preventive Dentistry, Gian Sagar Dental College and Hospital, Rajpura, Punjab, [3]Department of Oral Medicine and Radiology, Gitam Dental College and Hospital, Visakhapatnam, Andhra Pradesh, India

Received : 09-01-14
Review completed : 01-02-14
Accepted : 29-06-15

ABSTRACT

Aim: To determine the degree to which trabecular bone contributes to the radiographic visibility of laminadura (LD).

Study Design: Human dry mandibles were obtained, and a series of radiographs were acquired in the premolar region. Radiographs taken were: (1) Before removal of any bone, (2) After removal of small amount of cortical bone at the apex of tooth, (3) Removal of trabecular bone, (4) Smoothing of endosteal surface of cortical bone. The radiographs were projected to a panel of six oral radiologists, and they were asked to judge the visibility of LD.

Results: Chi-square analysis revealed a significant radiographic difference between radiographs made initially and after removal of trabecular bone, cortical bone and smoothing the endosteal surface of cortical bone.

Conclusion: There was statistically significant difference in the visibility of loss of LD when trabecular bone is lost. LD can be visible only if the endosteal surface of the cortical bone and trabecular bone is intact.

Key words: Cortical bone, intraoral periapical radiograph, laminadura, trabecular bone

The clinical significance and connotation of laminadura (LD) has been long controversial and continued to be an enigma till date. Though the literature supports it to be a healthy structural component of the teeth, many oppose it.[1] In fact, LD is considered to be an important landmark which differentiates normal tooth structure from that of a diseased condition.[2] The presence of intact LD around the apex of the root strongly implicates it to be a vital tooth.

Radiographically LD is considered to be a radio-opaque line around a thin bundle bone.[3] It is markedly influenced by dental diseases and occlusion. Discontinuity of LD is thought to occur at the beginning of periodontitis and also said to have a direct relationship with occlusal trauma.[4] Often, the first indication of periapical pathosis is discontinuity or loss of LD. This change is illusive and difficult to interpret.[5]

Address for correspondence:
Dr. Sanjeev Jindal
E-mail: jindal2003@yahoo.com

Access this article online	
Quick Response Code:	Website: www.ijdr.in
	DOI: 10.4103/0970-9290.162892

Intraoral periapical radiographs (IOPAR) is now considered to be a third eye to the clinician in diagnosing various diseases as it provides the wealth of information regarding teeth and surrounding bone. Radiographic interpretation is considered to be inconsistent with a wide variation between observers. The trabecular bone plays an important role in the radiographic appearance of the LD and plays a pivotal role in depicting the periapical pathosis.[6]

Hence, the objective of this study was to evaluate the degree of trabecular bone contributing to the visibility of the LD.

MATERIALS AND METHODS

Ten dentate mandibular segments from different dry mandibles between the age group of 20–60 years were obtained from Department of Anatomy. The surface was examined closely for defects that might be of radiological significance. The specimen were radiographed using IOPAR machine (New Life X-ray Unit, Germany) in premolar region using Carestream (Kodak) Intraoral E-Speed size 2 film to rule out the presence of any systemic or local disease.

The radiographic images were made of each segment with lingual cortex towards the film before removal of any bone [Figure 1], after removal of small amount of cortical bone by using a dental bur at the apical region of premolar tooth [Figure 2], after removal of trabecular bone [Figure 3]

after smoothing endosteal surface of cortical bone [Figure 4], this resulted in 40 radiographs. All exposures of the film were made at 8 mA, 70 kVp, 1 s, with a constant distance of 64 cm from the source to film. The specimens were placed directly on the film packet. The fixed geometry and placement of film and specimen allowed the making of a radiograph that was identical. The radiographs for each segment were processed in an automatic processor, labeled, sorted and projected to a panel of six dentists. The observers were blinded about the procedures that had been carried out on the specimen, they were asked to judge whether LD is visible in the entire radiograph [Table 1] and to appreciate significant differences in visibility of LD after each step of bone removal [Table 2]. Chi-square analysis was used to determine whether differences in the LD were seen initially, after removal of the cortical bone, after removal of trabecular bone and after smoothing endosteal surface of cortical bone.

RESULTS

Recording the single-blinded individual findings of six experienced oral radiologists ensured unprejudiced interpretation. The data obtained from the six observers were tabulated in a master chart to compare the visibility and similarity of the radiographic appearance of LD.

Analysis of observations, of different observers before removal of bone, depicts an average appreciation of LD to be >90% (55 of 60) with $P = 0.210$. After the removal of small amount of cortical bone at the apex of selected tooth, the average appreciation is 80% (45 of 60) with $P = 0.180$ [Table 1]. After removal of trabecular bone the appreciation of cortical bone is 60% (38 of 60) with $P < 0.001^{**}$ and after smoothing endosteal surface of cortical bone the appreciation of LD by observers was reduced to 37% (19 of 60) with $P = 0.002^{**}$. P value was significant when small amount of cortical bone at the apex of selected tooth was removed, moderately significant after removal of trabecular bone and strongly significant after smoothing of the endosteal surface of cortical bone [Table 2].

Based on the above values, it can be inferred that the variation in the visibility of LD observed by all the experts

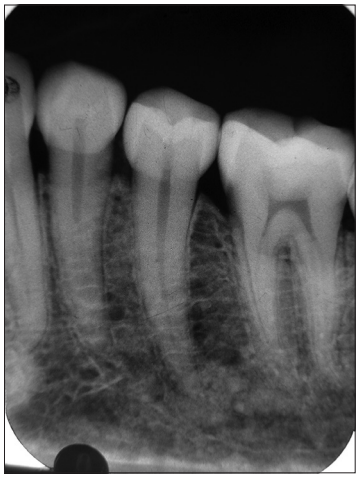

Figure 1: Before removal of any bone

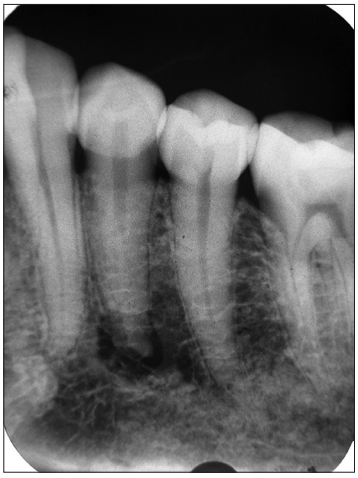

Figure 2: After removal of small amount of cortical bone by using a dental bur at the apical region of premolar tooth

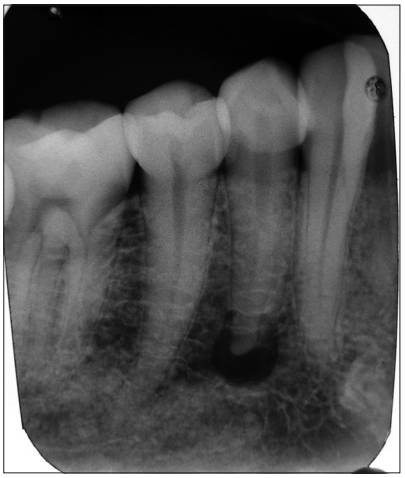

Figure 3: After removal of trabecular bone

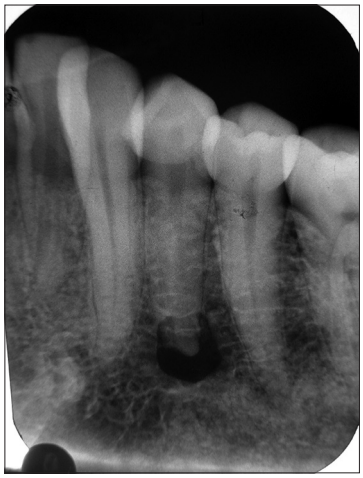

Figure 4: After smoothing endosteal surface of cortical bone

Table 1: Evaluation of radiographs for visibility of LD

Parameters	Observers 1 (%)	Observers 2 (%)	Observers 3 (%)	Observers 4 (%)	Observers 5 (%)	Observers 6 (%)
Step A: Before removal of bone						
Yes	9 (90.0)	9 (90.0)	9 (90.0)	10 (100.0)	9 (90.0)	9 (90.0)
No	1 (10.0)	1 (10.0)	1 (10.0)	0	1 (10.0)	1 (10.0)
Step B: After removal of small amount of cortical bone at apex of selected tooth						
Yes	8 (80.0)	8 (80.0)	9 (90.0)	8 (80.0)	9 (90.0)	8 (80.0)
No	2 (20.0)	2 (20.0)	1 (10.0)	2 (20.0)	1 (10.0)	2 (20.0)
Step C: After removal of trabecular Bone						
Yes	6 (60.0)	6 (60.0)	7 (70.0)	6 (60.0)	7 (70.0)	6 (60.0)
No	4 (40.0)	4 (40.0)	3 (30.0)	4 (40.0)	3 (30.0)	4 (40.0)
Step D: After smoothing endosteal surface of cortical bone						
Yes	2 (20.0)	4 (40.0)	3 (30.0)	4 (40.0)	6 (60.0)	0
No	8 (80.0)	6 (60.0)	7 (70.0)	6 (60.0)	4 (40.0)	10 (100.0)

Variables-an observation (n=10). LD=Laminadura

Table 2: Evaluation of radiographs for difference of visibility of LD

Parameters	Observers 1 (%)	Observers 2 (%)	Observers 3 (%)	Observers 4 (%)	Observers 5 (%)	Observers 6 (%)
Step A: Before removal of bone						
Not observed	1 (10.0)	1 (10.0)	1 (10.0)	0	1 (10.0)	1 (10.0)
Partially observed	5 (50.0)	5 (50.0)	4 (40.0)	1 (10.0)	4 (40.0)	1 (10.0)
Well observed	4 (40.0)	4 (40.0)	5 (50.0)	9 (90.0)	5 (50.0)	8 (80.0)
Step B: After removal of cortical bone at the apex of selected tooth						
Not observed	2 (20.0)	2 (20.0)	1 (10.0)	2 (20.0)	4 (40.0)	1 (10.0)
Partially observed	8 (80.0)	8 (80.0)	7 (70.0)	8 (80.0)	5 (50.0)	8 (80.0)
Well observed	0	0	2 (20.0)	0	1 (10.0)	1 (10.0)
Step C: After removal of trabecular bone						
Not observed	6 (60.0)	6 (60.0)	6 (60.0)	6 (60.0)	3 (30.0)	6 (60.0)
Partially observed	4 (40.0)	2 (20.0)	1 (10.0)	2 (20.0)	6 (60.0)	4 (40.0)
Well observed	0	2 (20.0)	3 (30.0)	2 (20.0)	1 (10.0)	0
Step D: After smoothing endosteal surface of cortical bone						
Not observed	8 (80.0)	6 (60.0)	7 (70.0)	6 (60.0)	4 (40.0)	10 (100.0)
Partially observed	2 (20.0)	3 (30.0)	1 (10.0)	3 (30.0)	5 (50.0)	0
Well observed	0	1 (10.0)	2 (20.0)	1 (10.0)	1 (10.0)	0

An observation (n=10). LD=Laminadura, ICC=Intra class correlation, Kappa=Kappa agreement

are significantly consistent when the more trabecular bone was present. As the trabecular bone was removed, the ability of the observers to identify the images were gradually decreased ($P < 0.001$)** [Table 3].

DISCUSSION

The absence of LD is diagnostic of pathology. Ritchey and Orban in 1943 thought the LD indicates changes in periodontal health.[7] Manson 1963 concluded that LD about teeth could be radiographic artifact, a tangential bony radiopacity of no clinical significance and inconsistent with disease, trauma or health, also suggested that, bone of the socket wall had the same mineral content by mass as the adjacent bone, he believed that there is no evidence of special bone with higher mineral content.[8] In 1981, Greenstein *et al.* thought the LD was related to the presence or absence of clinical inflammation.[9] In 1994 Rams *et al.* said that crestal LD could be used in predicting periodontal health or disease activity.[10] Socket or crestal LD are also attributed to the physiologic trabecular bone response to trauma or periodontal health and are used as a potential diagnostic tool for such systemic diseases.[11]

A study did confirm the image of LD would disappear when the alveolar bone proper is removed.[12] A similar study suggested that both the alveolar bone proper and some adjacent trabecular bone had to be removed to detect a difference in radiographic LD image.[13] This study was conducted with an aim to address these shortfalls and to arrive at a conclusion whether a trabecular bone is contributing to the radiographic visibility of LD. Bender has explained that if the mineral content per unit volume of the tissue is low, for instance in cancellous bone, a large volume of tissue needs to be destroyed before radiographic changes can be seen.[14]

In this study as the bone is removed from the buccal side of the mandible the visibility of LD is reduced. This implies that both cortical and trabecular is contributing to the visibility

Table 3: Evaluation of radiographs for LD variables by six observers: A statistical analysis

Statistical analysis	Step A: Before removal of bone	Step B: After removal of LD at the apex of selected tooth	Step C: After removal of trabecular bone	Step D: After smoothing endosteal surface of cortical bone
Kappa (k)	0.433	0.328	0.538	0.399
SE (k)	0.398	0.245	0.089	0.130
Z	1.088	1.339	6.068	3.062
P	0.210	0.180	<0.001**	<0.002**
ICC	0.461	0.359	0.568	0.431
95% CI (ICC)	0.21-0.77	0.12-0.70	0.31-0.83	0.18-0.75

LD=Laminadura, ICC=Intra class correlation, Kappa=Kappa agreement, SE=Standard error, CI=Confidence interval, **=Significant

of LD. This finding is in coherence with the results of similar studies conducted previously.[13]

CONCLUSION

The appearance of LD is a valuable radiographic feature. It is a functional state a freckle and friable indicator of health and disease. It should neither be relied upon too heavily nor ignored since it is an integral part of the tooth. It just requires understanding the appearance of LD in diagnosing various oral diseases. It is clearly evident in this study that trabecular and cortical bone should be intact for the visibility of LD.

REFERENCES

1. Hubar JS. Quantification of the lamina dura. J Can Dent Assoc 1993;59:997-1000.
2. Yamaoka M, Ishizuka M, Takahashi M, Uematsu T, Furusawa K. Bone formation with disruption of the lamina dura in the mandibular third molar. Clin Cosmet Investig Dent 2010;2:1-3.
3. Yokota ET, Miles DA, Newton CW, Brown CE Jr. Interpretation of periapical lesions using RadioVisioGraphy. J Endod 1994;20:490-4.
4. Colosi D, Potluri A, Islam S, Geha H, Lurie A. Brief communication: Bone trabeculae are visible on periapical images. Oral Surg Oral Med Oral Pathol Oral Radiol Endod 2003;96:772-3.
5. Couture RA, Whiting BR, Hildebolt CF, Dixon DA. Visibility of trabecular structures in oral radiographs. Oral Surg Oral Med Oral Pathol Oral Radiol Endod 2003;96:764-71.
6. Yamaoka M, Takahashi M, Ishihama K, Uematsu T, Furusawa K. Age-related disruption of the lamina dura: Evidence in the mandibular horizontal incompletely impacted third molar. Clin Interv Aging 2009;4:451-6.
7. Ritchey B, Orban B. The crests of the interdental alveolar septa. J Periodontol 1953;24:75-87.
8. Manson JD. The lamina dura. Oral Surg Oral Med Oral Pathol 1963;16:432-7.
9. Greenstein G, Polson A, Iker H, Meitner S. Associations between crestal lamina dura and periodontal status. J Periodontol 1981;52:362-6.
10. Rams TE, Listgarten MA, Slots J. Utility of radiographic crestal lamina dura for predicting periodontitis disease-activity. J Clin Periodontol 1994;21:571-6.
11. Kaffee I, Tamse A, Scheartz Y, Buchner A, Littner MM. Changes in the lamina dura as a manifestation of systemic diseases: Report of a case and review of the literature. J Endod 1982;8:467-70.
12. Barbat J, Messer HH. Detectability of artificial periapical lesions using direct digital and conventional radiography. J Endod 1998;24:837-42.
13. Cavalcanti MG, Ruprecht A, Johnson WT, Southard TE, Jakobsen J. The contribution of trabecular bone to the visibility of the lamina dura: An *in vitro* radiographic study. Oral Surg Oral Med Oral Pathol Oral Radiol Endod 2002;93:118-22.
14. Bender IB. Factors influencing the radiographic appearance of bony lesions. J Endod 1982;8:161-70.

How to cite this article: Singh TR, Jindal S, Singla A, Vinod Kumar AR, Damera A. Role of trabecular bone in visibility of laminadura: A cross-sectional radiographic study. Indian J Dent Res 2015;26:280-3.

Source of Support: Nil, **Conflict of Interest:** None declared.