

Tuberculosis with atypical manifestations involving multiple sites of the oral cavity: A case study

Sir,

Oral tuberculosis is rarely observed; only 0.05–1.5% of tuberculosis cases present with oral manifestations.^[1] Oral tuberculous lesions are characterized by atypical or persistent ulcers and are often misdiagnosed as malignancy, deep mycotic infection, syphilis and traumatic or aphthous ulcers.^[2,3] Ulcers often appear as single lesions.^[2]

A 52-year-old man with multiple oral ulcers visited our clinic in November 2014. While the initial lesion had developed 8 months earlier, there had been rapid progression of disease with multiple new ulcers over the previous 2 months. At presentation, he had a 2.5 cm × 1 cm sized irregular ulcer involving the buccal gingiva of the upper right second premolar and first and second molars with mild tenderness of the underlying bony surface at the ulcer base. The root of the upper right first molar was exposed with resorption of the underlying alveolar bone [Figure 1a]. Soft tissue defects, 2 and 5 mm in diameter, and extending as deep as the underlying bone were noted on the labial gingiva of the upper left lateral incisor and the palatal mucosa adjoining the upper left first molar, respectively [Figure 1b and 1c]. In addition, a 13-mm shallow erosion was noticed on the right hard palate [Figure 1d]. Shallow ulcers were present on the buccal gingival margin of the mandible adjacent to the lower right first and second molars [Figure 1e].

Eight months earlier, our patient's initial single gingival erosion located posteriorly in the right maxilla was diagnosed as osteoradionecrosis at a local hospital. Oral amoxicillin administered for 14 days was ineffective. Later, when multiple oral lesions appeared, there was difficulty in eating and speaking owing to pain. The patient also experienced considerable weight loss (approximately 10 kg), recurrent fever, as well as a decline in overall health. Medical histories included chemoradiotherapy for nasopharyngeal carcinoma 10 years previously and cure of chest cutaneous tuberculosis 8 years previously with standard treatment. In addition, he denied any family history of tuberculosis.

One month back, the patient had undergone a routine blood test that showed a normal complete blood count, blood glucose levels and liver and kidney functions. Laboratory investigations for human immunodeficiency virus and syphilis were negative; the tuberculosis-antibody assay was positive, purified protein derivative tuberculin skin test was negative and tuberculosis-interferon gamma release assay was positive (125.47; reference range: 0–14).

Computed tomography revealed right-sided partial maxillary alveolar resorption and swelling of the surrounding soft tissue. Chest radiography showed miliary nodular opacities in both the lungs. A biopsy taken from the maxillary right first molar vestibular groove revealed granulomatous inflammation suggesting the possibility of tuberculosis. Several acid-fast bacilli were identified on Ziehl–Nielsen staining [Figure 2]. DNA fragments of *Mycobacterium tuberculosis* were found on quantitative real-time polymerase chain reaction.

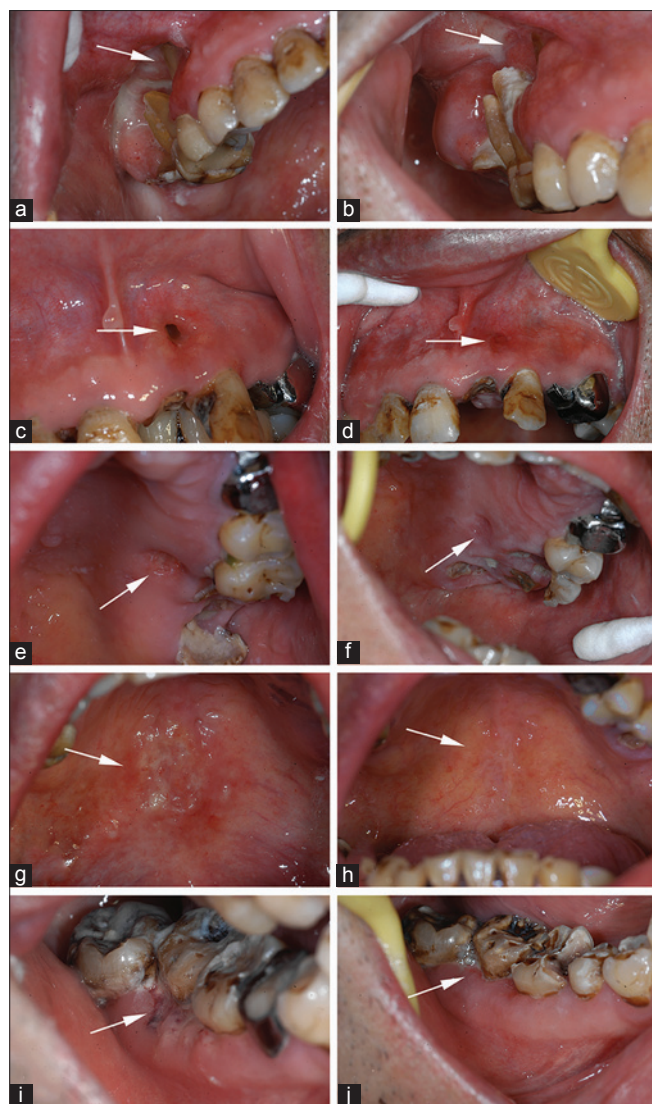


Figure 1: (a) A 2.5 cm × 1 cm sized irregular ulcer involving the buccal gingiva of the upper right second premolar and first and second molars. The root of the upper right first molar was exposed with resorption of the underlying alveolar bone. (b) A 2 mm soft tissue defect on the labial gingiva of the upper left lateral incisor extending to the surface of the underlying bone. (c) A 5 mm soft tissue defect on the palatal mucosa adjoining the upper left first molar extending to the surface of the underlying bone. (d) A 13-mm shallow erosion on the right hard palate. (e) Shallow ulcers on the buccal gingival margin of the mandible adjacent to the lower right first and second molars. (f-j) Healing of the lesions

A diagnosis of osteoradionecrosis was not considered given the total lack of response to antibiotics and failure to detect any sequestrum on computed tomography of the jaw. As a false-negative tuberculin skin test is found in approximately 28% of tuberculosis patients, this could explain our patient's negative result.^[2]

Although the oral lesions were diverse and atypical, when clinical, laboratory and histopathological

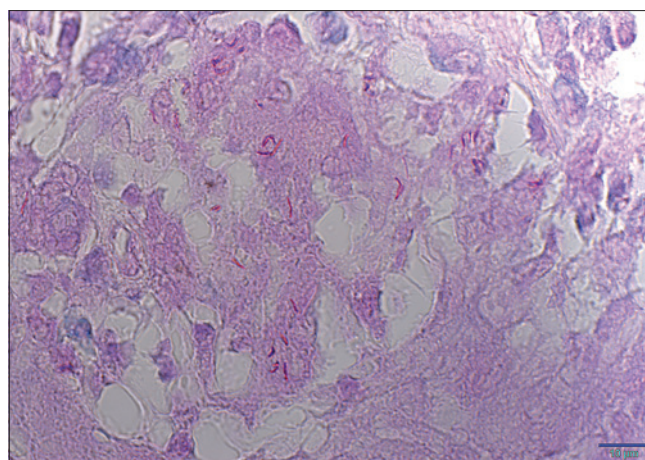


Figure 2: Oral biopsy demonstrating acid-fast bacilli (Ziehl-Nielsen staining, ×200)

findings were considered together, they were most suggestive of oral tuberculosis.

The patient achieved clinical remission 3 months after initiation of anti-tubercular therapy; healing of all the ulcerative perforative lesions [Figure 1f-j] confirmed our diagnosis.

Shallow gingival ulcers, deep necrotic gingival ulcers with damaged alveolar bone, soft tissue defects in the gingiva and hard palate with exposure of the bone surface, and irregular palatal erosions occurred simultaneously; perforation of soft tissue at two locations (the gingiva and hard palate) has been rarely reported previously because the involvement of the alveolar bone in tuberculosis is rare.^[4] The most common site of oral tuberculosis is the tongue while the hard palate is the least common site of infection.^[2,5] Our patient's unusual presentation with multiple ulcers mainly involving the gingiva and hard palate, sites rarely affected by tuberculosis, made diagnosis difficult.

Financial support and sponsorship

National Natural Science Foundation of China (81472533); Nonprofit Industry Research Specific Fund of National Health and Family Planning Commission of China (201502018).

Conflicts of interest

There are no conflicts of interest.

Xuefeng Zhang, Jiongke Wang, Yuanqin Wu, Lu Jiang, Yu Zhou, Qianming Chen, Xin Zeng

Department of Oral Medicine, West China Hospital of Stomatology, Sichuan University, Chengdu, Sichuan 610041, P. R. China

Address for correspondence: Prof. Xin Zeng,
Sichuan University, No. 14, 3rd Section,
Ren Min Nan Road, Chengdu,
Sichuan 610041, P. R. China.
E-mail: zengxin22@163.com

REFERENCES

1. Ito FA, de Andrade CR, Vargas PA, Jorge J, Lopes MA. Primary tuberculosis of the oral cavity. *Oral Dis* 2005;11:50-3.
2. Kakisi OK, Kechagia AS, Kakisis IK, Rafailidis PI, Falagas ME. Tuberculosis of the oral cavity: A systematic review. *Eur J Oral Sci* 2010;118:103-9.
3. Mignogna MD, Muzio LL, Favia G, Ruoppo E, Sammartino G, Zarrelli C, *et al.* Oral tuberculosis: A clinical evaluation of 42 cases. *Oral Dis* 2000;6:25-30.
4. Alawi F. An update on granulomatous diseases of the oral tissues. *Dent Clin North Am* 2013;57:657-71.
5. Kumar V, Singh AP, Meher R, Raj A. Primary tuberculosis of oral cavity: A rare entity revisited. *Indian J Pediatr* 2011;78:354-6.

This is an open access article distributed under the terms of the Creative Commons Attribution-NonCommercial-ShareAlike 3.0 License, which allows others to remix, tweak, and build upon the work non-commercially, as long as the author is credited and the new creations are licensed under the identical terms.

| Access this article online | |
|--|--|
| Quick Response Code: | Website: www.ijdv.com |
|  | DOI: 10.4103/0378-6323.184200 |
| | |

How to cite this article: Zhang X, Wang J, Wu Y, Jiang L, Zhou Y, Chen Q, *et al.* Tuberculosis with atypical manifestations involving multiple sites of the oral cavity: A case study. *Indian J Dermatol Venereol Leprol* 2017;83:116-8.
Received: August, 2015. **Accepted:** December, 2015.

