

# MORPHOLOGICAL STUDY OF PONTICULI IN ADULT HUMAN ATLAS VERTEBRAE

Dakshayani. K.R <sup>\*1</sup>, Rajapur. Parashuram <sup>2</sup>.

<sup>1</sup> Professor and HOD, Department of Anatomy, Mysore Medical College and Research Institute, Mysuru, Karnataka, India.

<sup>2</sup> Associate professor, Department of Anatomy, Mysore Medical College and Research Institute, Mysuru, Karnataka, India.

## ABSTRACT

**Introduction:** The atlas, the first cervical vertebra, supports the head. It is unique in that it fails to incorporate a centrum. Because it supports the skull, it was named after Atlas who, according to Greek mythology, supported the earth on his shoulders. Frequently bony spurs arise from the anterior and posterior margins of the groove for the vertebral artery. These are sometimes referred to as Ponticles, and they occasionally convert the groove into a foramen. More often the foramen is incomplete superiorly. Arcuate foramen also known as ponticulus posticus (Latin for "little posterior bridge").

**Aims and Objectives:** To study the proportion and various types of ponticuli.

**Materials and methods:** Present study was conducted on 100 adult human atlas vertebrae, collected from the department of Anatomy, Mysore Medical College and Research Institute, Mysuru.

**Observations and Results:** Out of 100 atlas vertebrae examined, 20 atlas vertebrae showed ponticuli of various types. 27 Ponticuli was observed in twenty (20) atlas vertebra as follows: a) Ponticulus posticus -15. b) Ponticulus lateralis -07. c) Ponticulus posterolateral -05. d) Complete Ponticulus -11. e) Incomplete Ponticulus -16. e) Bilateral Ponticulus -07. f) Unilateral Ponticulus -13. g) Right side -17 and Left side -10.

**Conclusion:** Proper identification of this anomaly on preoperative lateral radiographs should alert the surgeon to avoid using the ponticulus as a starting point for a lateral mass screw in order to not injure the vertebral artery. It is also useful to surgeons who face regularly the patients complaining about the symptoms of vertebrobasilar insufficiency like headache, vertigo, migraine.

**KEY WORDS:** Atlas Vertebra, Ponticulus, Vertebral Artery, Vertebrobasilar Insufficiency.

**Corresponding Author:** Dr. Dakshayani. K.R, Professor and HOD, Department of Anatomy, Mysore Medical College and Research Institute, Mysuru, Karnataka, India.

**E-Mail:** [dakshayani.kr@gmail.com](mailto:dakshayani.kr@gmail.com); [drparashuram100@yahoo.com](mailto:drparashuram100@yahoo.com)

Access this Article online	Journal Information
<b>Quick Response code</b>  <b>DOI:</b> 10.16965/ijar.2019.366	<b>International Journal of Anatomy and Research</b> ISSN (E) 2321-4287   ISSN (P) 2321-8967 <a href="https://www.ijmhr.org/ijar.htm">https://www.ijmhr.org/ijar.htm</a> DOI-Prefix: <a href="https://dx.doi.org/10.16965/ijar">https://dx.doi.org/10.16965/ijar</a> 
	Article Information
	Received: 11 Dec 2019 Peer Review: 11 Dec 2019 Revised: None
	Accepted: 05 Jan 2020 Published (O): 05 Feb 2020 Published (P): 05 Feb 2020

## INTRODUCTION

The atlas, the first cervical vertebra, supports the head. It is unique in that it fails to incorporate a centrum. Because it supports the skull, it was named after Atlas who, according to Greek mythology, supported the earth on his shoulders. Frequently bony spurs arise from the anterior

and posterior margins of the groove for the vertebral artery. These are sometimes referred to as Ponticles, and they occasionally convert the groove into a foramen. More often the foramen is incomplete superiorly [1].

Arcuate foramen also known as ponticulus posticus (Latin for "little posterior bridge"). It is

a common anatomical variation and estimated to occur in approximately 3-15% of the population [2]. It occurs in females more commonly than males [3].

The ponticulus posticus is created through ossification of the posterior atlanto-occipital ligament. The knowledge of this ponticuli may be of importance to orthopaedic surgeons, neurophysicians, neurosurgeons, otolaryngologists, radiologists, anthropologists, clinical anatomist, forensic experts, morphologists and architects. Thus the present study is carried out to know the proportion and various types of Ponticuli of the atlas vertebra.

**Aims and objectives:** The present study is carried out: 1) To know the Proportion of ponticuli of atlas vertebra and 2) To know the various types of ponticuli: a) Ponticulus posticus b) Ponticulus lateralis c) Ponticulus posterolateral d) Complete and Incomplete Ponticulus e) Bilateral Ponticulus f) Unilateral Ponticulus (right or left side).

## MATERIALS AND METHODS

**source of data:** Present study was conducted on 100 adult human atlas vertebrae, collected from the department of Anatomy, Mysore Medical College and Research Institute, Mysuru, over a period of one year. Fully ossified Atlas was included. Damaged, mutilated, deformed Atlas was excluded. Data was collected by naked eye observation for presence of ponticulus and for various types of ponticulus.

**Study design:** It is a descriptive study.

## OBSERVATIONS AND RESULTS

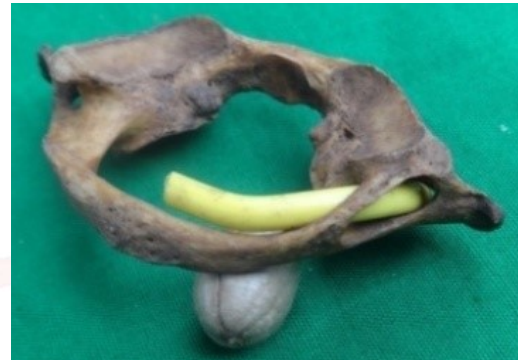**Fig. 1:** Twenty (20) Atlas vertebrae showing ponticuli



**Fig. 2:** Left Ponticulus posticus of atlas vertebra.



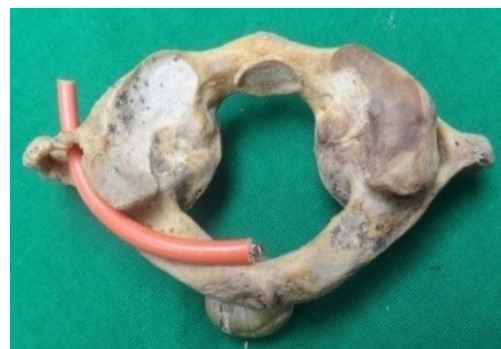**Fig. 3:** Right Ponticulus posticus of atlas vertebra.



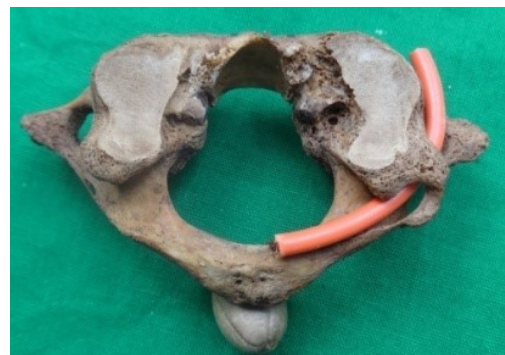**Fig. 4:** Right Ponticulus lateralis of Atlas vertebra.



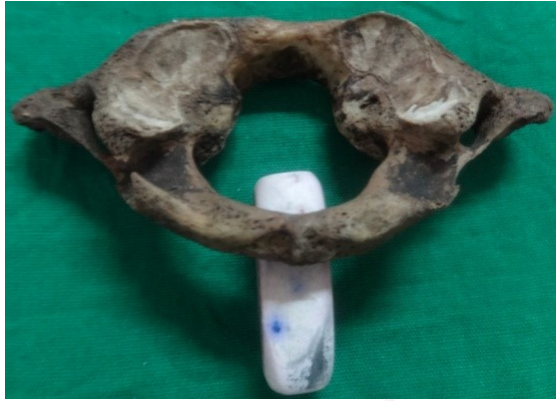**Fig. 5:** Left Ponticulus lateralis of Atlas vertebra.



**Fig. 6:** Right Ponticulus posterolateral of Atlas vertebra.





**Fig. 7:** Left Incomplete Ponticulus of atlas vertebra.**Table 1:** Distribution of Ponticuli of atlas vertebra.

Types	Ponticuli posticus	Ponticuli lateralis	Ponticuli posterolateral
Number of atlas vertebra	15	7	5

**Table 2:** Distribution of Ponticuli of atlas vertebra.

Types	Ponticuli posticus	Ponticuli lateralis	Ponticuli posterolateral
Complete ponticulus	7	3	1
Incomplete ponticulus	8	4	4

**Table 3:** Distribution of Ponticuli of atlas vertebra.

Types	Ponticuli posticus	Ponticuli lateralis	Ponticuli posterolateral
Right ponticulus	10	5	2
Left ponticulus	5	2	3

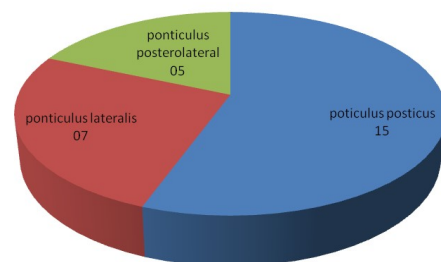
Out of 100 adult human atlas vertebrae examined, 20 atlas vertebrae showed ponticuli of various types. 27 Ponticuli was observed in twenty (20) atlas vertebra: a) Ponticulus posticus -15. b) Ponticulus lateralis - 07. c) Ponticulus posterolateral -05. d) Complete Ponticulus -11. e) Incomplete Ponticulus -16. e) Bilateral Ponticulus -07. f) Unilateral Ponticulus -13. g) Right side -17 & Left side -10.

## DISCUSSION

The present study shows the incidence of presence of ponticulus in 20 adult human atlas vertebra. Based on the literature, the incidence of presence of ponticulus varied in different races. The incidence in our study was close to the Korean 23%, and Indians 3-18% races and much lower than the races like South Africa 10%, Turkish 9.4%, and Japan 9%. In western population it varied from 5.1% - 37.8% [4].

The incidence of ponticulus in present study was 20% which is close to the authors reported like Ojaswini M et al [5] 17.5%, Lalit M. et al [6] 16.66%, and the incidence was higher than the author reported by Rekha BS et al [7] 40%.

The incidence of Ponticulus posticus in the present study was 15% which is close to the authors reported like Kavakli et al [8] 22.10%, Lalit M et al 23.33%, Jawed A et al [9] 21.17%, Radoievic S 23% . 27 Ponticuli was observed in 20 atlas vertebrae in the present study, out of which Ponticuli posticus type was more common (15 in number), Unilateral ponticuli was more common (13), Incomplete ponticuli was more common (16), Right side ponticuli was more common (17). Mitchell J [10] classified Ponticuli into three (3) class: Class 1: groove of

**Proportion of various types of ponticulus****Table 4:** Comparison of various studies on ponticulus of Atlas vertebra.

Sl.no	Authors	Total no of Atlas	Ponticuli posticus	Ponticuli lateralis	Ponticuli posterolateral
1	Taitz. C [11]	627	227 (33%)	26 (3.8%)	09 (1%)
2	Dhaull.U et al [12]	148	41 (27.7%)	5 (3.37%)	15 (11.8%)
3	Hasan et al [13]	350	23 (6.57%)	7 (2%)	4 (1%)
4	Kavakli. A et al [8]	-	22.10%	3.60%	-
5	Paraskevas. G et al	-	34.66%	11.36%	-
6	Lalit. M et al [6]	60	23.33%	8.30%	-
7	Rekha. BS [ 7]	200	62 (31%)	13 (6.5%)	5 (2.5%)
8	Jawed A et al [ 9]	118	21.17%	5.93%	-
9	Present study	100	15 (15%)	07 (7%)	5 (5%)

the vertebral artery. Class 2: vertebral artery groove with incomplete ring. Class 3: vertebral artery groove with complete ring.

The mechanism of formation of these ponticuli is a matter of debate [9]: Hayek's states that posterior ponticuli is derived from the embryonic tissue of the dorsal arch of the proatlas. Roy & sweat opinion is that ponticuli is a genetically inherited bony arch formation & is not calcification of the posterior atlanto-occipital ligament. LeDouble described that pulsation of vertebral artery induced the ossification of the ligament. Tritz & Nathan [11] proposed a hypothesis that the development of the bony ponticuli may be due to external mechanical factors like carrying heavy objects on the head, eg. Laborers. It may due to ossification of the posterior atlanto-occipital ligament.

**Table 5:** Proportion of ponticuli of atlas vertebra in different races [10].

Sl.no	Race	Proportion
1	Western population	5.1% - 37.8%
2	Indian	3%-18%
3	Korean	23%
4	Japan	9%
5	Turkish	9.40%
6	South Africa	10%

## CONCLUSION

In the present study of 100 adult human atlas vertebrae examined, 20 atlas vertebrae showed the presence of ponticuli. Proper identification of this anomaly on preoperative lateral radiographs should alert the surgeon to avoid using the ponticulus as a starting point for a lateral mass screw in order to not injure the vertebral artery. Knowledge of ponticulus is very important for the neurophysicians, neurosurgeons, orthopaedic surgeons & otolaryngologists who face regularly the patients complaining about the symptoms of vertebrobasilar insufficiency like headache, vertigo, migraine, periodic photophobia, shoulder and arm pain. If such anomaly is detected, it must be documented in the patients' health record.

**Conflicts of Interests: None**

## REFERENCES

- [1]. The Anatomical Basis of Clinical Practices, S. Standring, H. Ellis, J. C. Healy, D. Jhonson and A. Williams, Eds.; Churchill Livingstone, New York, NY, USA, 41<sup>st</sup> ed, 2008, pp. 719-720.
- [2]. Cushing KE et al. Tethering of the vertebral artery in the congenital arcuate foramen of the atlas vertebra: a possible cause of vertebral artery dissection in children. *Dev Med Child Neurol*. 2001; 43(7): 491-496.
- [3]. Cakmak O et al. Arcuate foramen and its clinical significance. *Saudi Med J*. 2005; 26(9): 1409-1413.
- [4]. Sharma V, Chaudhary D, Mitra R. Prevalence of ponticulus in Indian orthodontic patients. *Dentomaxillofacial Radiology*. 2010; 39: 277-283.
- [5]. Ojaswini M, Vipul PP, Nagar SK. Ponticulus posticus of the atlas vertebra. *National journal of medical research*. Dec 2011; 1(2): 51-53.
- [6]. Lalit M et al. Incidence of atlas bridges and tunnels: their phylogeny, ontogeny and clinical implications. *Rev Arg de Anat Clin*. 2014; 6(1): 26-34.
- [7]. Rekha BS, Rajeshwari T. Study of ponticuli in human atlas vertebrae. *Journal of evolution of medical and dental sciences* Nov 2013; 2(45): 8849-8855.
- [8]. Kavakli A et al. Variants and deformities of atlas vertebrae in eastern Anatolian people. *Saudi Med J*. 2004; 25(3): 322-325.
- [9]. Jawed A et al. A morphological study of ponticuli of the human atlas vertebrae and its clinical significance. *Int J Anat Res* 2015; 3(4): 1597-1602.
- [10]. Mitchell J. The incidence of the lateral bridge of the atlas vertebra. *J of Anat* 1998b; 193: 283-285.
- [11]. Taitz C, Nathan H. Some observations on the posterior and lateral bridge of the atlas. *Acta Anatomica*. 1986; 127(3): 212-217.
- [12]. Dhall U, Chabra S, Dhall JC. Bilateral asymmetry in bridges and superior articular facets of atlas vertebra. *J Anat Soc. India*. 1993; 42(1): 23-27.
- [13]. Hasan M et al. Posterolateral tunnels and ponticuli in human atlas vertebrae. *J Anat* 2001; 199: 339-343.

### How to cite this article:

Dakshayani. K.R, Rajapur. Parashuram. MORPHOLOGICAL STUDY OF PONTICULI IN ADULT HUMAN ATLAS VERTEBRAE. *Int J Anat Res* 2020;8(1.2):7320-7323. DOI: 10.16965/ijar.2019.366