

Rapidly growing pilomatrixoma on eyebrow

Dear Editor,

Pilomatrixoma, a benign tumor, known to occur in children, is rare in the middle-aged. It is recognized as a diagnostic pitfall not only clinically but also on aspiration cytology. Correct preoperative diagnoses vary from 11 to 50% and misdiagnosis at times leads to unwarranted extensive surgery. Pilomatrixoma should be considered in the differential diagnosis of firm skin nodule on the eyelid or brow in the middle-aged.

A 35-year-old female presented with a small nodule of one week duration, at right eyebrow, allegedly after blunt trauma by the head of her baby. A tiny, mild tender nodule palpable on the right brow was treated for five days with tablet amoxicillin 500 mg three times per day and diclofenac 50 mg twice per day, for the presumed diagnosis of organized hematoma. When she was reviewed one week later the nodule had increased in size. The skin-colored nodule was freely mobile, firm to hard with sharp defined margin. The diagnosis was revised to epidermoid cyst and advice of excision of nodule was refused by patient. She came back after one month as the nodule was enlarging, now measuring 1.5 cm x 1.5 cm and the overlying skin was reddish-brown [Fig. 1]. Excision biopsy confirmed the diagnosis of pilomatrixoma [Figs. 2, 3].

Pilomatrixoma, is a benign, calcifying, cutaneous tumor of children and young adults originating from pluripotential precursors of hair matrix cells. It has bimodal peak presentation in the first and sixth decade although can appear at any age. Although preceding trauma,¹ infection or bite, at the site of occurrence of tumor, has been reported their significance in the pathogenesis of pilomatrixoma is not known. Mutations of the beta-catenin gene were detected in 75% of the pilomatrixomas but the exact role of such mutations remain to be elucidated.² It presents as a firm to hard, well-defined mass adherent to skin but not fixed to underlying tissue. Reddish-brown hue of overlying skin suggests the diagnosis of pilomatrixoma.³ Pilomatrixoma, usually solitary but can be multiple, are most common in the head and neck region and may occur at eyebrow, lids and medial canthus. Multiple or familial pilomatrixoma are associated with myotonic dystrophy, Gardner syndrome, Rubinstein Taybi syndrome, Turner syndrome and Trisomy 9.

It is frequently misdiagnosed as epidermoid cyst, sebaceous cyst, dermoid cyst, foreign body reaction, calcification in lymph node, fat necrosis, pyogenic granuloma, chalazion and keratoacanthoma. Perforating pilomatrixoma may present as draining crusted nodule or ulcer.⁴ Perforating or rapidly growing pilomatrixoma can mimic neoplastic lesion.⁵

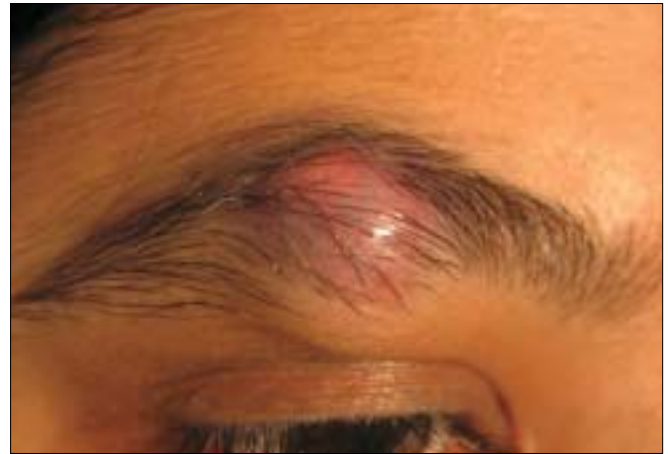

Figure 1: Color photo showing non-inflammatory nodule on right brow with reddish-brown hue of overlying skin

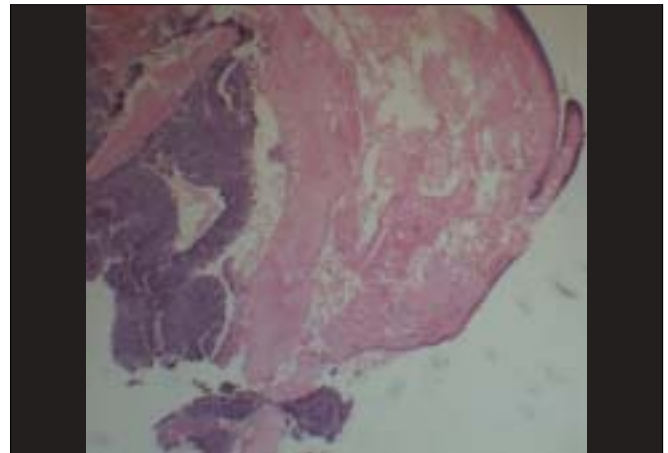


Figure 2: Histological section of nodule showing fibromuscular tissue at one side and sheets of basaloid cells mixed with ghost cells at other side (H/E, 10x)

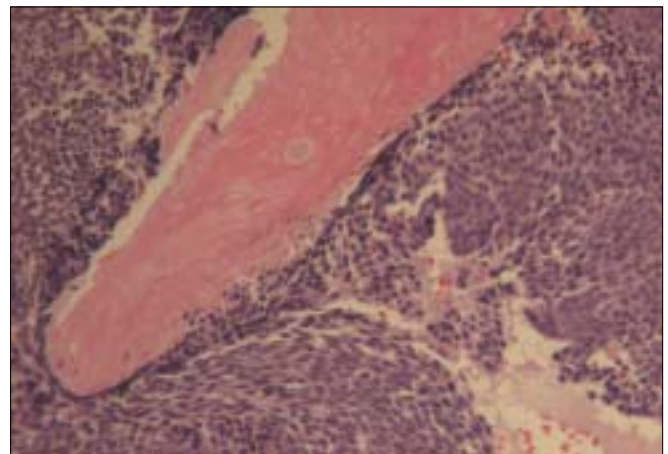


Figure 3: Sheets of basaloid cells mixed with sheets of ghost cells and foci of giant cells formation in higher magnification (H/E, 40x)

On ultrasonography, pilomatrixomas are heterogeneously hyper-echoic with internal echogenic foci and a peripheral hyper-echoic rim or completely echogenic with strong posterior

acoustic shadowing in the subcutaneous layer. On magnetic resonance imaging (T1W1) pilomatrixoma gives homogenous intermediate intensity signal and does not enhance on contrast. Viable basaloid cells in periphery, shadow cells in central part and foci of calcification are characteristic histopathological features of pilomatrixoma. Shadow cells are pathognomonic of pilomatrixoma. Since this doesn't regress spontaneously, excision is the treatment of choice. Surgical excision including clear margins and its overlying skin prevent recurrence in most cases. Although it is exceedingly rare, rapid growth, pain, itching, ulceration and bleeding may suggest malignant transformation of the pilomatrixoma. Malignant variant of pilomatrixoma, pilomatrix carcinoma, is a low-grade malignant lesion with a tendency to recur and carries a risk of distant metastases. Infiltration of surrounding tissue, necrosis, high number of atypical mitotic figures, peri neural or vascular invasion are the typical histological features but no feature is specific to confirm whether a malignant pilomatrixoma has arisen de novo or it is a malignant transformation of a preexisting benign pilomatrixoma.⁶

Pilomatrixoma is often misdiagnosed clinically, but a high index of suspicion and careful examination of its characteristic clinical features can help the clinicians to differentiate it from other tumors.

Sunil Kumar, FRCS, MS

Department of Ophthalmology, Mohammad Dossary Hospital,
PO Box 335, Al Khobar 31952, Saudi Arabia.
E-mail: sunkaru79@hotmail.com

References

1. Mathen LC, Olver JM, Cree IA. A large rapidly growing pilomatrixoma on a lower eye lid. *Br J Ophthalmol* 2000;84:1203-4.
2. Park SW, Suh KS, Wang HY, Kim ST, Sung HS. Beta-Catenin expression in the transitional cell zone of pilomatricoma. *Br J Dermatol* 2001;145:624-9.
3. Yap EY, Hohberger GG, Bartley GB. Pilomatrixoma of the eyelids and eyebrows in children and adolescents. *Ophthal Plast Reconstr Surg* 1999;15:185-9.
4. Niitsuma K, Kuwahara M, Yurugi S, Iioka H. Perforating pilomatricoma on the upper eyelid. *J Craniofac Surg* 2006;17:372-3.
5. Huerva V, Sanchez MC, Asenjo J. Large, rapidly growing pilomatrixoma of the upper eyelid. *Ophthal Plast Reconstr Surg* 2006;22:401-3.
6. Petit T, Grossin M, Lefort E, Lamarche F, Henin D. Pilomatrix carcinoma: Histologic and immunohistochemical features: Two studies. *Ann Pathol* 2003;23:50-4.