Original Article

Validity of 3-Tesla diffusion-weighted magnetic resonance imaging for distinction of reactive and metastatic lymph nodes in head-and-neck carcinoma

ABSTRACT

Objectives: The objective was to study the relationship of 3-Tesla (3T) diffusion-weighted magnetic resonance imaging (DW-MRI) with apparent diffusion coefficient (ADC) value for distinction of reactive and metastatic lymph nodes (LNs) in head-and-neck carcinoma (HNC) patients and to determine the ADC cutoff value for metastatic LNs at various levels.

Materials and Methods: 3T DW and T1- and T2-weighted imaging sequences were done in 34 patients with biopsy-proven primary HNC of 100 cervical LNs ≥1 cm in diameter. The mean ADC values were compared with histopathologically proven LNs using the independent *t*-test. ADC cutoff value was evaluated with sensitivity, specificity, accuracy, positive predictive value, negative predictive value and a receiver operating characteristic curve analysis.

Results: The mean ADC value of reactive LN was 1.2933×10^{-3} mm^2/s and metastatic LN was 0.908×10^{-3} mm^2/s. An ADC cutoff value was 0.868×10^{-3} mm^2/s with 84% sensitivity, 96% specificity, 93% accuracy, 87.5% positive predictive value, and 94.7% negative predictive value. A significant difference in mean ADC value between reactive and metastatic LNs was noted ($P < 0.001$).

Conclusion: 3T DW-MRI is useful in differentiating reactive and metastatic cervical LNs in HNC patients. However, studies with larger sample size have to be performed to validate ADC threshold value with 3T DW-MRI in differentiating between reactive and metastatic LNs for clinical practice.

KEY WORDS: Apparent diffusion coefficient values, cervical nodes, diffusion magnetic resonance imaging, head-and-neck neoplasms

K. Vijayalakshmi, P. H. Raghuram, K. Saravanan[1], C. L. Krithika, A. Kannan

Department of Oral Medicine and Radiology, SRM Dental College, [1]Department of Radio Diagnosis, Sri Balaji Medical College and Hospital, Chennai, Tamil Nadu, India

For correspondence: Dr. K. Saravanan, Department of Radio Diagnosis, Sri Balaji Medical College and Hospital, #7, Works Road, Chrompet, Chennai - 600 044, Tamil Nadu, India. E-mail: drks72@yahoo.com

Submitted: 23-Jan-2019
Revised: 22-Apr-2019
Accepted: 11-Sep-2019
Published: 16-May-2020

INTRODUCTION

Head and neck carcinoma (HNC) is a relatively frequent and the fifth most common cancer in the world till date.[1] During diagnosis, many HNC patients require accurate discrimination of benign versus malignant tissues and identification of the lymph nodes (LNs) which have a major influence on distant metastasis, local recurrence, extent of neck dissection, and prognosis of patient management.[2] Clinical examination allows only direct visualization, which cannot evaluate the extent of disease progression. Imaging in the pretreatment evaluation provides accurate information about the extent and depth of the tumor that can help in deciding the appropriate management strategy and prognosis.

Currently, computed tomography (CT) imaging, magnetic resonance imaging (MRI), positron emission tomography, and ultrasound-guided fine-needle aspiration cytology (FNAC) are the imaging of choice for identifying the head-and-neck lesions and determining the biological activity. Yet, discrimination of benign from malignant lesion is sometimes difficult. Positron emission tomography can be better in discrimination but is unaffordable and does not furnish good imaging resolution. US guided FNAC is invasive and is operator dependent that leads to sampling error with 77% sensitivity.[3] CT imaging relies on volumetric criteria and has low sensitivity when making the diagnosis.[4] MRI is better than CT in discriminating the soft tissue

Cite this article as: Vijayalakshmi K, Raghuram PH, Saravanan K, Krithika CL, Kannan A. Validity of 3-Tesla diffusion-weighted magnetic resonance imaging for distinction of reactive and metastatic lymph nodes in head-and-neck carcinoma. J Can Res Ther 2020;16:587-93.

Access this article online
Website: www.cancerjournal.net
DOI: 10.4103/jcrt.JCRT_55_19
Quick Response Code:

and the extent of head-and-neck tumors. Conventional MRI mainly evaluates morphological properties and is insufficient to characterize the pathological process within the tissue.

Diffusion-weighted MRI (DW-MRI) is a functional imaging technique which was first used in the evaluation of acute stroke, where it relies upon the movement of water molecules and also it is now commonly used in imaging cancer patients.[5] From extracranial to intracranial applications, DW imaging (DWI) has advanced imaging gradient quality and phased array receiver coil providing its clinical value in assessing cancer patients.[6] DWI works on the principle of Brownian movement in which cell surface and tissues in parts of the body with water molecules shows restricted mobility. However, in other parts of the body, water molecules are not restrained. In necrosis and edema due to lack of constituted anatomic structures, restriction of water molecule occurs leading to decreased microstructural density. This displacement of water molecules is quantified by apparent diffusion coefficient (ADC) value, where ADC value is the loss of signal on DWI showing correlation with tissue cellularity[7] and the values are calculated.

Many articles have stated the use of DWI with ADC values[8] in discriminating reactive and metastatic LNs in cancer patients, but there are inconsistent results in measuring ADC values, correlation between technical settings and ADC quantification, and topographic correlation between LNs and MR images.[9] Hence, the novelty of our research was to validate the 3-Tesla (3T) DW-MRI for distinction of cervical metastatic and reactive LNs in HNC patients by standardizing the technical settings, ADC cutoff value, and topographic correlation between DW-MRI and cervical nodes.

MATERIALS AND METHODS

Study group

The study was accepted by the institutional ethical committee, and informed consent was obtained from all the patients. The sample size is calculated with sensitivity based on Dr. Lin Naing method with expected sensitivity 93%, expected prevalence 50%, derived precision 7% and confidence level 95%, thereby achieving sample size of 100 LNs with consecutive sampling techniques which were employed.[10] Thirty-four biopsy-proven primary HNC patients underwent 3T MRI. Treated patients were excluded. One hundred LNs from these patients were collected. The final histopathological diagnosis of LNs derived from neck dissection was made according to standard laboratory procedures. The mean age of patients was 51.02 years (40–70 years), of which 27 were male and 7 were female.

Magnetic resonance imaging protocol

All MRI examinations were performed with a 3T MR scanner (Siemens Spectra 3T) with 16-channel head-and-neck coil. Patients were asked to lie in supine position. Turbo spin echo (TSE) and DW echo planar imaging (EPI) were taken from skull base to clavicles covering the cervical LNs using parameters, as shown in Tables 1 and 2. To standardize the parameters, both TSE and DWEPI sequences were attained with similar geometry. In DWI sequence, b value is of importance as it minimizes the noise propagation and provides the accuracy of ADC value.[11] Higher *b* values offer a good sensitivity in detecting tumoral disease, LNs, and cystic lesions.[12] In our study, higher *b* values of 1000 s/mm^2 have been used to establish the differentiation of LNs by ADC value.

Evaluation of apparent diffusion coefficient value

LNs are analyzed on ADC map, using workstation Version 3T Magnetom Spectra, Siemens AG, Erlangen, Munich, Germany software system by a 15 years experienced single radiologist who is blinded to clinical and histopathological diagnosis. In this study, we chose only the largest LNs of ≥1 cm in diameter. The ADC values were measured by placing the region of interests (ROIs) around the LNs avoiding contents of necrotized area. For a better qualitative assessment, *b*1000 values should be used which most likely suppress the T2 shrine effects in necrosis or fluidcontaining regions avoiding the overestimation.[11] Ideally, DWI-EP images are preferred in calculating ADC values of LNs, where the ROI is contoured as it has the highest contrast between the lesion and the normal tissue. The equation used for ADC value calculation is:

Table 1: Parameter sequences of T1- and T2-weighted turbo spin echo

Parameters	T1 weighted TSE	T2 weighted TSE
TR/TE	560ms/22ms	3500ms/89ms
FOV (AP×RL)	263×350mm	263×350mm
VOXEL SIZE (AP×RL)	0.9mm	0.9mm
NO. OF SLICES	30	30
Slice thickness	3mm	3mm
RECONS.VOXEL SIZE	0.94mm	0.94mm
TSE FACTOR	4	20
FLIP ANGLE	150 degrees	150 degrees
NSA	2	3
BAND WIDTH	248Hz	248Hz
Total scan duration	4 mins 50 sec	7 mins 57 sec

Table 2: Parameter sequences of echo-planar diffusion-weighted imaging

Parameters	EPI - DWI
TR/TE	3500 ms/72 ms
FOV (AP×RL)	235×350mm
VOXEL SIZE (AP×RL)	1.5×1.5mm
NO. OF SLICES	35
SLICE THICKNESS	4mm
FLIP ANGLE	150
EPI FACTOR	80
NSA	3
FAT SUPPRESSION	STIR
BANDWIDTH	679Hz
NO. OF b FACTORS	1
b FACTOR ORDER	Ascending
MAXIMUM b FACTOR	1000s/mm^2
RECON VOXEL SIZE	1.47×1.47
SCAN DURATION	2 mins 47 sec

$$ADC = \frac{In(S_0 / S_1)}{b}$$

Where S_0 and S_1 are the signal intensity and b is the b value.

Histological–radiological analysis

Wide margins of surgical excision and neck dissection were performed by an oral surgeon who was blinded to the size and ADC value of LNs detected by MRI. Then, all the LNs were subsequently examined microscopically by an oral pathologist who was also blinded to radiological findings. The size, area, and histopathological picture of nodes were recorded, as shown in Figure 1. The histopathological reports were used as the gold standard to compare with the ADC values of DW-MRI of reactive and metastatic LN.

Statistical analysis

Data analysis was performed using the independent *t*-test for reactive and metastatic LNs. Evaluation of ADC cutoff value in differentiating metastatic and reactive LNs was done using sensitivity, specificity, predictive value, and diagnostic accuracy with receiver operating characteristic (ROC) curve analysis.

RESULTS

Out of 100 dissected neck levels of lymph nodes, 34 were level I LNs, 34 Level II LNs, 23 Level III LNs, 6 Level IV LNs and 3 Buccal nodes were identified. Relevant patient characteristics, primary tumor location, and details of LNs dissection are summarized in Table 3.

Apparent diffusion coefficient finding

In assessment of DW-MR-EPI, 100 LNs were identified for ADC quantification, in which 76 were reactive and 24 were metastatic cervical nodes. The ADC_{b1000} value for reactive cervical nodes was 1.2933×10^{-3} mm²/s ± 0.32 and for metastatic LNs was 0.90×10^{-3} mm²/s ± 0.30. Tables 4 and 5 show the averaged ADC value of reactive and malignant cervical nodes. ADC values were found to be statistically significant between the groups, respectively ($P < 0.001$). The independent *t*-test was performed between ADC value and histopathological report in Table 6. An optimal ADC threshold value of 0.868×10^{-3} mm²/s was established as a cutoff value which was derived with the ROC curve analysis shown in Chart 1 yielding 84% sensitivity, 96% specificity, and 93% diagnostic accuracy with a confidence interval of 95% ranging from 0.757 to 0.979.

Apparent diffusion coefficient and pathological analysis

On pathological examination, 100 LNs of 1-cm diameter were identified, of which 93 LNs were correlated and 7 LNs were not correlated with histopathological and MRI reports. Most of the cervical nodes were situated at Level I ($n = 34$) and Level II ($n = 34$) in Table 7. Chart 2 shows the average ADC value and histopathology report of LNs.

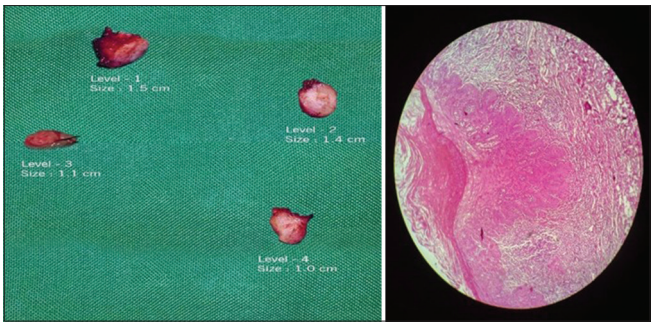

Figure 1: Specimens of neck dissection of lymph nodes and histopathological picture

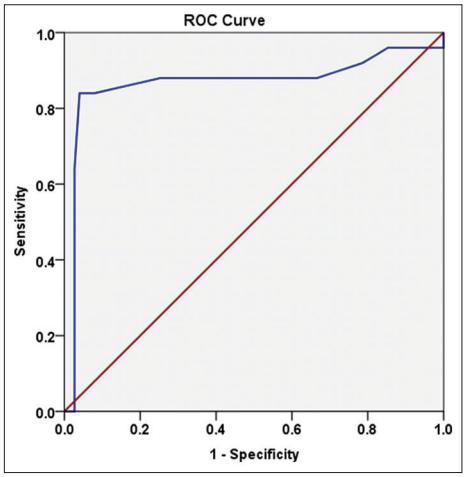

Chart 1: Receiver operating characteristic curve analysis of apparent diffusion coefficient cutoff value

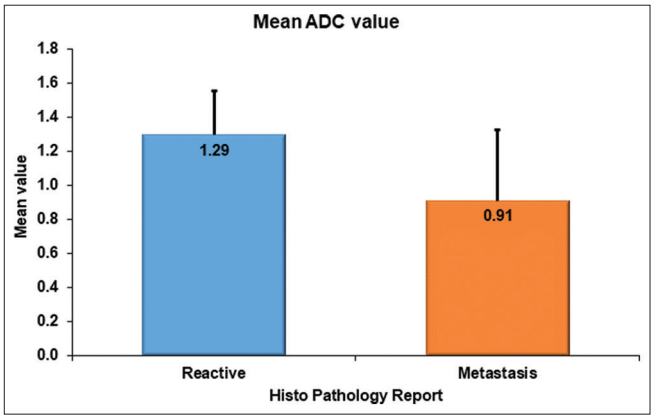

Chart 2: Average apparent diffusion coefficient value and histopathology report of lymph nodes

DISCUSSION

HNC accounts for 5% of all the malignancies worldwide. Many patients with headandneck cancer commonly involve regional LNs requiring treatment consisting of surgery and adjuvant therapy.[13] Lymphatic metastasis is an important mechanism of tumor spread in case of malignancy. The presence of a LN is a prognostic sign where invasiveness and LN metastasis have a greater impact. Imaging prior to treatment of HNC has

Table 3: Details of the patient, primary tumor location, and type of neck dissection

Patient s.no	Age (years)	Gender	Primary tumour location	Type of neck dissection
1	62	M	Tongue	Radical
2	63	F	Alveolo-buccal complex	Radical
3	72	M	Floor of the mouth	Radical
4	54	M	Tongue	Radical
5	55	M	Alveolo-buccal complex	Radical
6	53	M	Buccal mucosa	Radical
7	35	M	Tongue	Radical
8	70	F	Alveolo-buccal complex	Radical
9	34	M	Buccal mucosa	Radical
10	48	M	Alveolo-buccal complex	Radical
11	42	M	Buccal mucosa	Radical
12	60	M	Tongue	Radical
13	37	M	Tongue	Radical
14	39	M	Buccal mucosa	Radical
15	44	M	Tongue	Radical
16	31	M	Buccal mucosa	Radical
17	43	M	Tongue	Radical
18	40	M	Buccal mucosa	Radical
19	55	M	Buccal mucosa	Radical
20	31	M	Buccal mucosa	Radical
21	65	F	Buccal mucosa	Selective
22	60	F	Tongue	Radical
23	41	M	Buccal mucosa	Radical
24	70	M	Buccal mucosa	Selective
25	45	F	Alveolo-buccal complex	Radical
26	43	F	Buccal mucosa	Radical
27	64	M	Buccal mucosa	Radical
28	60	M	Buccal mucosa	Radical
29	41	M	Buccal mucosa	Radical
30	36	M	Bucco-vestibular complex	Radical
31	43	M	Buccal mucosa	Radical
32	70	F	Alveolo-buccal complex	Radical
33	81	M	Tongue	Radical
34	48	M	Alveolo-buccal complex	Radical

Table 4: Apparent diffusion coefficient value of reactive lymph nodes

ADC value of reactive LN	Level of LN location	ADC value of reactive LN	Level of LN location
1.2	Level III	1.3	Level IV
1.3	Level IV	1.1	Level II
1.3	Level II	1.1	Level I
1.2	Level I	1.5	Level II
1.2	Level I	1.3	Level III
1.1	Level II	1.2	Level I
1.3	Level III	1.3	Level II
1	Level IV	1.3	Level II
1.1	Level I	1.1	Level III
1.2	Level II	1.2	Level II
1.1	Level II	1.4	Level II
1.2	Level I	1.2	Level I
1.6	Level II	1.6	Level II
1.4	Level III	1.4	Level III
1.1	Level IV	1.7	Level I
1	Level II	2.1	Level II
1.5	Level III	1.2	Level II
1.3	Level I	1.6	Level III
1.3	Level II	1.9	Level I
1.1	Level III	1.7	Level II
1.4	Level II	1.3	Level IV
1.2	Level III	1.1	Buccal nodes
1.2	Level I	1.3	Level I
1.1	Level II	1.4	Level II
1.5	Level III	1.3	Level II
1.2	Level I	1.1	Level III
1.1	Level II	1.7	Level II
1.2	Level II	1.4	Level III
1.2	Buccal nodes	1.2	Level II
1.8	Level I	1.4	Level II
1.4	Level III	1	Level III
1.3	Level I		
1.5	Level II		
1.3	Level III		
1.4	Level I		
1.7	Level II		
1.6	Level III		
1.1	Level I		
1.5	Level II		
1.2	Level III		
1.3	Level III		
1.2	Level IV		

gained more interest in which it has the ability in staging the primary tumor, posttreatment response, and differentiating LN characteristics.[14]

Perrone *et al*. stated that there is a difficulty in understanding the differences between the reactive and metastatic LNs in HNC. Since water molecules (protons) by DWI can alter the internal changes of the tissue, distinguishing the reactive and metastatic lymph nodes can be difficult in HNC. Therefore, characteristics changes of LNs such as extracapsular tumor spread, size and shape, abnormality of internal architecture, nuclear: cytoplasmic ratio and chromatism can be useful in differentiating reactive and metastatic LNs.[15]

Differences in ADC values show the diffusion changes in evaluating the different pathologies. Many studies reported that there is an opposite relation between ADC values and LN cellularity leading to restricted diffusion of nodes or viable LN. According to previous literature, low ADC values are related to high cellularity, enlarged nuclear: cytoplasmic ratio, and restriction diffusion which are attributed to the characteristics of metastatic LNs.[16] High ADC value having low cellularity with strong contrast and no restricted diffusion leads to the characteristics of reactive LNs.[17]

In line with these studies, our study deals with the standardization of technical settings of the same b value, evaluating the ADC cutoff value and recording the topographic correlation of LN of 1 cm in diameter in relation to MR images showing significant differences in ADC values between reactive and metastatic LNs. The result of our study shows 84% sensitivity, 96% specificity, and 93% diagnostic accuracy with a confidence interval of 95% ranging from 0.757 to 0.979, indicating that 3T DW-MRI can be used in distinction between reactive and metastatic LNs HNC patients [Figure 2].

Interestingly Si *et al*. have demonstrated DW-MRI with ADC values in differentiating LNs, but none of them have standardized the parameter sequence which can influence the ADC calculation.[10] Thoeny *et al*. have stated that different *b* values and DW-EPI sequence can result in various

Table 5: Apparent diffusion coefficient value of metastatic lymph nodes

ADC value of metastatic LN	Level of LN location
0.6	Level I
0.9	Level III
0.8	Level I
0.7	Level I
0.9	Level I
0.8	Level III
0.7	Level III
0.8	Level I
0.6	Level III
0.8	Buccal node
0.8	Level I
0.7	Level I
0.9	Level I
0.9	Level I
0.6	Level II
0.8	Level II
0.6	Level I
0.8	Level I
0.9	Level I
0.7	Level I
0.8	Level I

Table 6: Mean apparent diffusion coefficient value between H/P reactive and metastatic lymph nodes

Variable	H/P report	*n*	Mean	Std. Dev	*t*	*P*
ADC value	Reactive	75	1.2933	0.25802	5.486	<0.001
	Metastasis	25	0.9080	0.41525		

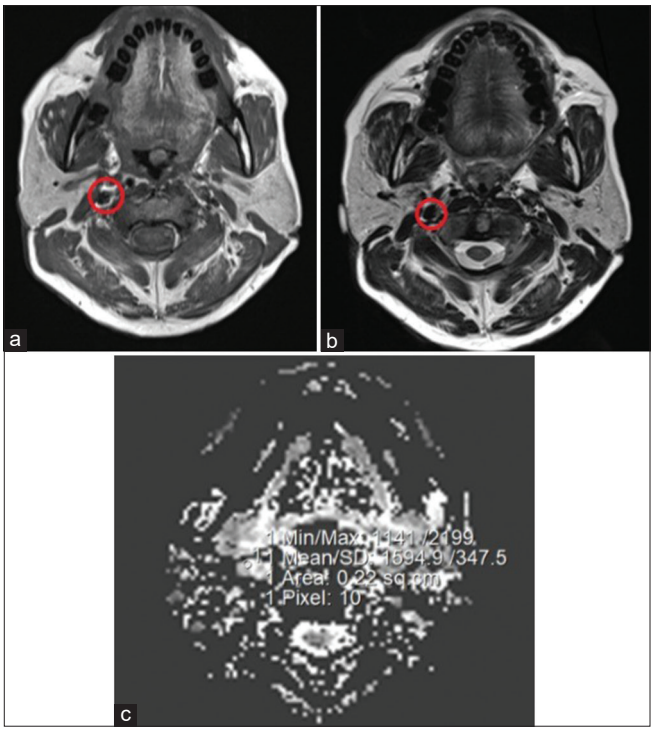

Figure 2: (a and b) Axial T1- and T2-weighted image with hypointensity signal of Level 2 lymph nodes and (c) Diffusion-weighted magnetic resonance imaging of Level 2 with apparent diffusion coefficient value 1.6 characteristics of reactive lymph nodes

ADC values and susceptible artifacts.[17,10] To avoid this, we standardized the sequence using multi-shot EP imaging and single higher *b* value ($b = 1000$) sequence which can decrease the artifact and represent more cellularity in tissues quantifying the ADC values.[18] Recording the pathological LNs after surgery without correlating with MR images for size and location of LN owes to false-positive results.[19] Although we performed surgeries after topographic correlation of 1-cm diameter LN with prior MR images [Figure 3], we resulted in seven false-positive findings. Figure 3d demonstrates the ADC value of 1.4 for reactive LN in Level 2, whereas histopathological results revealed them to be metastatic LNs. Although our study population of 100 LNs was small, we were able to obtain a consistent ADC cutoff value as the DW-MRI parameter sequences were standardized which vary when compared to previous literature.

The ADC cutoff value in our study was 0.868×10^{-3} mm^2/s in ROC analysis of reactive and metastatic LNs of size 1 cm in diameter, thereby differentiating the LNs using 3T DW-MRI. de Bondt *et al*. stated that well-established ADC cutoff value depends on the technique used and size of the LN.[20] Hence, in this research, we standardized the parameter sequence with the same *b* value for all LNs of sized 1 cm in diameter, recorded the topographic correlation of each LN, and determined the best ADC cutoff value for both reactive and metastatic LNs using 3T DW-MR-EPI in HNC patients. Yet, there are some limitations in our study. First, subcentimeter LNs are not considered in our research and also in previous literature due to the possibility of nodal metastases in the head-and-neck region.[21] Second, dental restoration such as amalgams and fixed prosthesis can produce artifacts which, in turn, can be reduced by making the availability of faster imaging sequences. Evaluating ADC values for LNs is an operator-dependent entity, where selection of ROIs can result in under- or overestimation of nodal pathology. Third, determining LNs in MR workstation is time-consuming. Fourth, during the period of research, all the patients were squamous cell carcinoma type, but regions involved were oral cavity rather than head-and-neck regions. Fifth, many studies have been performed to validate DW MRI in discriminating reactive and metastatic LNs in HNC. The purpose of our study was to determine the ability of DW-MRI in distinguishing reactive and metastatic nodes to aid in diagnosis. In future research, using the baseline of our study treatment options such as selective neck dissection can be performed for N0 patients.[22]

CONCLUSION

3T DW-MRI can be used in calculating the ADC value and to distinguish reactive and metastatic nodes in HNC patients. Furthermore, ADC cutoff value of 0.868×10^{-3} mm^2/s indicates that 3T DW-MRI is an accurate predictor and diagnostic marker in the metastatic nodes in HNC patients. More multicenter studies with larger sample size and

Table 7: Diffusion-weighted imaging apparent diffusion coefficient value and histopathological examination of lymph nodes

DWI - ADC value of lymph nodes	HPE of lymph nodes
Level I - 1.2	Reactive
Level I - 1.2	Reactive
Level I - 1.1	Reactive
Level I - 1.2	Reactive
Level I - 1.3	Reactive
Level I - 1.2	Reactive
Level I - 1.2	Reactive
Level I - 1.8	Reactive
Level I - 1.3	Reactive
Level I - 1.4	Reactive
Level I - 1.1	Reactive
Level I - 1.3	Reactive
Level I - 1.9	Reactive
Level I - 1.7	Reactive
Level I - 1.2	Reactive
Level I - 1.2	Reactive
Level I - 1.1	Reactive
Level I - 1.6/Reactive	Metastatic
Level I - 0.6	Metastatic
Level I - 0.8	Metastatic
Level I - 0.7	Metastatic
Level I - 0.9	Metastatic
Level I - 0.8	Metastatic
Level I - 0.8	Metastatic
Level I - 0.8	Metastatic
Level I - 0.7	Metastatic
Level I - 0.9	Metastatic
Level I - 0.9	Metastatic
Level I - 0.6	Metastatic
Level I - 0.8	Metastatic
Level I - 0.9	Metastatic
Level I - 0.7	Metastatic
Level I - 0.8	Metastatic
Level I - 0.6/Metastatic	Reactive
Level II - 1.3	Reactive
Level II - 1.1	Reactive
Level II - 1.2	Reactive
Level II - 1.1	Reactive
Level II - 1.6	Reactive
Level II - 1	Reactive
Level II - 1.3	Reactive
Level II - 1.4	Reactive
Level II - 1.1	Reactive
Level II - 1.1	Reactive
Level II - 1.2	Reactive
Level II - 1.5	Reactive
Level II - 1.7	Reactive
Level II - 1.5	Reactive
Level II - 1.4	Reactive
Level II - 1.2	Reactive
Level II - 1.7	Reactive
Level II - 1.3	Reactive
Level II - 1.4	Reactive
Level II - 1.7	Reactive
Level II - 1.2	Reactive
Level II - 2.1	Reactive
Level II - 1.6	Reactive
Level II - 1.4	Reactive
Level II - 1.2	Reactive
Level II - 1.3	Reactive
Level II - 1.3	Reactive
Level II - 1.5	Reactive
Level II - 1.1	Reactive
Level II - 1.3/Reactive	Metastatic

Contd...

Table 7: Contd...

DWI - ADC value of lymph nodes	HPE of lymph nodes
Level II - 0.6	Metastatic
Level II - 0.8	Metastatic
Level II - 0.9/Metastatic	Reactive
Level III - 1.2	Reactive
Level III - 1.3	Reactive
Level III - 1.4	Reactive
Level III - 1.5	Reactive
Level III - 1.1	Reactive
Level III - 1.2	Reactive
Level III - 1.5	Reactive
Level III - 1.4	Reactive
Level III - 1.3	Reactive
Level III - 1.6	Reactive
Level III - 1.2	Reactive
Level III - 1.3	Reactive
Level III - 1	Reactive
Level III - 1.4	Reactive
Level III - 1.1	Reactive
Level III - 1.6	Reactive
Level III - 1.4	Reactive
Level III - 1.1	Reactive
Level III - 1.3	Reactive
Level III - 0.9	Metastatic
Level III - 0.8	Metastatic
Level III - 0.7	Metastatic
Level III - 0.6	Metastatic
Level III - 0.5/Metastatic	Reactive
Level IV - 1.3	Reactive
Level IV - 1	Reactive
Level IV - 1.1	Reactive
Level IV - 1.2	Reactive
Level IV - 1.3	Reactive
Level IV - 1.3	Reactive
Buccal Nodes - 1.2	Reactive
Buccal Nodes - 1.1	Reactive
Buccal nodes - 1.6/Reactive	Metastatic
Buccal Nodes - 0.8	Metastatic

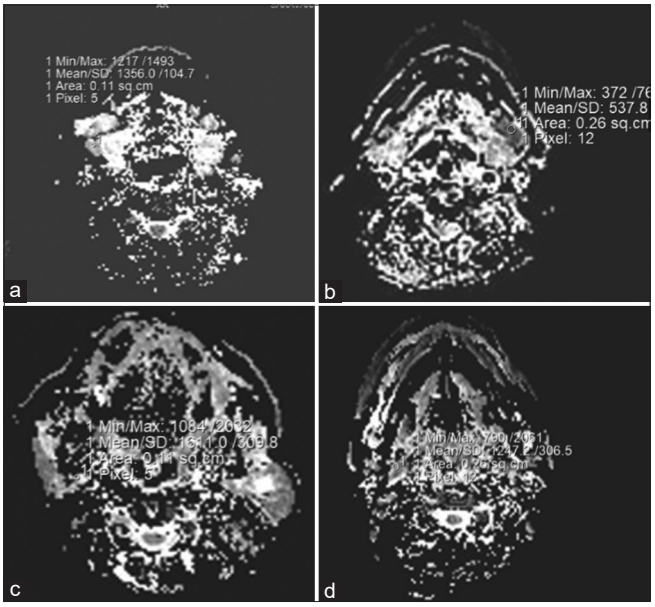

Figure 3: Diffusion-weighted magnetic resonance imaging of (a) Level 1B with apparent diffusion coefficient value of 1.8, (b) Level 1B with apparent diffusion coefficient value of 0.5, (c) Level 2 with apparent diffusion coefficient value of 2.1, and (d) Level 2 with apparent diffusion coefficient value of 1.4

different MR systems have to be performed to validate our study in the future.

Acknowledgment

The authors would like to thank the staff members of Oral Medicine and Radiology Department of SRM Dental College and Hospital, Ramapuram, Chennai.

Financial support and sponsorship

Nil.

Conflicts of interest

There are no conflicts of interest.

REFERENCES

1. Heneidy H, Yosef W. Role of diffusion weighted imaging in differentiating benign from malignant head and neck tumors. Int J Med Imaging 2016;4:16.
2. Snyderman NL, Johnson JT, Schramm VL Jr., Myers EN, Bedetti CD, Thearle P. Extracapsular spread of carcinoma in cervical lymph nodes. Impact upon survival in patients with carcinoma of the supraglottic larynx. Cancer 1985;56:15979.
3. King AD, Tse GM, Ahuja AT, Yuen EH, Vlantis AC, To EW, *et al*. Necrosis in metastatic neck nodes: Diagnostic accuracy of CT, MR imaging, and US. Radiology 2004;230:7206.
4. van den Brekel MW, Stel HV, Castelijns JA, Nauta JJ, van der Waal I, Valk J, *et al*. Cervical lymph node metastasis: Assessment of radiologic criteria. Radiology 1990;177:37984.
5. Dunithan AJ, Cox LA, Long BW. Detection of acute stroke with diffusionweighted MRI. Radiol Technol 1998;69:55965.
6. Wang J, Takashima S, Takayama F, Kawakami S, Saito A, Matsushita T, *et al*. Head and neck lesions: Characterization with diffusionweighted echoplanar MR imaging. Radiology 2001;220:62130.
7. Ross BD, Moffat BA, Lawrence TS, Mukherji SK, Gebarski SS, Quint DJ. Evaluation of cancer therapy using diffusion magnetic resonance imaging. Mol Cancer Ther 2003;2:5817.
8. Sumi M, Sakihama N, Sumi T, Morikawa M, Uetani M, Kabasawa H. Discrimination of metastatic cervical lymph nodes with diffusionweighted MR imaging in patients with head and neck cancer. AJNR Am J Neuroradiol 2003;24:162734.
9. Verhappen MH, Pouwels PJ, Ljumanovic R, van der Putten L, Knol DL, De Bree R. Diffusionweighted MR imaging in head and neck cancer: Comparison between halffourier acquired singleshot turbo spinecho and EPI techniques. AJNR Am J Neuroradiol 2012;33:123946.
10. Si J, Huang S, Shi H, Liu Z, Hu Q, Wang G. Usefulness of 3T diffusionweighted MRI for discrimination of reactive and metastatic cervical lymph nodes in patients with oral squamous cell carcinoma: A pilot study. Dentomaxillofac Radiol 2014;43:1-9.
11. Vandecaveye V, De Keyzer F, Dirix P, Lambrecht M, Nuyts S, Hermans R. Applications of diffusionweighted magnetic resonance imaging in head and neck squamous cell carcinoma. Neuroradiology 2010;52:77384.
12. Takahara T, Imai Y, Yamashita T, Yasuda S, Nasu S, Van Cauteren M. Diffusion weighted whole body imaging with background body signal suppression (DWIBS): Technical improvement using free breathing, STIR and high resolution 3D display. Radiat Med 2004;22:27582.
13. McGurk M, Chan C, Jones J, O'regan E, Sherriff M. Delay in diagnosis and its effect on outcome in head and neck cancer. Br J Oral Maxillofac Surg 2005;43:2814.
14. Lee MC, Tsai HY, Chuang KS, Liu CK, Chen MK. Prediction of nodal metastasis in head and neck cancer using a 3T MRI ADC map. AJNR Am J Neuroradiol 2013;34:8649.
15. Perrone A, Guerrisi P, Izzo L, D'Angeli I, Sassi S, Mele LL. Diffusionweighted MRI in cervical lymph nodes: Differentiation between benign and malignant lesions. Eur J Radiol 2011;77:2816.
16. Kotsenas AL, Roth TC, Manness WK, Faerber EN. Abnormal diffusionweighted MRI in medulloblastoma: Does it reflect small cell histology? Pediatr Radiol 1999;29:5246.
17. Thoeny HC, De Keyzer F, King AD. Diffusionweighted MR imaging in the head and neck. Radiology 2012;263:1932.
18. Suh CH, Choi YJ, Baek JH, Lee JH. The diagnostic value of diffusionweighted imaging in differentiating metastatic lymph nodes of head and neck squamous cell carcinoma: A systematic review and metaanalysis. AJNR Am J Neuroradiol 2018;39:188995.
19. Baltzer PA, Renz DM, Herrmann KH, Dietzel M, Krumbein I, Gajda M. Diffusionweighted imaging (DWI) in MR mammography (MRM): Clinical comparison of echo planar imaging (EPI) and halffourier singleshot turbo spin echo (HASTE) diffusion techniques. Eur Radiol 2009;19:161220.
20. de Bondt RB, Hoeberigs MC, Nelemans PJ, Deserno WM, PeutzKootstra C, Kremer B. Diagnostic accuracy and additional value of diffusionweighted imaging for discrimination of malignant cervical lymph nodes in head and neck squamous cell carcinoma. Neuroradiology 2009;51:18392.
21. Pekçevik Y, Çukurova İ, Arslan İB. Apparent diffusion coefficient for discriminating metastatic lymph nodes in patients with squamous cell carcinoma of the head and neck. Diagn Interv Radiol 2015;21:397402.
22. Taha T, Sakr HM, Taha MS, Salem DA. Role of diffusion weighted MRI in the initial diagnosis and followup of pharyngeal squamous cell carcinoma. Egypt J Radiol Nucl Med 2015;46:91927.