

Disseminated cutaneous glomuvenous malformation

Sir,

Glomuvenous malformations (GVMs) also known as glomangiomas are proliferations of cells of the glomus body, a specialized form of arteriovenous anastomosis involved in thermal and baroregulation. They usually present as asymptomatic pink-to-blue nodules or plaques in childhood and adolescence.^[1] Multiple lesions are uncommon, representing less than 10% of all reported cases,^[2] and involvement of mucous membranes is even rarer.

A 30-year-old male presented with multiple bluish to dusky red plaques and nodules since 12 years of age.

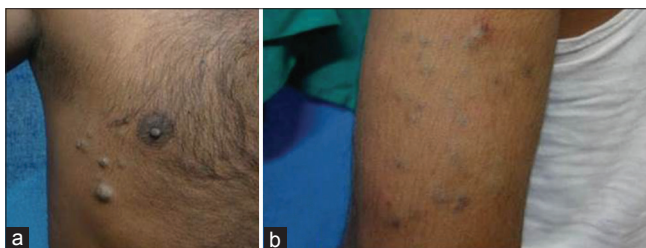

Figure 1: (a) Multiple bluish nodules over the trunk (b) Bluish to erythematous papulonodules forming a plaque over the left arm

The first lesion appeared over the right medial canthus and bridge of the nose as an erythematous papule. There was a gradual increase in the number of lesions thereafter, involving the nose, upper lip, arms, buttocks and trunk. Some of the lesions were painful with scant bleeding on trauma. There was no history of any systemic complaints or bleeding from visceral sites. No one else in the family was affected. Cutaneous examination revealed 25-30 non-compressible to partially compressible tender plaques and nodules ranging in size from 1 cm to 5 cm over the trunk, face, arms, and buttocks. [Figures 1 and 2] There was no associated bruit or thrill. Over the left arm the papules were grouped to form a plaque. [Figure 1b] Similar lesions were also present over the inner aspect of the upper lip, gingiva, and right vestibule. Keeping the provisional possibilities of glomus tumor, blue rubber bleb nevus, and venous malformation, a skin biopsy was taken from a nodule. Histological examination showed acanthosis and papillomatosis of the epidermis along with multiple ectatic dilated vascular channels in the dermis. These vascular channels were surrounded by multiple layers of cuboidal glomus cells with ovoid nuclei and eosinophilic cytoplasm. [Figures 3 and 4] These features were consistent with the diagnosis of glomuvenous malformation. Hemogram, liver function tests, renal function tests, urine routine microscopy, stool for occult blood, coagulation profile, and X-ray paranasal sinuses were within normal limits. At present, the patient has undergone 2 sessions of sclerotherapy with polidocanol for symptomatic lesions with minimal improvement. The patient has been counseled about the nature and usual course of the disease, and an informed decision will be made regarding planning of future sessions.

Glomus tumors are thought to represent neoplastic proliferations of glomus cells which are modified

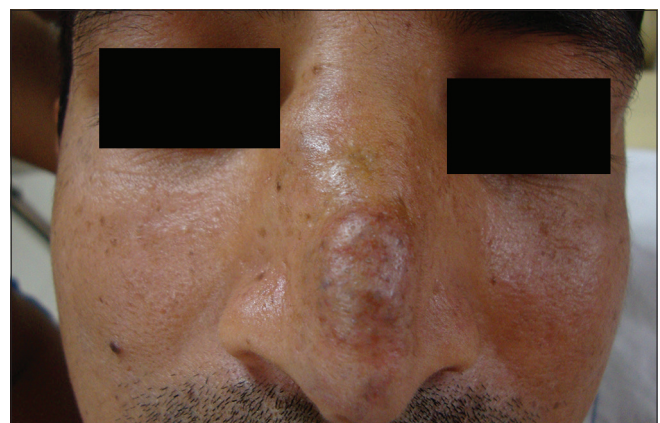

Figure 2: Skin colored to bluish swelling on the nose

smooth muscle cells located in the walls of the Sucquet-Hoyer canal, a specialized arteriovenous anastomosis found most often in the fingers, and play an important role in thermoregulation.^[1] Our case is unusual because the presence of bluish nodules and plaques with cobblestoning in a disseminated pattern is a rare pattern of presentation in glomangiomas. Glomus tumors can be subdivided into localized, disseminated, and congenital plaque-type forms. Localized pattern of lesions is the most common, and they present as blue-to-purple, partially compressible papules or nodules that are grouped and limited to a specific area, most commonly to an extremity. The disseminated type is less common, presenting as

multiple lesions distributed over the body with no specific grouping, and the congenital plaque-like form is the rarest, consisting of either grouped papules that coalesce to form indurated plaques or clusters of discrete nodules [Table 1].

Our case had lesions involving the mucosal aspect of upper lip and right nasal vestibular area. Mucosal involvement is very rare with only occasional case reports with oral cavity, nasal cavity, and paranasal sinus involvement.^[3,4] In a large case series of 135 patients, only 1% of inherited cases had mucosal involvement whereas 7.3% of sporadic cases showed involvement of the mucosal sites.^[1]

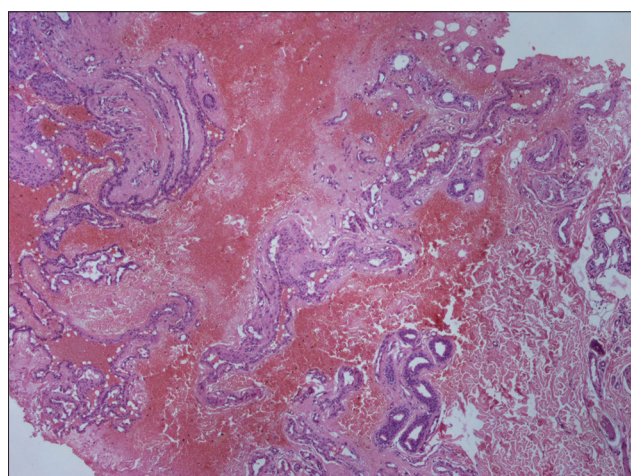


Figure 3: Congested ectatic vascular channels lined by multiple layers of glomus cells

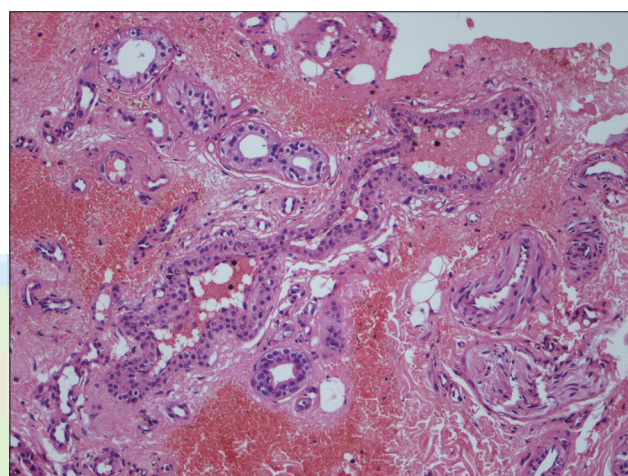


Figure 4: Multiple layers of cuboidal glomus cells with ovoid nucleus and eosinophilic cytoplasm

Table 1: Summary of previously reported disseminated cutaneous glomangiomas

Authors	Number of cases	Inheritance pattern	Mucosal involvement	Age at diagnosis	Course	Treatment
Boon <i>et al.</i> , 2004	135	Inherited (105)	1%	50% at birth 50% at puberty	Not available	Not available
		Sporadic (30)	7.3%	100% at birth		
Solovan <i>et al.</i> , 2012	1	Inherited	None	Adolescence	Onset at puberty with gradual progression of lesions thereafter	Excision of painful symptomatic nodules with observation and follow up
Borovaya <i>et al.</i> , 1992	1	Not known	None	Adolescence	Onset at birth with increase in size of the lesions with age	Excision of painful symptomatic nodules with observation and follow up
Hussein <i>et al.</i> , 2012	2	Sporadic	None	Adolescence	Onset at puberty with gradual increase in size and number	Not available
Mallory <i>et al.</i> , 2006	10	Inherited (4)	None	At birth/ infancy (7)	Macular lesions at birth with increase in size, extent and elevation with age	Excision (3) Sclerotherapy (1) Pulsed dye laser+Sclerotherapy (1) Observation (5)
		Sporadic (6)		Adolescence (4)		
Hazey <i>et al.</i> , 2009	1	Sporadic	None	At birth	Bluish red macules with few ectatic vessels at birth, gradual enlargement at 9 month follow up	None
Diamantino <i>et al.</i> , 2011	1	Sporadic	None	Childhood	Purplish vascular lesions at birth with gradual progression with age	None

Letters to the Editor

Glomuvenous malformations can be sporadic or inherited. They are thought to result from mutations in the glomulin gene. This generates a truncated glomulin protein that interferes with vascular smooth muscle differentiation and late maturation of vascular smooth muscle cells resulting in the formation of glomus cells. These cells stain positively for smooth muscle cell α actin, vimentin, and calponin but are negative for desmin, von Willebrand factor, and S-100.^[5] Our patient was a sporadic case who presented with generalized lesions at puberty. Mutation analysis for glomulin gene could not be performed because the facility is not available at our centre.

Histologically, glomuvenous malformations contain multiple irregular, dilated, endothelium-lined vascular channels that are surrounded by small aggregates of cuboidal glomus cells having a round ovoid nucleus and scant eosinophilic cytoplasm. These cells are also present in the adjacent stroma.^[6] In patients with multiple glomangiomas, excision should be limited to symptomatic lesions only, and asymptomatic lesions should be kept under periodic observation.^[6] Other modalities that have been used are argon and carbon dioxide laser therapy, electron-beam radiation, and sclerotherapy with hypertonic saline or sodium tetracyclate. However, sclerotherapy has been found to be less effective in glomuvenous malformations than in venous malformations. The prognosis for these patients is usually excellent and most patients never experience any related medical problems.

Aditi Jha, V. Ramesh, Avninder Singh¹

Department of Dermatology and Sexually Transmitted Diseases,
Vardhman Mahavir Medical College and Safdarjung Hospital,
¹Department of Pathology, Indian Council of Medical Research,
Safdarjung Hospital, New Delhi, India

Address for correspondence: Dr. V. Ramesh,
Department of Dermatology and Sexually Transmitted
Diseases, 5th Floor, OPD Block, Vardhman Mahavir Medical
College and Safdarjung Hospital, New Delhi - 110 029, India.
E-mail: weramesh@gmail.com

REFERENCES

1. Boon LM, Mulliken JB, Enjolras O, Vikkula M. Glomuvenous malformation (glomangioma) and venous malformation: Distinct clinicopathologic and genetic entities. *Arch Dermatol* 2004;140:971-6.
2. Goodman TF, Abele DC. Multiple glomus tumors. A clinical and electron microscopic study. *Arch Dermatol* 1971;103:11-23.
3. Ficarra G, Merrell PW, Johnston WH, Hansen LS. Intraoral solitary glomus tumor (glomangioma): Case report and literature review. *Oral Surg Oral Med Oral Pathol* 1986;62:306-11.

4. Constantinidis J, Kiefer A, Reitnauer K, Iro H. Glomangioma of the nasal cavity and paranasal sinuses. *Rhinology* 2000;38:136-9.
5. Brouillard P, Boon LM, Mulliken JB, Enjolras O, Ghassibé M, Warman ML, *et al.* Mutations in a novel factor, glomulin, are responsible for glomuvenous malformations ("glomangiomas"). *Am J Hum Genet* 2002;70:866-74.
6. Leger M, Patel U, Mandal R, Walters R, Cook K, Haimovic A, *et al.* Glomangioma. *Dermatol Online J* 2010;16:11.

Access this article online	
Quick Response Code:	Website: www.ijdv.com
	DOI: 10.4103/0378-6323.144200