

Research Article

A study of variations in brachial artery and its branching pattern

Uma Shivanal^{1*}, M. S. Trinesh Gowda²

¹Department of Anatomy, Mysore Medical College and Research Institute, Mysore, Karnataka, India

²Department of Anatomy, Mandya Institute of Medical Sciences, Mandya, Karnataka, India

Received: 03 April 2015

Accepted: 07 May 2015

***Correspondence:**

Dr. Uma Shivanal,

E-mail: umavijay15@gmail.com

Copyright: © the author(s), publisher and licensee Medip Academy. This is an open-access article distributed under the terms of the Creative Commons Attribution Non-Commercial License, which permits unrestricted non-commercial use, distribution, and reproduction in any medium, provided the original work is properly cited.

ABSTRACT

Background: Knowledge of the normal and variant arterial anatomy of the upper extremity is of significant clinical importance for the vascular radiologist and surgeons for accurate diagnostic interpretation as well as in the conduct of interventional and surgical procedures on the upper extremity. The anatomical knowledge of the anomalous branching pattern of the brachial artery is important during percutaneous arterial catheterization, so as to prevent any complications arising from accidental damage to the anomalous vessel and knowledge of the variations are important for plastic surgeons using flaps for reconstructive surgeries.

Methods: The present study was undertaken on 50 upper limbs of both sexes from embalmed adult human cadaver used for undergraduate dissection from the department of Anatomy, Mandya Institute of Medical Sciences, Mandya.

Results: In the present study, normal brachial artery was found in 42 specimens accounting for 84%. Variations were found in 8 specimens (16%); of these five specimens presented with trifurcation of brachial artery into radial, ulnar and radial recurrent arteries (10%); one specimen presented with double profunda brachii artery (2%); one specimen showed high origin of radial artery (2%) and one specimen presented with high division of brachial artery in the proximal third of arm (2%).

Conclusions: Accurate anatomical knowledge about the brachial artery and its branching pattern with their variations are important for physicians, cardiologists, vascular surgeons and interventional radiologists. Study of these variations and its awareness helps in avoiding the iatrogenic injuries of the blood vessels, in the management of accidental/traumatic injuries to arteries in upper limb and during diagnostic procedures (like arteriograms).

Keywords: Brachial artery, Brachial artery variations, Profunda brachii artery, Radial artery, Ulnar artery

INTRODUCTION

The word "Brachial" is derived from the Greek word Brakhion meaning 'Shorter'; brachium also means 'arm'.

The brachial artery is the major artery of the upper limb. It begins as a continuation of the axillary artery at the distal (inferior) border of the tendon of teres major muscle and ends at the level of the neck of the radius by dividing into radial and ulnar arteries.¹ The artery is superficial in its course in the arm, lying immediately deep to the deep fascia of the antero-medial aspect of the arm.² It gives profunda brachii artery, superior and

inferior ulnar collateral arteries, nutrient artery to the humerus and muscular branches in the arm.

The brachial artery has numerous important anastomoses with proximal parts of radial and ulnar arteries, ensuring circulation in case of disturbed blood flow during flexion of elbow joint.¹

The anatomical knowledge of the anomalous branching pattern of the brachial artery is important during percutaneous arterial catheterization, so as to prevent any complications arising from accidental damage to the anomalous vessel and knowledge of the variations will be

important for plastic surgeons using flaps for reconstructive surgeries.

The brachial and antebrachial arteries are the arteries of choice for making an arterio-venous fistula involving the radial artery and the cephalic vein in wrist region for dialysis to treat chronic renal failure. They are the first and best choice of the treatment for dialysis because they last longer and need less maintenance.³

One of the several clinical applications of the brachial artery, besides blood pressure monitoring and arterial puncture for gasometry, is the measure of its Flow Mediated Dilation (FMD). This vessel has been used in obstetrics as a method of evaluating endothelial function. Another invasive procedure using brachial artery is cardiac ventriculography, when femoral access is not possible.³

Considering all these factors, the present study was taken to know the variations in course and branching pattern of brachial artery to help clinicians for diagnostic evaluation and surgical management of vascular injuries and diseases.

METHODS

The present study was conducted on 50 upper limb specimens belonging to the department of Anatomy of Mandya Institute of Medical Sciences, Mandya for the period of 1 year from January 2013 - January 2014. These specimens were taken from embalmed human cadavers used for undergraduate studies irrespective of sex and race, age ranging from 18 to 80 years. Adult upper limbs showing gross deformity, asymmetry or partially amputated were considered unsuitable for this study. The dissection was carried out to look for the brachial artery and its branches. The origin of brachial artery and its branches were identified. The branches of brachial artery were traced, cleaned and observed. In the cubital fossa, bicipital aponeurosis was dissected and terminal branches of brachial artery were exposed and observed. The brachial artery was cleaned, dividing the cross channels that interconnects the accompanying venae comitantes.

RESULTS

Out of 50 specimens studied, 42 (84%) specimens showed normal brachial artery and its branching pattern, while the rest 8 (16%) specimens showed.

- 1 Trifurcation near its termination was seen in 5 specimens (10%) (Figure 1).

In the present study, trifurcation of brachial artery was observed in five specimens. In all the cases the brachial artery was terminating in the cubital fossa into radial, ulnar and radial recurrent arteries and this was accounting for 10% of variations.

- 2 Double profunda brachial artery was seen in 1 specimen (2%) (Figure 2).




Figure 1: Specimen showing trifurcation of brachial artery.



Figure 2: Specimen showing double profunda brachial artery.

In the present study, one specimen showed presence of double profunda brachii artery arising from postero-medial aspect of brachial artery accounting for 2% of the variations observed.

- 3 High origin of radial artery was seen in 1 specimen (2%) (Figure 3).

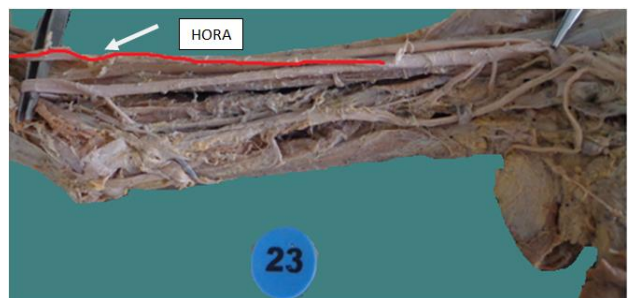

Figure 3: Specimen showing high origin of radial artery.

In the present study, high origin of radial artery was found in one specimen. It was originating from proximal one third of brachial artery and coursing superficially in the arm, crossed superficial to the median nerve and then descending laterally to it. Radial artery did not give origin to any branches in the arm.

- 4 High division of brachial artery was seen in 1 specimen (2%) (Figure 4).



Figure 4: Specimen showing high division of brachial artery.

In the present study, high division of brachial artery was observed in one specimen (2%). After giving rise to profunda brachii artery and superior ulnar collateral artery, the artery was bifurcating in the proximal third of the arm into radial and ulnar arteries. The radial artery was crossing superficial to the median nerve and continued superficial course in the forearm. Inferior ulnar collateral artery was not found to be arising from any of these terminal branches.

Table 1: Frequency of variations of brachial artery and its branching pattern.

Type	Number (50)	Percentage (%)
Normal	42	84
Variations	8	16

Table 2: Analysis of variations.

Variations observed	Number of specimens	Percentage (%)
Double profunda brachii artery arising from brachial artery (DPBA)	1	2
Trifurcation of brachial artery (TRI)	5	10
High origin of radial artery (HORA)	1	2
High division of brachial artery (HDBA)	1	2

DISCUSSION

Variations in the vascular pattern of upper limb have been frequently observed. The presence of the arterial variations may be due to chemical factors, hemodynamic forces, fetal position in the uterus, genetic predisposition and the result of developmental anomaly during the formation of blood vessels.⁴ The first systemic description and classification of these variations was published in 1844 by the Quain's review of literature and analysis of cadaver dissection.⁵

In the present study, trifurcation of brachial artery was observed in five specimens. In all the cases the brachial artery was terminating in the cubital fossa into radial, ulnar and radial recurrent arteries and this was accounting for 10% of variations. This was the most common variation observed in the present study.

Trifurcation of brachial artery

Patnaik VVG et al., in 2002 conducted a study on 50 upper limbs and described a case of trifurcation of brachial artery where it divided into radial, ulnar and radial recurrent arteries instead of radial and ulnar arteries at the level of neck of radius in the cubital fossa in one upper limb accounting for 2%.⁶

Bilodi AK in 2004 reported a case of trifurcation of brachial artery where it was dividing into radial, ulnar and common interosseous arteries.⁷

Malcic-Gurbuz et al., in 2002 observed a case of trifurcation of brachial artery that divided into radial, ulnar and superior ulnar collateral arteries high up in the arm.⁸

These findings were similar to the variations reported by Patnaik VVG et al., in 2002 but with higher frequency. This was the most common variation observed in the present study.

Double profunda brachii artery (DPBA)

Double profunda brachii arteries originating from a single brachial artery, is rarely found in individuals. In case of fractures involving the radial groove of the humerus both the profunda brachii arteries may be involved resulting in excessive haemorrhage.⁹

The origin of profunda brachii artery is quite variable. Charles et al., classified the origin of profunda brachii artery into seven types. In the present study, it is of type Ia: Origin of arteria profunda brachii by 2 separate branches (seen in 0.7% dissections).¹⁰

High division of brachial artery (HDBA)

The bifurcation of brachial artery proximal to the intercondylar line is considered as high division or bifurcation of brachial artery.⁶ According to Compendium of Human Anatomic Variation, major variations are present in about 25% of the subjects studied for the brachial artery. The variations in the form of high proximal division into terminal branches i.e. radial artery (15%), ulnar artery (2%), common interosseous artery, vas aberrans and superficial median antebrachial artery. This high division may occur at any point in the normal course of the vessel. The two vessels into which the brachial artery divides run parallel to each other to the bend of the elbow, in the usual position of the brachial artery. From this point, one branch follows the

normal course of the radial artery through the forearm and the other one takes the normal course of the ulnar artery. This arrangement is considered a simple high division of the brachial artery.¹¹

Rossi Junior et al., in 2011 conducted a study on 56 cadavers in which they encountered a case of high division of the brachial artery, located in the upper $\frac{1}{3}$ rd in both arm, close to the axilla in a male cadaver (1.78%), placed 20 cm above the right cubital fossa and 21.5 cm from the left one. Incidence of a high division of the brachial artery is rare in general population, especially when it is bilateral.³

Quarrat-Ul-Ain et al., in 2002 observed high division of brachial artery in two limbs out of 88 upper limbs of dissected cadavers. The brachial artery divided into its terminal branches after its origin at the lower border of axilla. The radial artery was placed medially whereas ulnar artery was in lateral position. After crossing elbow joint both arteries acquired normal position in the forearm.¹²

The bifurcation of the brachial artery is the commonest site for embolism and a higher bifurcation would result in a larger area of ischemia than expected. High bifurcation of the brachial artery presenting with acute ischemia secondary to an embolic event was reported. This was identified and the ischemia was successfully resolved with embolectomy.¹³ Hence the higher division seeks a greater clinical significance.

High origin of radial artery (HORA)

Brachioradial artery, is defined as a high origin of radial artery, originating frequently from brachial than axillary artery and specifically from upper $\frac{1}{3}$ rd of the brachial artery followed by middle and inferior thirds respectively.¹⁴

HORA is the most frequent arterial variation observed in the upper limb showing an incidence of 20.3% in the dissected specimens and 9.75% in angiographic studies, reported in the literature.¹⁵ The highest prevalence of brachioradial artery or high origin of radial artery was 39 out of 384 upper limbs i.e. 20.3% from the study conducted by Rodriguez et al. in 2001. At the cubital fossa the brachioradial artery may anastomose with brachial artery through a vessel with a sling like loop or rectilinear form.

Embryological basis for the present anomaly can be explained by the persistence of the embryological vessel i.e. proximal or initial segment of radial artery which is giving rise to high origin of radial artery.

Transradial procedure failures can sometimes be due to variation in the radial artery anatomy. This has implications for clinical practice and suggests a need for imaging of the radial artery before such procedure.¹⁶

Hence we urge physicians and surgeons to be aware of this possibility before initiating the procedure.

Development of brachial artery

The axis artery of the upper limb is derived from the lateral branch of the 7th cervical intersegmental artery. The main arterial trunk grows outwards along the ventral axial line and terminates in capillary plexus of the developing limb bud.

Proximal part of the main trunk forms the axillary and brachial arteries, and its distal part persists as the anterior interosseous artery and the deep palmar arch.

The radial and ulnar arteries are the last arteries to appear in the forearm as sprouts of axis artery. The ulnar artery develops as a branch from the original brachial trunk and extends down the ulnar side of the forearm.

Initially, the radial artery arises more proximally than the ulnar artery from the main trunk and crosses in front of the median nerve. Later, the radial artery establishes a new connection with the main trunk at or near the level of origin of the ulnar artery. The upper portion of its original stem usually undergoes regression to a large extent. Thus radial and ulnar arteries arise at the same level.

The profunda brachii, nutrient branch and ulnar collaterals develop as new off shoots of the primary axial vessel.¹⁷

CONCLUSION

Arterial variations are common in the upper extremity. The mechanism of development of arterial variations has been the subject of many studies. According to Rodriguez-Niedenfuhr et al., the upper limb arteries form from an initial capillary plexus that appears from the dorsal aorta and develops at the same rate as the limb. A remodeling process occurs involving the enlargement and differentiation of selected parts. It is thought that variations arise through the persistence, enlargement and differentiation of parts of the initial network which would normally remain as capillaries or even regress.¹⁸

Arterial variations in the arm are of potential clinical implications as it is a frequent site of injury and are also involved in many surgical and invasive procedures. Accurate knowledge of these variation patterns are of considerable clinical importance in the reparative surgeries around the shoulder, arm and fracture management of the humerus.

Documentation of these variations is highly significant for the advanced techniques of microvascular reconstructive surgeries and radiologic diagnostic techniques. Variation in the branching pattern of the brachial artery is of significance in cardiac catheterization for angioplasty, pedicle flaps, or arterial grafting. The

transradial approach for percutaneous coronary procedures has the advantage of reducing access site complications but it is associated with specific technical challenges in comparison with the transfemoral approach.

Based on the studies and results done by Rodríguez-Niedenführ et al., injection studies on animal embryos and experimental data, it showed that when an endothelial tube gets a muscular coating it loses its remodelling ability.¹⁹ Most of vascular variations can be understood in context of vascular embryology. These deviations frequently resemble patterns found in the lower animals because embryology reflects evolution.²⁰

Overall understanding of the variations of brachial artery and its branching pattern is essential for the clinicians and surgeons to avoid iatrogenic injuries so as to reduce morbidity and mortality.

Funding: No funding sources

Conflict of interest: None declared

Ethical approval: The study was approved by the institutional ethics committee

REFERENCES

1. Standing S, Borely NR, Collins P, Crossman AR, Gatzoulis MA, Herly JC, et al. Upper arm. In: Standing S, Borely NR, Collins P, Crossman AR, Gatzoulis MA, Herly JC, et al., eds. Gray's Anatomy: the Anatomical Basis of Clinical Practice. 40th ed. London, UK: Elsevier Ltd; 2008: 827-828, 835-836.
2. Sinnatamby CS. Upper limb. In: Sinnatamby CS., eds. Last S Anatomy. 11th ed. Philadelphia: Churchill Livingstone Elsevier; 2006: 61.
3. Junior R, Esteves, Simoes JS, Fernandes GJM. Bilateral high division of the brachial artery in one human male cadaver: a case report. J Morphol Sci. 2011;28(3):204-7.
4. Krstonosic B, Srdic B, Maric D, Gudovic R, Mijatov S, Babovic S. An anatomical study of double brachial arteries - a case report. IJAV. 2010;3:6-8.
5. Aughsteen AA, Hawamdeh HM, AL-Khayat M. Bilateral variations in the branching pattern of brachial artery. IJAV. 2011;4:167-70.
6. Patnaik VVG, Kalsey G, Rajan KS. Branching pattern of brachial artery - a morphological study. J Anat Soc India. 2002;51:176-86.
7. Bilodi AK, Sanikop MB. Variations in termination of brachial artery - a case report. Kathmandu Univ Med J. 2004;2(1):49-51.
8. Malcic GJ, Gurunluoglu R, Ozdogmus O, Yalin, Aymelek A. Unique case of trifurcation of the brachial artery: its clinical significance. Clinic Anat. 2002 May;15(3):224-7.
9. Das S, Singh S, Paul S. Double profunda brachii and abnormal branching pattern of the brachial artery. TMJ. 2005;55:159-61.
10. Bidarkotimath S, Avadhani R, Arunachalam K. Primary pattern of arteries of upper limb with relevance to their variations. Int J Morphol. 2011;29(4):1422-8.
11. Bergman RA, Thompson SA, Afifi AK, Saadeh FA. Cardiovascular system. In: Bergman RA, Thompson SA, Afifi AK, Saadeh FA, eds. Compendium of Human Anatomic Variation. Text, Atlas and World Literature. 1st ed. Baltimore: Urban and Schwarzenberg; 1988: 73-74.
12. Quarrat-ul-Ain, Kausar Y, Raza TA. High division of brachial artery and analogous start of radial and ulnar arteries. Ann King Edward Med Coll. 2002 Jan-Mar;8(1):30-1.
13. Cherukupuli C, Dwivedi A, Dayal R. High bifurcation of brachial artery with acute arterial insufficiency: a case report. Vasc Endovasc Surg. 2008;41(6):572-4.
14. Rodriguez-Niedenführ M, Vazquez T, Nearn L, Ferreira B, Parkin I, Sanudo JR. Variations of the arterial pattern in the upper limb revisited: a morphological and statistical study, with a review of the literature. J Anat. 2001;199:547-66.
15. Pelin C, Zagypay R, Mas N, Karbay G. An unusual course of the radial artery. Folia Morphol. 2006;65(4):410-3.
16. Madhyastha S, Nayak SR, Krishnamurthy A, D'costa S, Jose AA, Bhat KMR. Case report of high origin of radial, ulnar and profunda brachii arteries, its clinical implication and literature. J Vasc Bras. 2009;8(4):374-8.
17. Datta AK. The circulatory system. In: Datta AK, eds. Essentials of Human Embryology. 6th ed. Kolkata, India: Current Books International; 2010: 183-185.
18. Rodriguez-Niedenfuhr M, Burton GJ, Deu J, Sanudo JR. Development of the arterial pattern in the upper limb of staged human embryos: normal development and anatomic variations. J Anat. 2001;199:407-17.
19. Rodriguez-Niedenführ M, Vazquez T, Parkin IG, Sanudo JR. Arterial patterns of the human upper limb: update of anatomical variations and embryological development. Eur J Anat. 2003;7:21-8.
20. Pushpalatha M, Haq I. Bilateral high division of the brachial artery - a case report. Anatomica Karnataka. 2010;4(1):59-61.

DOI: 10.18203/2320-6012.ijrms20150154

Cite this article as: Shivanal U, Trinesh Gowda MS. A study of variations in brachial artery and its branching pattern. Int J Res Med Sci 2015;3:1392-6.