

Rheumatoid factor versus anti - cyclic citrullinated peptide antibody as screening tool for rheumatoid arthritis in an ophthalmic clinic

Prabhakar Singh, Arvind Kumar¹, Prakash Chandra²

Patients with moderate to severe dry eyes are often screened at the Dry Eye Clinic to rule out connective tissue diseases. Rheumatoid factor (RF) is one of the screening tools to rule out rheumatoid arthritis (RA). Patients who turn out positive for the RF are often subjected to anti-CCP antibody evaluation for confirmation of disease. This article tries to highlight 3 cases of negative and anti-CCP antibody positive cases which presented to the ophthalmic clinic, unaware of their systemic status. Though RF is the cheapest modality to screen for RA, it is not always a reliable marker. One should order anti-CCP antibody for patients where suspicion is high, despite RF being normal.

Key words: Anti-CCP antibody, ophthalmic clinic, Rheumatoid factor

Dry eye disease has always been an area of interest, as far as its etiology, adequate and targeted treatment is concerned. Altered ocular surface milieu can often be because of local factors contributing to dryness, however systemic factors should also be evaluated for. RA is one such systemic etiology causing dry eyes. RA can cause spectrum of ocular manifestations from keratoconjunctivitis sicca to scleritis, sclerokeratitis, peripheral ulcerative keratitis.^[1] Known cases of RA are often looked for

any ocular complications, however reverse referral from an ophthalmic clinic to a rheumatologist is very less often seen. Lack of awareness about the widespread prevalence of disease could be an important cause of non-referral.

There are various clinical signs, symptoms and serological tests available to diagnose the disease. The markers like RF and anti-CCP are said to have good sensitivity and specificity.

Patients with moderate to severe dry eyes are often screened at ophthalmic clinic (dry eye clinic) to rule out connective tissue diseases. At our clinic all patients with moderate to severe dry eyes (as per Dry Eye Disease grading scheme- DEWS 2007), dry eyes not responding to the conservative treatment with lubricants or associated with clinically evident systemic features were evaluated for systemic diseases. A detailed history is taken. All patients in dry eye clinic undergo detailed slit lamp examination to look for any lid or adnexal abnormality responsible for dry eye. Tear break-up time, observation of ocular surface staining patterns and Schirmers are done sequentially. We have also incorporated meibography as a workup tool in dry eye clinic.

RF is one of the screening tools to rule out RA. Patients who turn out positive for the RF are often subjected to anti-CCP antibody evaluation for confirmation of disease. The sensitivity and specificity of anti-CCP reactivity for RA patients diagnosed based on American College of Rheumatology criteria were detected as 73.5% and 100%, respectively.^[2] Does that mean that cases which are negative for RF cannot have positive anti-CCP antibody? This article tries to highlight three cases of RF negative and anti-CCP antibody positive cases which presented to the ophthalmic clinic, unaware of their systemic status.

Case 1

A 60-year-old female presented to the clinic with complaints of photophobia and decreased vision for 1 month. Visual acuity in RE was 20/1200 whereas that in LE was CFCF. The Schirmers value were 8 mm and 5 mm for the right and left eye, respectively. The patient attributed the symptoms to the cataract, and wanted to get operated for it. On examination LE had diffuse superficial punctate keratitis (SPK) [Fig. 1], whereas RE had filamentary keratitis. Both eyes had immature

Access this article online	
Quick Response Code:	Website: www.ijo.in
	DOI: 10.4103/ijo.IJO_526_19

Head of Cornea and Anterior Segment Services, Nirwana Netralaya, Sasaram, ¹Head of Oculoplasty Services, Nirwana Netralaya, ²Nirwana Netralaya, Sasaram, Rohtas, Bihar, India

Correspondence to: Dr. Prabhakar Singh, Head of Cornea and Anterior Segment Services, Nirwana Netralaya, Sasaram, Rohtas - 821 115, Bihar, India. E-mail: prabhakar1aiims@gmail.com

Received: 18-Mar-2019

Revision: 22-Jul-2019

Accepted: 15-Aug-2019

Published: 19-Dec-2019

This is an open access journal, and articles are distributed under the terms of the Creative Commons Attribution-NonCommercial-ShareAlike 4.0 License, which allows others to remix, tweak, and build upon the work non-commercially, as long as appropriate credit is given and the new creations are licensed under the identical terms.

For reprints contact: reprints@medknow.com

Cite this article as: Singh P, Kumar A, Chandra P. Rheumatoid factor versus anti - cyclic citrullinated peptide antibody as screening tool for rheumatoid arthritis in an ophthalmic clinic. Indian J Ophthalmol 2020;68:236-8.

senile cataract but the grade of cataract was not explaining the vision loss. Patient was asked for history of joint pain, to which she complained of occasional pain in wrist and metacarpophalangeal joints of both hands. Routine test was performed. ESR was 30 mm (Westergren method), but RF was negative. Considering the history, anti-CCP antibodies were ordered and it turned out to be strongly positive (625 RU/ml). The patient was counseled and started on topical medications and sent to rheumatologist for treatment. Patient was started on oral methotrexate by rheumatologist, to which she responded well. The patient was operated for cataract 3 months after starting methotrexate.

Case 2

A 58-year-old male presented to the clinic with complaints of foreign body sensation in both eyes for 3 months. The Schirmers value for the right and left eye were 3 mm and 5 mm, respectively. History of small joint pain was noted, for which patient was taking Ayurvedic medication. On examination, BE filamentary keratitis were noted with left eye corneal perforation [Fig. 2]. ESR (20 mm) was marginally raised with normal RF. Anti-CCP antibody (395.81 RU/ml) was significantly raised. Tissue adhesive were used to stabilize the left eye tectonically. Patient was sent to the rheumatologist for further evaluation and treatment. Patient is currently on oral methotrexate for last 4 months and the corneal dryness has improved significantly and also the corneal perforation has healed with a scar.

Case 3

A 50-year-old patient with complaints of decreased vision in both eyes presented to ophthalmic clinic. RE visual acuity was 20/80 and LE was 20/200. Both the eyes had Schirmers value of 6mm. RE had confluent SPKs with posterior subcapsular cataract, whereas LE had partially absorbed cataract. Patient suffered road traffic accident 4 years ago, during which she suffered trauma in LE and her left hand. Patient had swan neck deformity of index, middle and ring finger of left hand [Fig. 3]. Patient attributed these deformities to the trauma she had 4 years ago. Patient was evaluated for dry eyes. ESR was 75 mm by Westergren method and the RF was normal. Considering the finger deformity, patient was also advised for anti-CCP antibodies. It turned out to be strongly positive (540.99 RU/ml). Patient was sent to rheumatologist and was started on methotrexate.

Discussion

In all three cases, the patients were unaware of their systemic status and presented to ophthalmic clinic for their ocular complaints. A thorough history taking and examination, helped us to reach the diagnosis, and hence treatment. Previous studies have shown a direct and significant correlation between anti-CCP antibody and ocular manifestation of RA.^[3] Itty *et al.* in their study found that the combined presence of anti-CCP antibodies and RF had more severe ocular involvement compared to those who were negative for these antibodies.^[1] There are studies suggesting that anti-CCP antibody has been found in sera up to 10 years before the onset of joint symptoms in patients who later develop RA and may appear somewhat earlier than RF.^[4] Though RF is the cheapest modality to screen for RA, it is not always a reliable marker. RF is often not detected early in RA,

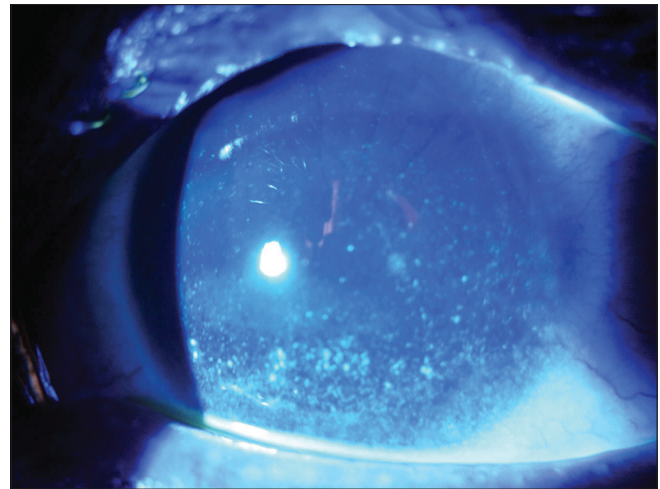


Figure 1: Superficial punctate keratitis secondary to RA induced keratoconjunctivitis sicca

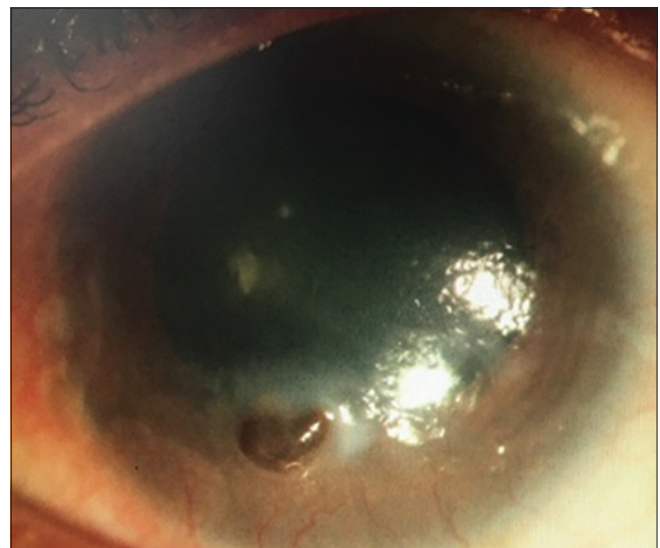


Figure 2: Corneal perforation secondary to keratoconjunctivitis sicca

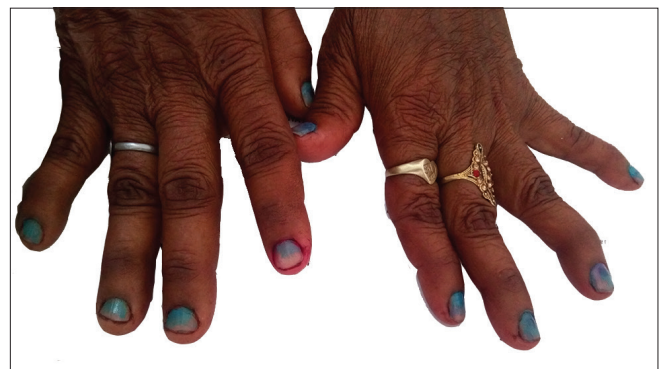

Figure 3: Showing swan neck deformity of fingers

and detection of RF is not specific for RA. Testing for anti-CCP antibody can provide additional information and, in some cases, enable earlier and more specific diagnosis.^[5] One should

order anti-CCP antibody for patients where suspicion is high, despite RF being normal. However still there are 10-15% of patients with seronegative RA with joint deformities. These patients need to be carefully looked for and should also be looked for ophthalmic involvement. In a new patient with symptoms and signs compatible with early RA (ie, a duration of less than 6 months), anti-CCP antibody testing is the better test because it has equal or greater sensitivity (especially early on) and greater specificity, than testing.^[6,7]

Conclusion

RF is the cheapest modality to screen for RA especially in ophthalmic clinic, but is not always a reliable marker. One should order anti-CCP antibody for patients where suspicion is high, despite RF being normal.

Declaration of patient consent

The authors certify that they have obtained all appropriate patient consent forms. In the form the patient(s) has/have given his/her/their consent for his/her/their images and other clinical information to be reported in the journal. The patients understand that their names and initials will not be published and due efforts will be made to conceal their identity, but anonymity cannot be guaranteed.

Financial support and sponsorship

Nil.

Conflicts of interest

There are no conflicts of interest.

References

1. Itty S, Pulido JS, Bakri SJ, Baratz KH, Matteson EL, Hodge DO. Anti-cyclic citrullinated peptide, rheumatoid factor, and ocular symptoms typical of rheumatoid arthritis. *Trans Am Ophthalmol Soc* 2008;106:75-81.
2. El-Banna H, Jiman-Fatani A. Anti-cyclic citrullinated peptide antibodies and paraoxonase-1 polymorphism in rheumatoid arthritis. *BMC Musculoskelet Disord* 2014;15:379.
3. Vignesh AP, Srinivasan R. Ocular manifestations of rheumatoid arthritis and their correlation with anti-cyclic citrullinated peptide antibodies. *Clin Ophthalmol* 2015;9:393-7.
4. Nielen MM, van Schaardenburg D, Reesink HW, van de Stadt RJ, van der Horst-Bruinsma IE, de Koning MH, *et al*. Specific autoantibodies precede the symptoms of rheumatoid arthritis: A study of serial measurements in blood donors. *Arthritis Rheum* 2004;50:380-6.
5. Bose N, Calabrese LH. Should I order an anti-CCP antibody test to diagnose rheumatoid arthritis? *Cleveland Clin J Med* 2012;79:249-52.
6. Egerer K, Feist E, Burmester GR. The serological diagnosis of rheumatoid arthritis: Antibodies to citrullinated antigens. *Dtsch Arztebl Int* 2009;106:159-63.
7. Conrad K, Roggenbuck D, Reinhold D, Dörner T. Profiling of rheumatoid arthritis associated autoantibodies. *Autoimmun Rev* 2010;9:431-5.